



Discover Generics

Cost-Effective CT & MRI Contrast Agents



WATCH VIDEO

AJNR

Computed tomographic diagnosis of posterior ocular staphyloma.

R L Anderson, G A Epstein and E A Dauer

AJNR Am J Neuroradiol 1983, 4 (1) 90-91

<http://www.ajnr.org/content/4/1/90.citation>

This information is current as
of June 20, 2025.

Computed Tomographic Diagnosis of Posterior Ocular Staphyloma

Robert L. Anderson,¹ Gil A. Epstein,² and Edward A. Dauer^{1, 3}

With constantly improving technology and more frequent computed tomography (CT) of the brain and orbits, the radiologist is likely to encounter various ophthalmologic conditions with which he is unfamiliar. One such condition, which has not been described previously, is the posterior ocular staphyloma. The following case presentation will serve to illustrate the clinical and CT manifestations of this condition.

Case Report

A 66-year-old woman was seen by a neurologist with a 2 year history of intermittent headaches referred to the right eye and face. She reported a long history of poor vision in the right eye. Physical and neurologic examination revealed only severe myopia in the right eye.

CT of the brain and orbits was performed with a Picker Synerview 600 CT Scanner, 256 × 256 matrix, 3.3 sec scan time, 10 mm sections angled 20° above the canthomeatal line anteriorly for brain, 6 mm sections parallel to infraorbital-meatal line for orbits. Images were obtained before and after bolus infusion of 100 ml Conray 60 (methylglucamine iothalamate 60%, Mallinckrodt).

The orbital examination (fig. 1) revealed a superolateral isodense bulge projecting from the posterior aspect of the right globe with apparent thinning or absence of the scleral-uveal rim on the contrast-enhanced images. There was no appreciable enhancement of the mass (bulge). The optic nerve and extraocular muscles were symmetric and of normal thickness. There was no evidence of proptosis. The cerebral scan was normal.

The ocular examination revealed severe myopia best corrected to finger counting on the right, with 20/20 vision on the left. A Marcus-Gunn afferent pupillary defect was present on the right. Funduscopy revealed a myopic fundus with a large posterior staphyloma. The axial length of each eye was determined by sonography, the right measuring 30.66 mm, the left 24.1 mm, confirming the funduscopy findings. The sagittal sonogram correlated well with sagittal CT reconstruction (fig. 2).

Discussion

The posterior staphyloma is a well recognized entity associated with the highly myopic eye. High myopia may

involve one or both eyes and is often hereditary. The highly myopic eye is characteristically egg-shaped, as compared with the more spherical "normal" eye. The elongation is in the anteroposterior axis, affecting the posterior pole. The anterior half of the eye is normal [1-3]. There is usually no proptosis. The elongation is thought to be due to a defective sclera, the collagenous structural outercoat of the eye. When severe, there is a focal outward bulge of the sclera at the posterior pole, a posterior staphyloma [2]. Adjacent layers of the eye, the retina, and choroid are likewise thinned and bulge outward with the sclera. This results in a retina prone to detachment [3]. Visual prognosis is poor, especially with congenital and asymmetric staphyloma. In most cases, there is no effective treatment. Scleral implants have met with limited success [1, 3].

Other conditions in which staphyloma occur include glaucoma, scleritis, trauma, and necrotizing infections. These conditions are easily distinguished clinically [3]. The posterior staphyloma and the myopic fundus are diagnosed by clinical ophthalmoscopy and can be quantified by sonography.

The CT appearances correlate well with the structural changes. The scleral-uveal rim was noted to be thinned or absent at the site of the posterior ocular bulge. The bulge was isodense with the rest of the vitreous. The lack of enhancement following contrast is to be expected.

This CT pattern is unlikely to be encountered in ocular neoplasm (primary or metastatic) or pseudotumor. In the Bernardino et al. [4] series of ocular neoplasms, "all showed eccentric thickening of the scleral-uveal rim with extension into the globe." Pseudotumors likewise frequently show scleral-uveal rim thickening and marked enhancement [4-8]. In neither condition is one likely to encounter a smooth focal bulge projecting from the globe of density identical to the vitreous before and after contrast administration.

While Hilal and Trokel [5] noted that CT would demonstrate numerous conditions such as congenital glaucoma (manifest by a large globe), they indicated these conditions are more easily assessed by conventional optical and sonographic methods. Although this is true, an awareness of

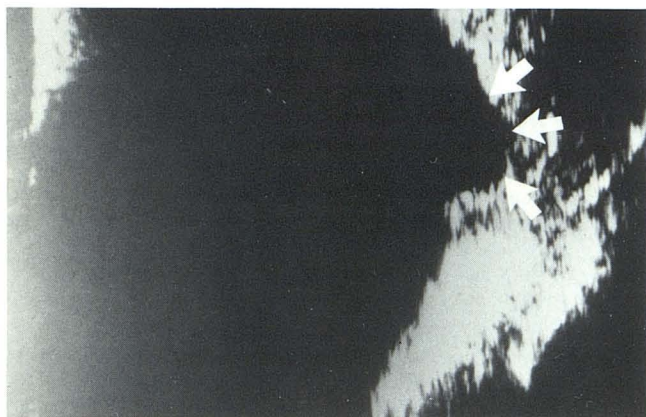
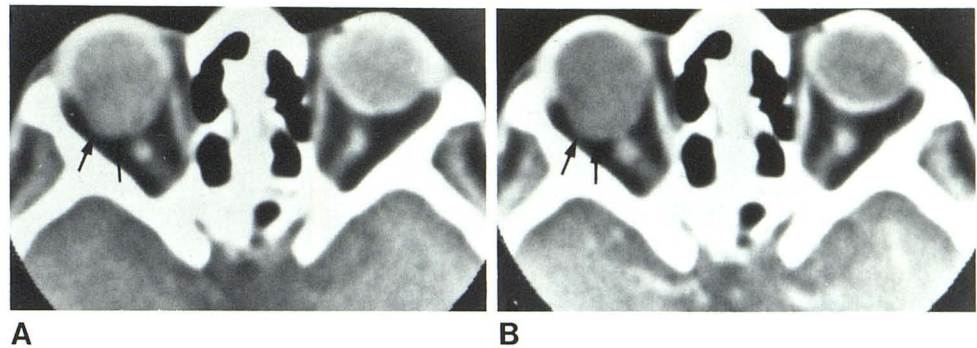
Received January 14, 1982; accepted after revision April 27, 1982.

¹Department of Radiology, Florida Medical Center, 5000 W. Oakland Park, Fort Lauderdale, FL 33313. Address reprint requests to E. A. Dauer.

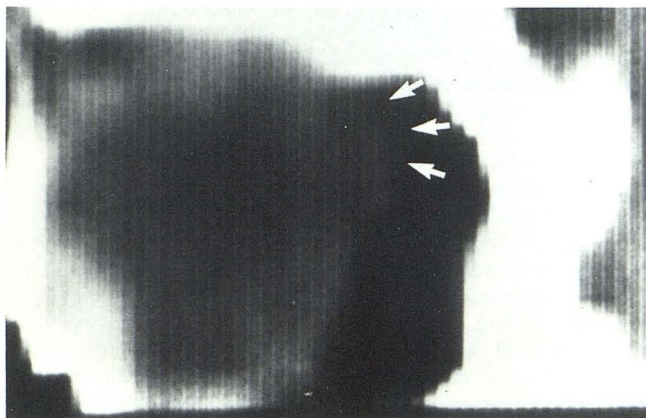
²Department of Ophthalmology, Florida Medical Center, Fort Lauderdale, FL 33313.

³Department of Radiology, University of Miami, Miami, FL 33152.

Fig. 1.—Nonenhanced (A) and enhanced (B) CT scans. Posterior staphyloma is isodense focal bulge of superolateral aspect of posterior pole of right globe. Thinning or absence of overlying scleral-uvual rim (arrows).



A



B

Fig. 2.—A, Sagittal sonogram. Posterior staphyloma (arrows). B, Corresponding CT reconstruction.

these conditions and their CT appearance will help the radiologist avoid undue concern caused by the erroneous diagnosis of an ocular/orbital mass. We suggest that the CT pattern described in our case is characteristic enough to permit the radiologist to at least include posterior staphyloma in his differential diagnosis. The condition is then readily confirmed by funduscopy and/or sonographic examination.

REFERENCES

1. Vaughn D, Asbury T. *General ophthalmology*. Los Altos, CA: Lange, 1974:85-89
2. Duke-Elder S. *Parsons diseases of the eye*. London: Churchill, 1956:442-443
3. Duke-Elder S, Abrams O. *Systems of ophthalmology*. Vol V: *Ophthalmic optics and refraction*. St. Louis: Mosby, 1970:307-309
4. Bernardino ME, Danziger J, Young SE, Wallace S. Computed tomography in ocular neoplastic disease. *AJR* 1978;131:111-113
5. Hilal SK, Trokel SL. Computerized tomography of the orbit using thin sections. *Semin Roentgenol* 1977;12:137-147
6. Hilal SK. Computed tomography of the orbit. *Ophthalmology (Rochester)* 1979;86:864-870
7. Bernardino ME, Zimmerman RD, Cirtin CM, Davis DO. Scleral thickening: a CT sign of orbital pseudotumor. *AJR* 1977;129:703-706
8. Guibert-Tranier F, Piton J, Culabet A, Caille JM. Orbital Syndromes—CT analysis of 100 cases. *Comput Tomogr* 1979;3:241-264