



Providing Choice & Value
Generic CT and MRI Contrast Agents



CONTACT REP

AJNR

**Celebrating 35 Years of the AJNR: May 1983
edition**

AJNR Am J Neuroradiol 2018, 39 (5) 992
doi: <https://doi.org/10.3174/ajnr.P0061>
<http://www.ajnr.org/content/39/5/992>

This information is current as
of July 29, 2025.

Celebrating 35 Years of the AJNR

May 1983 edition

The Application of NMR to the Evaluation of Pituitary and Juxtaseellar Tumors

R. C. Hawkes,¹ G. N. Holland,^{1,2} W. S. Moore,¹ R. Corston,³ D. M. Kean,⁴ and B. S. Worthington⁴

Nuclear magnetic resonance (NMR) imaging was used to evaluate pituitary and juxtaseellar tumors in 37 patients representing a wide range of pathology. The value of the multiplanar facility of NMR is emphasized in providing accurate volumetric information and establishing the topographical relation of tumors to adjacent structures. Current limitations of the method and possible future developments to improve diagnostic precision are discussed.

Investigation of pituitary and parasellar lesions can be particularly exciting because clinical manifestations, including visual failure and endocrinological disturbances, may occur when the lesion is in its early stages. Appropriate management demands precise localization and a distinction among various pathologies so that the appropriate operative route or field for irradiation can be chosen [1]. Early detection of suprasellar extension of pituitary adenomas is particularly important in preventing visual loss in patients undergoing medical treatment, especially when pregnancy occurs in women with prolactinomas, where there is a risk of accelerated tumor expansion [2]. Follow-up studies are valuable in assessing the effects of radiotherapy or drug therapy on tumor size. After plain skull radiography, computed tomography (CT) in the transverse axial plane is usually used to diagnose and evaluate tumors in the pituitary region [3-5]. Despite the high quality of images now available, it is sometimes difficult to determine the precise extent of extraseellar extension of pituitary tumors and to diagnose microadenomas. Invasive procedures are often required to confirm a suspected diagnosis of empty sella syndrome and to establish the relationship of any mass to the optic chiasm [6, 7].

Subjects and Methods

Proton nuclear magnetic resonance (NMR) scans using steady-state free precession (SSFP) techniques were performed with a Picker relative NMR unit on 10 normal volunteers and 37 patients with known pathology in the pituitary region at the Queen's Medical Centre, Nottingham. The cases studied comprised 12 chromophobe pituitary adenomas; five acromegalies; four craniopharyngiomas; three cases each of prolactinoma, juxtaseellar aneurysm, and empty sella syndrome; one case each of recurrent chordoma, hypothalamic glioma, and nasopharyngeal carcinoma; and four colloid cysts of the third ventricle.

¹ Department of Physics, University of Nottingham, Nottingham, England.
² Present address: Picker International, Highland Heights, OH 44143.
³ Department of Neurology, University of Nottingham, Nottingham, England.
⁴ Department of Academic Radiology, Queen's Medical Centre, University of Nottingham.

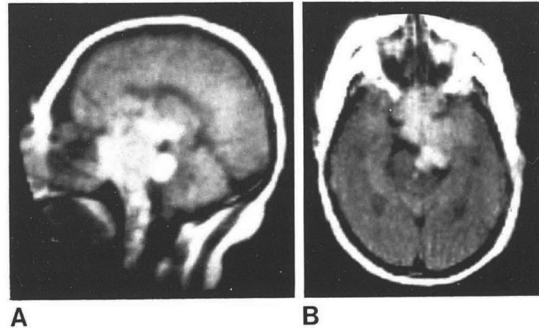
AJNR 4:221-222, May/June 1983 0195-6108/83/0403-0221 \$00.00 © AJNR

Procedure

The normal pituitary gland is isodense with brain and is best seen on sagittal section. It is our practice to obtain a midline sagittal scan and complement this with transverse and coronal scans as appropriate, using a slice thickness of 1 cm and an image time of 2 min. A typical examination of about eight sections takes 25 min. It is usually possible in no more than three attempts to obtain a section in which at least part of the third ventricle is included with the pituitary gland below. The normal gland is seen contrasted against a variable quantity of marrow and air within the basiphenooid. The optic chiasm and optic nerves can be identified within the suprasellar cisterns on sagittal and coronal sections. The anatomy of the suprasellar cisterns shown on transverse section matches that seen with CT.

Results

NMR demonstrated clearly the presence and size of pituitary adenomas. Its multiplanar facility was most valuable in delineating extraseellar extension. All tumors visualized by NMR were denser than brain tissue and all except one were homogeneous in texture. Although the bone of the fossa could not be seen, the degree of expansion of the floor could be observed from the configuration of the inferior margin of the tumor on sagittal and coronal sections. As



Preliminary Clinical Results of Proton (¹H) Imaging of Cranial Neoplasms: In vivo Measurements of T₁ and Mobile Proton Density

Thomas J. Brady,¹ Ferdinando S. Buonanno,² Ian L. Pykett,¹ Paul F. J. New,¹ Kenneth R. Davis,¹ Gerald M. Pohost,³ and J. Philip Kistler²

Proton nuclear magnetic resonance (NMR) images reflecting T₁ relaxation time and approximating proton density were acquired and used to generate T₁ rate (1/T₁) maps. By region-of-interest selection, measurements of T₁ relaxation time were made from discrete volumes of the imaging plane. Such techniques were applied to the study of human cranial neoplasia and associated conditions of differential diagnostic importance (e.g., postoperative changes, radiation necrosis). Inversion-recovery NMR images exhibit a high lesion-detection sensitivity. In all patients, the specificity of NMR imaging is low since all abnormal areas appear as lesions darker than surrounding normal brain, reflecting a decreased proton density, prolonged T₁ values, or both. T₁ relaxation times are prolonged within neoplastic foci; however, absolute T₁ values overlap with those found in other lesions.

During the last decade, in vitro nuclear magnetic resonance (NMR) spectroscopic studies by several investigators [1-3] have demonstrated prolonged proton T₁ relaxation times in various malignant tissues when compared with values obtained from normal tissue. Prolongation of T₁ in tumors has been associated with, among other things, an increase in tissue water content [4]; however, the mechanism producing this phenomenon has not been fully elucidated.

In this preliminary study, NMR images were obtained that provide both subjective assessment of relaxation time of normal tissue and approach attempts to detect delineating central nervous system problems and to detect have specific NMR characteristics.

Materials and Methods

The study population consisted of three patients with relatively acute, and postoperative and neurologic history and pre- and computed tomography (CT) guidelines of the Massachusetts Institute of Human Studies, was

T. J. Brady is a recipient of a G. M. Pohost is an establisher of Department of Radiology, Massachusetts General Hospital, Boston, Massachusetts.
 © AJNR 4:225-226, May/June

study. Histopathologic confirmation of the diagnosis was obtained in six patients.

NMR images were obtained using a prototype head imaging system developed by Technicare Corp. (Solon, OH). A static magnetic field of 0.147 Tesla, corresponding to a proton resonance frequency of 6.26 MHz, is generated by a four coil, relative electromagnet. True three-dimensional volumetric data are acquired using two combined radiofrequency (RF) pulse sequences, as previously reported [5]. Postprocessing of the data allows reconstruction of images in any arbitrary plane, including levels corresponding to those of CT scans. Reconstruction of data from a saturation recovery-type technique with the 90°-90° interslice delay τ set to 1 sec generates images where the signal intensity is mainly dependent on mobile proton density (PD). Reconstruction of data from an inversion-recovery (IR) type of sequence with the 180°-90° interslice delay τ set to 400 msec provides images that are heavily T₁-weighted. The spatial resolution is about 3-4 mm and is isotropic, that is, equal in all directions.

Results and Discussion

Figure 1 contains representative images through a ventricular plane in a normal volunteer. The image that approximates PD (fig. 1A) has uniform signal intensity within the brain parenchyma but has decreased signal intensity in regions of markedly proton-poor T₁.

