



Discover Generics

Cost-Effective CT & MRI Contrast Agents



FRESENIUS
KABI

WATCH VIDEO

AJNR

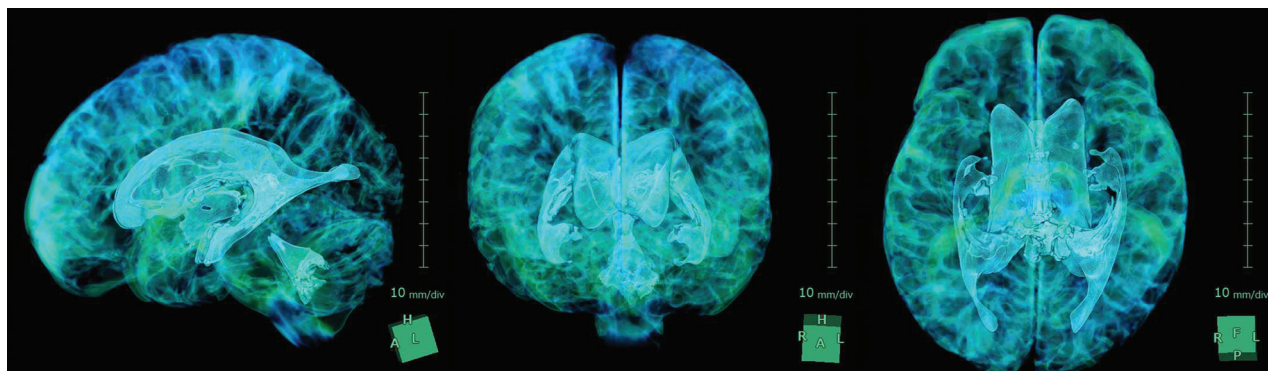
Shigeki Yamada

AJNR Am J Neuroradiol 2016, 37 (5) 773

doi: <https://doi.org/10.3174/ajnr.P0017>

<http://www.ajnr.org/content/37/5/773.citation>

This information is current as
of June 9, 2025.



Title: 3D View of the Intracranial CSF Space in the Normal Brain. **Explanation:** It is a splendid visualization created by using an independent 3D volume analyzer workstation. A 73-year-old man had no medical history including dementia. CSF spaces were automatically extracted from brain parenchyma by using a simple threshold algorithm on the T2-weighted 3D-SPACE sequence with a 64-channel 3-Tesla MRI system. His total CSF volume was automatically calculated as 509 mL which was constructed total ventricular volume (97 mL) and total cisternal volume (412 mL). His brain parenchymal volume was calculated as 1221 mL.

Shigeki Yamada, MD, PhD, Department of Neurosurgery, Stroke Center, NPH Center, Rakuwakai Otowa Hospital, Kyoto, Japan