



Discover Generics

Cost-Effective CT & MRI Contrast Agents



FRESENIUS
KABI

WATCH VIDEO

AJNR

Do Early MRI Signals Predict Lesion Size in a Neonatal Stroke Rat Model?

S. Fau, C. Po, C. Goyenvallé, P. Meric and C. Charriaut-Marlangue

AJNR Am J Neuroradiol 2013, 34 (7) E73-E76

doi: <https://doi.org/10.3174/ajnr.A3069>

<http://www.ajnr.org/content/34/7/E73>

This information is current as of June 23, 2025.

Do Early MRI Signals Predict Lesion Size in a Neonatal Stroke Rat Model?

S. Fau, C. Po, C. Goyenvallée, P. Meric, and C. Charriaut-Marlangue



ABSTRACT

SUMMARY: In this study, we compared lesion size by using V_{ADC} and V_{T2} at 0, 2, 5, 24, and 48 hours and histologic lesions at 48 hours in a P7 rat stroke model. The best correlation between V_{HISTO} and V_{ADC} was at H0, and between V_{HISTO} and V_{T2} at H2-H5. Early MR imaging signals allowed excluding “no-lesion” and “no-reflow” animals to help standardize this neonatal stroke model and predict lesion size.

ABBREVIATIONS: H0, H2, H5, H24, and H48 = 15 minutes and 2, 5, 24, and 48 hours after reperfusion, respectively; P7 = 7-day-old; RARE = rapid acquisition relaxation excitement; V_{ADC} = volume of lesion on ADC maps; V_{HISTO} = volume of lesion on histologic sections; V_{T2} = volume of lesion on T2 maps

Neuroimaging, particularly MR imaging, could be a tool for a rapid comprehensive assessment in acute stroke with the potential to guide treatment decisions for a better clinical outcome. One of the key issues in stroke assessment is to choose the best end points that appropriately indicate outcome. In experimental animal research, final lesion size has been used consistently as an outcome. Infarct sizes assessed by T2WI have been shown to correlate well by some and to underestimate histologic damage by others.¹ In the developing brain, authors have reported that MR imaging in P7 rat pups submitted to stroke² or hypoxia-ischemia^{3,4} seems correlated to final histologic lesions measured 24 hours or 3–10 days after the injury, without early MR imaging time-point evaluation.

The aim of the present study was to develop a preclinical design including routine MR imaging coupling ADC maps, T2 maps, and MRA. We suggested that this strategy could improve the statistical

power of trials using our model by diminishing the variability of the outcome assessment. Early MR imaging could 1) confirm initial ischemia, 2) confirm arterial reflow, and 3) accurately predict the final histologic outcome at 48 hours.

TECHNIQUE

Perinatal Ischemia

Care and use of experimental animals followed French and European Community guidelines. Ischemia was created in 24 Wistar P7 rats (Janvier, Le Genest Saint Isle, France) of both sexes.⁵ Briefly, anesthetized (chloral hydrate, 350 mg/kg, intraperitoneally) rats were exposed to left MCA electrocoagulation followed by 50-minute transient left common carotid artery occlusion. During ischemia and recovery the pups were placed in a humidified incubator at 37°C.

MR Imaging Acquisition

Pups were monitored at H0, H2, H5, H24, and H48 after reperfusion. For H0, H2, and H5 imaging session, pups were asleep due to the initial chloral hydrate injection. For H24 and H48 imaging sessions, pups were anesthetized by isoflurane 0.8% mixed in 30% O₂, 70% N₂. During imaging, animals were thermoregulated by a water blanket heated at 37°C. Images were acquired by using a 7T horizontal magnet equipped with a Bruker AVANCE console and with an actively shielded gradient 360mT device (Bruker BioSpin, Rheinstetten, Germany). DWI was performed from an EPI sequence (TR = 3 seconds, TE = 25 ms, b-values = 50, 500, 1000 s/mm², FOV = 40 × 40 mm, matrix = 256 × 256, repetitions = 3, 25 sections, thickness = 0.5 mm, duration = 9.5 minutes). T2WI was performed with a RARE sequence (TR = 5404 ms, TE values = 25.6, 76.8, 128, 179.2 ms, RARE factor = 4, FOV = 40 × 40 mm, matrix = 128 × 128, 25 sections, thickness = 0.5 mm,

Received December 6, 2011; accepted after revision January 6, 2012.

From the CNRS 7102 (S.F., C.G., C.C.-M.), Equipe HICD, Université Pierre et Marie Curie Paris–Paris, France; Laboratoire de RMN Biologique (C.P., P.M.), ICSN, CNRS UPR 2301, Gif-sur-Yvette, France; and IR4M (C.P.), CNRS UMR 8081, Université de Paris Sud, Orsay, France.

This study was supported by the Institut pour la Recherche sur la Moelle Epinière, Fondation NRJ and Société Française sur la Recherche du Handicap de l'Enfant. S. Fau was the recipient of a “poste d'accueil” from AP-HP and CNRS.

C.C.M., S.F., and P.M. designed and organized this study; S.F., C.P., and C.G. performed the experiments and analyzed data. C.C.M., S.F., and C.P. wrote the manuscript.

Paper previously presented as a poster at: Brain 09, 24th International Symposium on Cerebral Blood Flow, Metabolism, and Function, Chicago, Illinois, June 29–July 3, 2009.

Please address correspondence to C. Charriaut-Marlangue, PhD, Institut National de la Santé et de la Recherche Médicale U676, Hôpital Robert Debré, 48 Bd Sérurier, 75019 Paris, France; e-mail: christiane.marlangue@gmail.com

Indicates open access to non-subscribers at www.ajnr.org

<http://dx.doi.org/10.3174/ajnr.A3069>

duration = 3 minutes). ADC and T2 maps were computed by exponential fitting of the local signal-intensity versus b and TE, respectively, by using a homemade ImageJ plugin (<http://rsbweb.nih.gov/ij/>). MRA was performed with a 3D time-of-flight method based on a fast low-angle shot 3D sequence (TR = 15 ms, TE = 2.5 ms, FOV = 40 × 40 × 40 mm, matrix = 256 × 256 × 128, flip angle = 20°, duration = 3 minutes). Each animal underwent the H0 imaging and was then eventually excluded either as “no-lesion” if the DWI lesion was visible on <3 sections or as “no-reflow” if MRA showed an ipsilateral ICA signal of <40% of the contralateral ICA signal. All animals were sacrificed immediately after the H48 imaging session.

Outcome Assessments

The volume of the lesion was assessed by using histology at H48, ADC maps, and T2 maps from H0 to H48. V_{HISTO} was delineated by a classic visual method on cresyl violet–stained coronal sections (50- μm thick, 500- μm intervals). V_{ADC} and V_{T2} were defined by applying a threshold (mean – 2 SDs) of the whole contralateral hemisphere ADC and T2, respectively. Volume measurements were expressed as a percentage of the ipsilateral hemisphere.

Statistical Analysis

All results are given as mean \pm SD. The correlation and regression were performed with a standard statistical software package (SSYSTAT 3.1, Systat Software, San Jose, California) by using a Spearman rank-order correlation and a linear regression, respectively.

RESULTS

Four animals of 24 (17%) were excluded as no-lesion. All exhibited MCA interruption on H0 angiography, without a significant DWI lesion. Two animals of 24 (8%) were excluded as “no-reflow” as determined on MRA. Eighteen animals were then analyzed (Fig 1), and V_{ADC} , V_{T2} , and V_{HISTO} were calculated (Fig 2). An area in the ipsilateral frontoparietal cortex with low V_{ADC} was maximal at H0 in almost all the animals (Fig 1). V_{ADC} at H0 was different from 6.6%–32.1% of the ipsilateral hemisphere. A significant correlation between V_{ADC} at H0 and lesion volume (V_{HISTO}) at 48 hours was obtained (slope: 1.09, $r = 0.92$, $P < .001$; Fig 2). In some animals, V_{ADC} slightly decreased between H2 and H5, whereas it remained similar in the others. At 24 and more markedly at 48 hours, all V_{ADC} values were highly reduced (0.2%–8.3%; Fig 1). Even if hints in the deeper cortical and subcortical layers (Fig 1) were visible on T2 maps as soon as H0 (in few animals), the T2 lesion was clearly identifiable in all animals at H2 (4.4%–26.7%). A significant correlation between V_{T2} and V_{HISTO} was obtained at H2 (slope: 0.97, $r = 0.91$, $P < .001$) and H5 (slope: 1.04, $r = 0.91$, $P < .001$; Fig 2). This correlation remained at H24 but with a higher slope (1.15, $r = 0.89$). Then V_{T2} slightly decreased at H48 ($r = 0.888$). The range of V_{HISTO} was from 3.5% to 24% with a mean of $13.5 \pm 5.7\%$.

DISCUSSION

This study showed that routine MR imaging could be a toolbox able to standardize neonatal stroke models, first by excluding no-

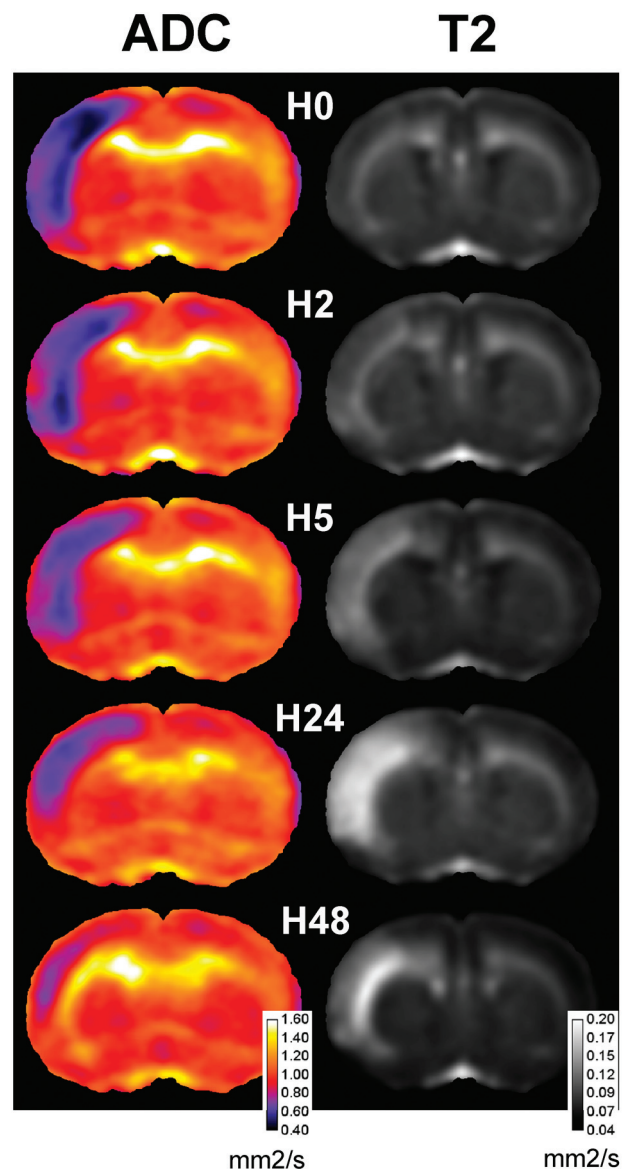


FIG 1. Time course of ADC and T2 maps at Bregma 1.20 mm. Sum of coregistrated sections are computed at H0, H2, H5, H24, and H48. Note that low ADC was observed in the lesioned frontoparietal cortex compared with the contralateral side. Hints of T2 were observed as early as H0 in the deeper cortical layers. At H48, marked T2 signals are still detected in the deeper cortex.

lesion and no-reflow animals in the first MR angiography, and second by predicting histologic outcome early in a neonatal stroke model.

The first set of MR images at H0 was used to exclude no-lesion animals. These animals probably developed efficient cortical arterial anastomoses during ischemia as we previously demonstrated by using sonography.⁶ MR imaging also allowed excluding no-reflow animals because the absence of recanalization was shown to block the development of further edema.⁷

All animals exhibited a quite reproducible time course of ADC or T2 volume. As previously reported, V_{ADC} reached a maximum just after reperfusion.⁷ The best-correlated V_{ADC} time point with V_{HISTO} was H0. This impressive correlation lets one think that as soon as 15 minutes after reperfusion, “the

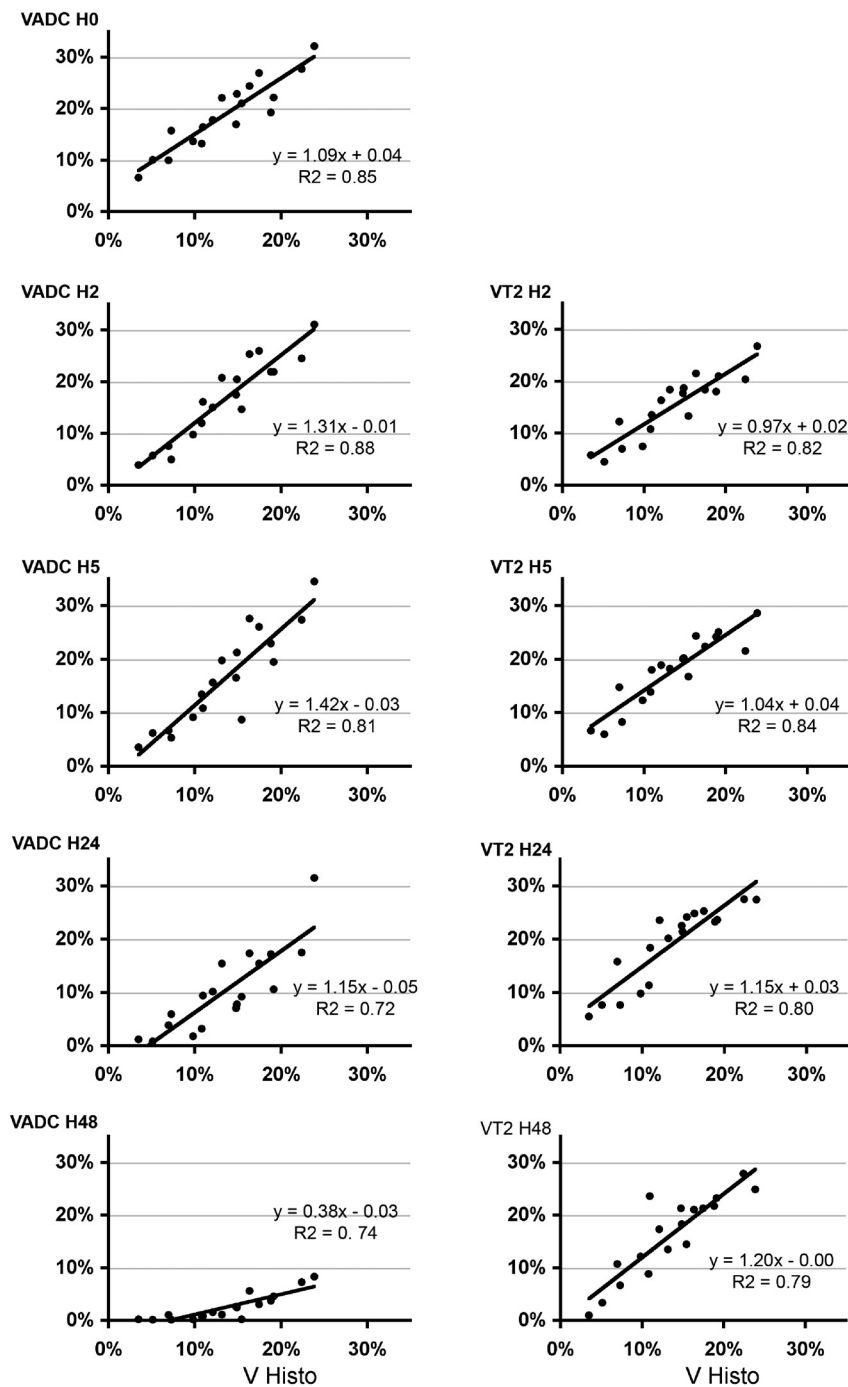


FIG 2. Correlation between MR imaging and histology measurements. V_{HISTO} and V_{ADC} (left) or V_{T2} (right) are given at different time points after reperfusion. Note that correlation was very strong at H0 on the ADC map and at H2 and H5 on the T2 maps.

die was cast,” and almost the whole interindividual variability of animals was already determined. In contrast, at H2 and H5, the slope of regression was superior to 1, suggesting that V_{ADC} overestimated histology volume. Conversely, at 24 and 48 hours, correlation between ADC and histology became less strong and the slope coefficient decreased, leading to an underestimation of the final lesion.

As previously reported, T2 lesions appeared as soon as 2 hours after ischemia.⁷ Most interesting, we observed that the correlation

of V_{T2} with V_{HISTO} was strong as early as H2 and H5, with a slope of regression close to 1, suggesting good overlap between T2 signals and histologic lesions. Thereafter, V_{T2} overestimated lesions at both 24 and 48 hours.

CONCLUSIONS

This whole strategy was not reported in the literature because only parts of studies reported exclusion of no-lesion animals with intraischemic MR imaging.⁸ In addition, early MR imaging signals

appear to be good surrogates for final stroke lesions in the developing brain.

Disclosures: Christiane Charriaut-Marlangue—RELATED: Support for Travel to Meetings for the Study or Other Purposes: Société Française sur la Recherche du Handicap de l'Enfant.* Sébastien Fau—RELATED: Grant: CNRS, Comments: French National Scientific Research Center. *Money paid to the institution.

REFERENCES

1. Farr TD, Wegener S. Use of magnetic resonance imaging to predict outcome after stroke: a review of experimental and clinical evidence. *J Cereb Blood Flow Metab* 2010;30:703–17
2. Derugin N, Wendland M, Muramatsu K, et al. Evolution of brain injury after transient middle cerebral artery occlusion in neonatal rats. *Stroke* 2000;31:1752–61
3. Wang Y, Cheung PT, Shen GX, et al. Hypoxic-ischemic brain injury in the neonatal rat model: relationship between lesion size at early MR imaging and irreversible infarction. *AJNR Am J Neuroradiol* 2006;27:51–54
4. Lodygensky GA, Inder TE, Neil JJ. Application of magnetic resonance imaging in animal models of perinatal hypoxic-ischemic cerebral injury. *Int J Dev Neurosci* 2008;26:13–25
5. Renolleau S, Fau S, Goyenvalle C, et al. Specific caspase inhibitor Q-VD-OPh prevents neonatal stroke in P7 rat: a role for gender. *J Neurochem* 2007;100:1062–71
6. Bonnin P, Leger PL, Deroide N, et al. Impact of intracranial blood-flow redistribution on stroke size during ischemia-reperfusion in 7-day-old rats. *J Neurosci Methods* 2011;198:103–09
7. Fau S, Po C, Gillet B, et al. Effect of the reperfusion after cerebral ischemia in neonatal rats using MRI monitoring. *Exp Neurol* 2007;208:297–304
8. Derugin N, Dingman A, Wendland MF, et al. Magnetic resonance imaging as a surrogate measure for histological sub-chronic endpoint in a neonatal rat stroke model. *Brain Res* 2005;1066:49–56