



Discover Generics

Cost-Effective CT & MRI Contrast Agents



WATCH VIDEO

AJNR

Dural Infantile Hemangioma Masquerading as a Skull Vault Lesion

C. Philpott, A. Wray, D. MacGregor and L. Coleman

AJNR Am J Neuroradiol 2012, 33 (6) E85-E87

doi: <https://doi.org/10.3174/ajnr.A2752>

<http://www.ajnr.org/content/33/6/E85>

This information is current as
of June 7, 2025.

CASE REPORT

C. Philpott
A. Wray
D. MacGregor
L. Coleman

Dural Infantile Hemangioma Masquerading as a Skull Vault Lesion

SUMMARY: We describe a case of intracranial dural IH initially diagnosed as a primary skull vault lesion hemangioma due to associated focal hyperostosis. Histopathologic examination of the dural component confirmed IH. The case is discussed in the context of IH within the neural axis.

ABBREVIATIONS: Glut-1 = glucose transporter-1 by immunohistochemistry; IH = infantile hemangioma

IHs are the most common benign neoplasms of infancy. Although intracranial lesions are relatively rare, they occur predominantly in the basal cisterns. IH presenting in a dural location has never previously been described, to our knowledge.

Case Report

A 12-month-old girl, a monozygotic twin, presented with an enlarged but stable head circumference greater than the 95th percentile with no neurologic signs. Sonography revealed mild ventriculomegaly and enlargement of the extra-axial spaces, compatible with benign enlargement of these spaces. MR imaging was performed, revealing an unexpected finding of focal expansion of the cancellous diploe of the right parietal bone with diffuse thickening and enhancement of the underlying dura (Figs 1 and 2). The dural abnormality was adjacent to the bony lesion but extended well beyond the lesion, including the dura of the tentorium. Apart from mild distortion of the adjacent posterior parietal lobe, there was no abnormality of the underlying brain.

A CT scan confirmed the focal expansion of the diploic bone and endosteal thickening (Fig 3). A benign bone lesion with an abnormal dural reaction, specifically a hemangioma, was favored, but the lack of diploic enhancement was thought atypical for such a lesion. The appearance of the dura raised suspicions of a more sinister process necessitating histopathologic analysis; hence, excisional biopsy, along with resection of abnormal bone, was performed. On histopathologic examination, the bone segment demonstrated symmetric expansion of cancellous bone covered by an unremarkable cortex with normocellular intervening marrow consistent with reactive bone. The dural biopsy demonstrated numerous irregular small blood vessels permeating the mature fibrous tissue (Fig 4A), the endothelium of which stained strongly for Glut-1 by immunohistochemistry (Fig 4B).

MR imaging at 6-month follow-up revealed reduction in dural thickening consistent with spontaneous involution and appropriate bony healing. Clinically, without further treatment, the patient is achieving milestones with plateauing of her head growth. Dedicated review revealed no cutaneous lesions.

Discussion

IHs (previously termed “capillary hemangiomas”) are the most common vascular tumors of infancy. They are benign neoplasms of endothelial cells that rapidly proliferate initially, usually in the first 5 months of life, followed by a plateau phase and slow involution.¹ On histologic examination, these lesions comprise lobules of tightly packed endothelial cells forming capillary-like structures, separated by septa of fibrous connective tissue.^{1,2} Identification of the Glut-1 protein on immunohistochemical staining is used to distinguish these lesions from other vascular lesions.¹ More commonly, they involve the skin and soft tissues. Involvement of the neural axis is rare.

There have been 28 cases of intracranial IH published in the literature.³⁻¹⁶ Classically, these cases involve the extra-axial basal cisterns, subarachnoid and ventricular spaces, and cavernous sinus.^{7-10,12-14} Two articles reported dural attachment,^{10,16} and only 4 cases were intra-axial.^{3,4} Most intracranial IHs (71%)^{4,7,9,12,14} were associated with extracranial soft-tissue extension or cutaneous hemangiomas.

While spinal dural capillary hemangiomas have been described, this is the first case of cranial dural IH. Cranial IH typically presents in childhood (86%),^{3-9,12,14-16} and in a few cases, in adolescence,^{3,10,11,13} while spinal IH usually presents in an older population, (range, 40–62 years).¹⁷

The imaging characteristics of IH within the neural axis are consistent with those found elsewhere, with iso- to low-T1 signal intensity, high T2 signal intensity, and avid contrast enhancement typical on MR imaging.^{14,17} Intralesional flow voids are a common feature,^{10,14} and foci of high T1 signal intensity are also described.^{4,10,17} This may represent thrombosis in some of the small vascular spaces or hemorrhage.

Our initial interpretation of the imaging findings was that this was primarily a bony lesion, an intradiploic IH, with hyperostosis and secondary dural reaction. However, the features were atypical and of concern. There was hyperostosis but no abnormal diploic space enhancement or large abnormal diploic space vessels. The dural reaction was too extensive and florid to be a secondary dural reaction to an intradiploic IH or an essentially benign-appearing bone lesion. Meningioma was considered a possibility, given the florid hyperostosis and dural thickening; however, the appearance was also atypical for this condition. The extensive dural thickening on imaging, therefore, raised concern of a primary dural lesion of sinister etiology.

Hydrocephalus has been described in 10% of intracranial IHs. It is uncertain whether this represents an association with or a consequence of the hemangioma. It could be postulated

Received April 23, 2011; accepted after revision May 17.

From the Departments of Radiology (C.P., L.C.), Neurosurgery (A.W.), and Department of Anatomical Pathology (D.M.), Royal Children's Hospital Melbourne, Australia.

Please address correspondence to Cristina Philpott, MD, Department of Radiology, Royal Children's Hospital, Flemington Rd, Parkville, Victoria, Australia 3052; e-mail: cristina.philpott@rch.org.au

<http://dx.doi.org/10.3174/ajnr.A2752>

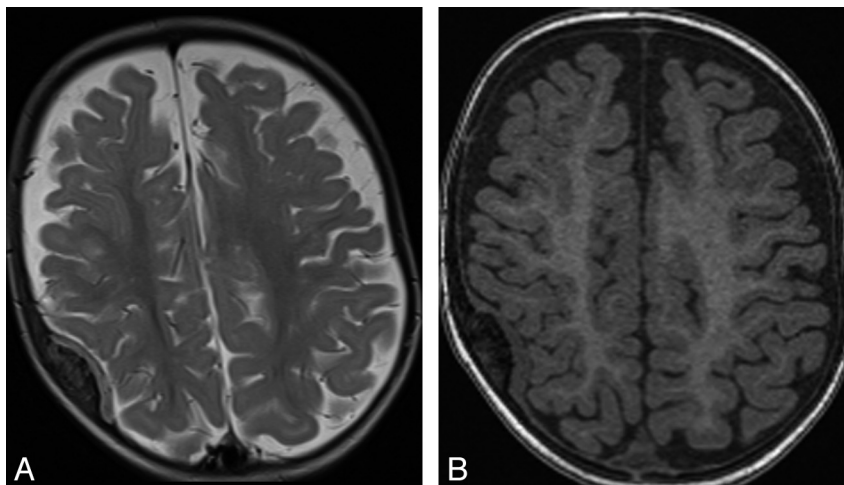


Fig 1. Axial T2 (A) and T1-weighted (B) sequences demonstrating iso- to mildly high T2 signal intensity, the iso-T1 signal intensity dural thickening, and adjacent focal diploic bone expansion with hyperostosis.

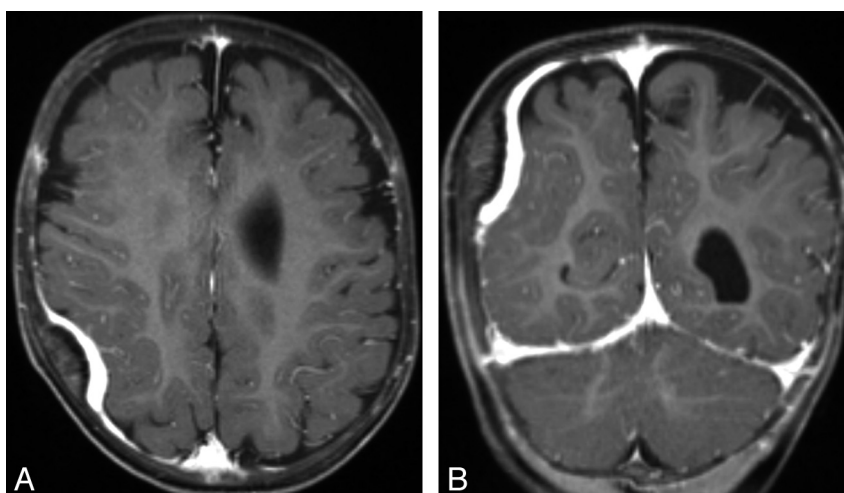


Fig 2. Axial (A) and coronal (B) T1 post-gadolinium-enhanced sequences demonstrating the avidly enhancing abnormal dural thickening underlying the hyperostosis.

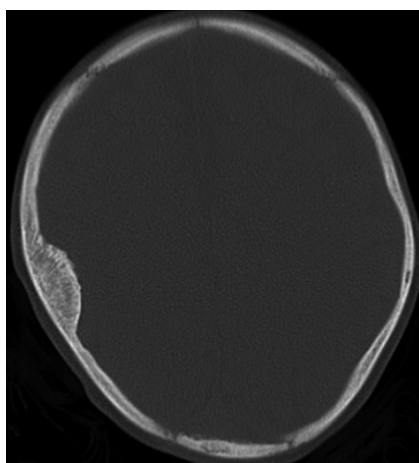


Fig 3. CT scan demonstrating benign-appearing focal diploic expansion and hyperostosis.

that thrombosis of small venous structures associated with the hemangioma or the direct mass effect of the lesion alters local CSF flow dynamics, resulting in hydrocephalus. The mild ventricular dilation in our case may reflect such a prior CSF flow

alteration because we postulated that this lesion was already involuting at diagnosis.

Given that IHs are self-limited, management is dependent on size, location, and any associated complications, which include visual and neurologic deficits for the intracranial lesions. Contemporary management of IH is with propranolol; however, systemic steroid and interferon therapy has been described.^{12,13} In the absence of complicating features, observation in expectation of involution is favored.

Conclusions

We report a new entity of intracranial dural hemangioma, histologically confirmed by Glut-1 staining. The description of the imaging findings and pitfalls in diagnosing this lesion should be considered in assessing durally based lesions in childhood and should help to guide the management of this benign self-limiting lesion.

Disclosures: Alison Wray—UNRELATED: Travel/Accommodations/Meeting Expenses: Medtronic,* Details: educational grant to attend intrathecal baclofen users' group meeting. * Money paid to institution.

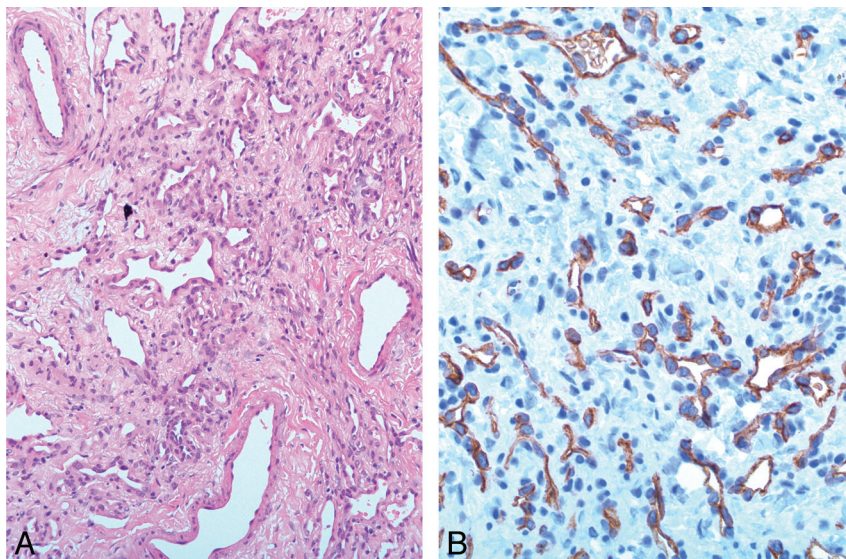


Fig 4. A, Mature fibrous tissue permeated by blood vascular channels of various sizes (hematoxylin-eosin, original magnification $\times 20$ objective). B, Strong, uniform staining of endothelial cells for Glut-1 (immunohistochemical stain, original magnification $\times 40$ objective).

References

- Holland KE, Drolet BA. **Infantile hemangioma.** *Pediatr Clin North Am* 2010;57:1069–83
- Puttgren KB, Pearl M, Tekes A, et al. **Update on pediatric extracranial vascular anomalies of the head and neck.** *Childs Nerv Syst* 2010;26:1417–33
- Abe M, Tabuchi K, Tanaka S, et al. **Capillary hemangioma of the central nervous system.** *J Neurosurg* 2004;101:73–81
- Balaci E, Sumner TE, Auringer ST, et al. **Diffuse neonatal hemangiomatosis with extensive involvement of the brain and cervical spinal cord.** *Pediatr Radiol* 1999;29:441–43
- Bihannic A, Michot C, Heckly A, et al. **Capillary haemangioma arising from the anterior choroidal artery.** *Child's Nervous System* 2005;21:265–71. Epub 2005 Jan 20
- Daenekindt T, Weyns F, Kho KH, et al. **Giant intracranial capillary hemangioma associated with enlarged head circumference in a newborn.** *J Neurosurg* 2008;1:488–92
- Ersay S, Mancini AJ. **Hemifacial infantile hemangioma with intracranial extension: a rare entity.** *Pediatr Dermatol* 2005;22:309–13
- Karikari IO, Selznick LA, Cummings TJ, et al. **Capillary hemangioma of the fourth ventricle in an infant: case report and review of the literature.** *J Neurosurg* 2006; 104(3 suppl):188–91
- Poindexter G, Metry DW, Barkovich AJ, et al. **PHACE syndrome with intracerebral hemangiomas, heterotopia, and endocrine dysfunction.** *Pediatr Neurol* 2007;36:402–06
- Simon SL, Moonis G, Judkins AR, et al. **Intracranial capillary hemangioma: case report and review of the literature.** *Surg Neurol* 2005;64:154–59
- Smith I, Skelton V. **An unusual intracranial tumour presenting in pregnancy.** *Int J Obstet Anesth* 2007;16:82–85
- Tortori-Donati P, Fondelli MP, Rossi A, et al. **Intracranial contrast-enhancing masses in infants with capillary haemangioma of the head and neck: intracranial capillary haemangioma?** *Neuroradiology* 1999;41:369–75
- Tsao MN, Schwartz ML, Bernstein M, et al. **Capillary hemangioma of the cavernous sinus: report of two cases.** *J Neurosurg* 2003;98:169–74
- Viswanathan V, Smith ER, Mulliken JB, et al. **Infantile hemangiomas involving the neuraxis: clinical and imaging findings.** *AJNR Am J Neuroradiol* 2009;30:1005–13
- Watanabe M, Kubo N, Hakozaki S, et al. **Intracranial capillary hemangioma: a case report [in Japanese].** *No Shinkei Geka* 2001;29:1049–54
- Willing SJ, Faye-Petersen O, Aronin P, et al. **Radiologic-pathologic correlation: capillary hemangioma of the meninges.** *AJNR Am J Neuroradiol* 1993;14:529–36
- Nowak DA, Widenka DC. **Spinal intradural capillary haemangioma: a review.** *Eur Spine J* 2001;10:464–72