



Providing Choice & Value
Generic CT and MRI Contrast Agents

**FRESENIUS
KABI**

CONTACT REP

AJNR

Transient Hyperintensity in the Subthalamic Nucleus and Globus Pallidus of Newborns on T1-Weighted Images

T. Taoka, N. Aida, T. Ochi, Y. Takahashi, T. Akashi, T. Miyasaka, A. Iwamura, M. Sakamoto and K. Kichikawa

This information is current as of July 7, 2025.

AJNR Am J Neuroradiol 2011, 32 (6) 1130-1137

doi: <https://doi.org/10.3174/ajnr.A2451>

<http://www.ajnr.org/content/32/6/1130>

ORIGINAL
RESEARCH

T. Taoka
N. Aida
T. Ochi
Y. Takahashi
T. Akashi
T. Miyasaka
A. Iwamura
M. Sakamoto
K. Kichikawa



Transient Hyperintensity in the Subthalamic Nucleus and Globus Pallidus of Newborns on T1-Weighted Images

BACKGROUND AND PURPOSE: In the brains of newborns, changes in signal intensity in most structures can be explained by the development of myelination. However, there are some structures for which signal intensity changes cannot be accounted for by myelination alone. We examined the STN and globus pallidus signal intensities and tried to determine whether a relationship exists between the signal intensity and the postnatal age or the gestational age at the examination.

MATERIALS AND METHODS: We examined T1WI and T2WI obtained from 79 neonates who showed normal development at their 2-year follow-up examinations. We performed both qualitative and quantitative (signal intensity ratio to the thalamus) evaluation of the STN and globus pallidus signals, and we examined the correlation between signal intensity changes and the age of neonates.

RESULTS: With increasing postnatal age at examination, the high signal intensity on the T1WI for both STN and globus pallidus diminished. Although the disappearance of this hyperintensity was well correlated with the postnatal age at examination for both the qualitative and quantitative studies, there was no correlation with gestational age at examination. For the T2WI, there was no correlation with either the postnatal age or the gestational age at examination.

CONCLUSIONS: Signal intensity on T1WI in the STN and globus pallidus is not related to the gestational age at examination; instead, signal intensities on T1WI seem to be more dependent upon the postnatal age at examination.

ABBREVIATIONS: ANOVA = analysis of variance; ROI = region of interest; STN = subthalamic nucleus; T1WI = T1-weighted imaging; T2WI = T2-weighted imaging

The mechanism of myelination in adult and fetal white matter has been studied intensively. The time course for changes in cerebral signal intensity associated with the progression of myelination in the developing brain also has been described in detail.¹⁻⁷ Compared with unmyelinated areas, myelinated regions of the brain exhibit high signal intensity on T1WI and low signal intensity on T2WI. Although changes in signal intensity in most cerebral structures can be explained by the development of myelination, there are some structures for which signal intensity changes cannot be accounted for by myelination alone.⁵

Patients in our neonate intensive care unit are routinely screened for central nervous system abnormalities by using MR imaging. Certain cases among these have displayed unusual signal intensities with respect to cerebral development. In one case, initial examination revealed an extremely high signal intensity in the STN on T1WI, which resembled the thalamic hyperintensity observed in profound asphyxia.⁸ However, the patient showed normal development and no clinical symptoms and the high signal intensity had disappeared on follow-up examinations conducted 2 months after birth (Fig 1A-D). In another instance, although high signal

intensity was observed in the STN and globus pallidus in one patient, no difference in signal intensity compared with surrounding structures was observed in another patient of similar gestational age at the time of MR imaging examination (40 weeks 6 days versus 40 weeks 5 days) (Fig 1E, -F). Based on these observations, we hypothesized that gestational age at examination may not always play a major role in the signal intensity changes noted in structures such as the STN and the globus pallidus in neonates. It is also possible that the high signal intensities sometimes observed in the STN and globus pallidus might be dependent on postnatal age at the time of MR imaging examination. To evaluate these hypotheses, we retrospectively reviewed MR images of patients who had been initially admitted to our neonate intensive care unit but who showed normal development at their 2-year follow-up examinations. STN and globus pallidus signal intensities were qualitatively and quantitatively assessed to determine whether a correlation existed between signal intensity and gestational age and postnatal age at the time of MR imaging examination.

Materials and Methods

Subjects

Subjects comprised neonates with no known developmental abnormalities who were enrolled anonymously in accordance with the experimental protocol approved by our institutional review board. Written informed consent was received from all parents before the start of this retrospective MR imaging study. Image data and clinical data were reviewed from 110 neonates who had undergone brain MR imaging studies in our institute's neonate intensive care unit between January 1 and December 31, 2007. Of these, 13 cases in total with

Received September 21, 2010; accepted after revision October 21.

From the Departments of Radiology (T.T., T.O., T.A., T.M., A.I., M.S., K.K.) and Pediatrics (Y.T.), Nara Medical University, Nara, Japan; and Department of Radiology (N.A.), Kana-gawa Children's Medical Center, Yokohama, Japan.

Paper previously presented at: 69th Annual Meeting of Japan Radiological Society 2010.

Please address correspondence to Toshiaki Taoka, MD, PhD, Department of Radiology, Nara Medical University, 840 Shijo-cho, Kashihara, Nara, 634-8522, Japan; e-mail: ttaoka@naramed-u.ac.jp

DOI 10.3174/ajnr.A2451

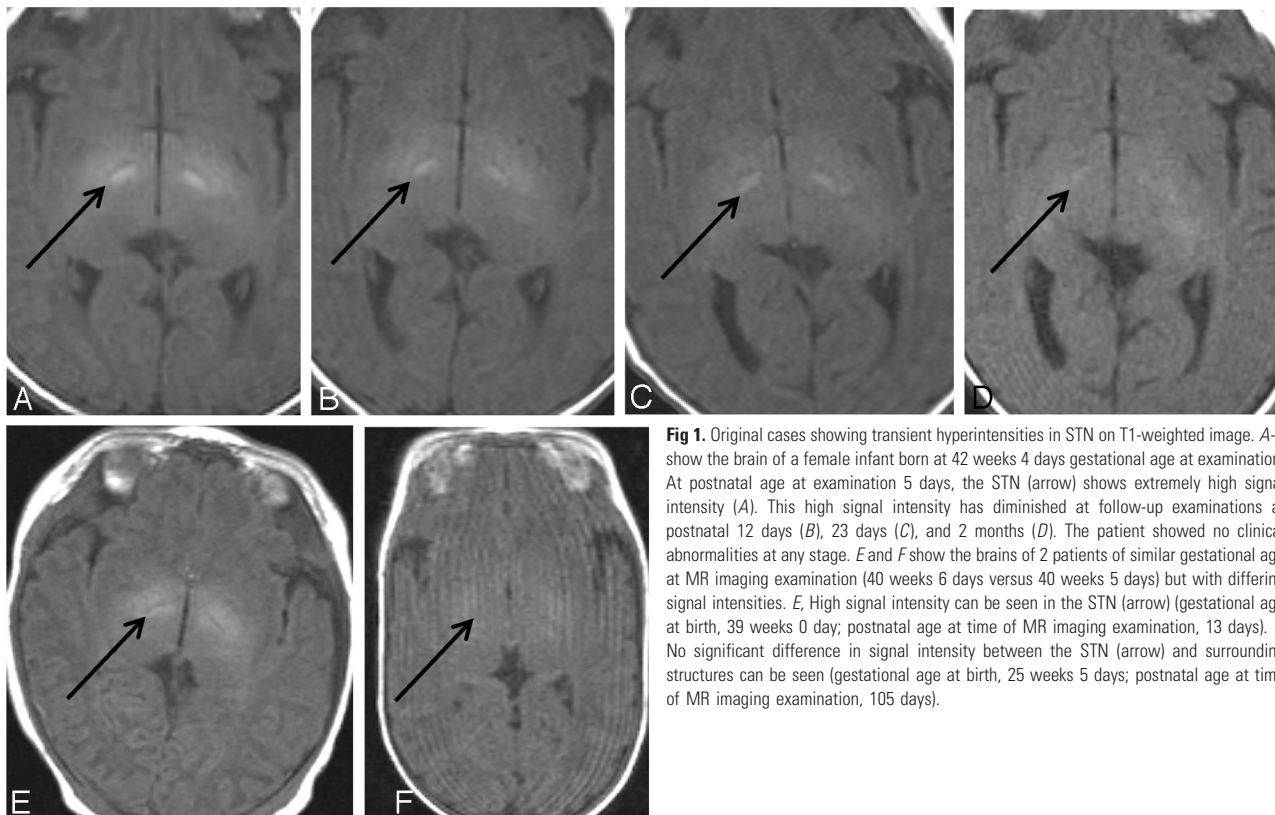


Fig 1. Original cases showing transient hyperintensities in STN on T1-weighted image. *A-D* show the brain of a female infant born at 42 weeks 4 days gestational age at examination. At postnatal age at examination 5 days, the STN (arrow) shows extremely high signal intensity (*A*). This high signal intensity has diminished at follow-up examinations at postnatal 12 days (*B*), 23 days (*C*), and 2 months (*D*). The patient showed no clinical abnormalities at any stage. *E* and *F* show the brains of 2 patients of similar gestational age at MR imaging examination (40 weeks 6 days versus 40 weeks 5 days) but with differing signal intensities. *E*, High signal intensity can be seen in the STN (arrow) (gestational age at birth, 39 weeks 0 day; postnatal age at time of MR imaging examination, 13 days). *F*, No significant difference in signal intensity between the STN (arrow) and surrounding structures can be seen (gestational age at birth, 25 weeks 5 days; postnatal age at time of MR imaging examination, 105 days).

documented pathologic status within the central nervous system were excluded from analysis. These cases included congenital cytomegalovirus infection, hydrocephalus ($n = 2$), intracranial hematoma, chromosomal abnormality ($n = 2$), Langerhans cell histiocytosis, myotonic dystrophy, periventricular leukomalacia ($n = 2$), hyperinsulinemia, epilepsy of unknown cause, and congenital ichthyosis. We

also excluded 9 cases that were lost to follow-up 2 years after birth due to change of address and 9 cases that exhibited development outside the normal range. Criteria for normal development were based on the Enjoji Infantile Developmental Test.⁹ After exclusions, the remaining 79 subjects were divided into 3 groups based on their clinical status at birth. The “normal” group had neither neonate jaundice nor asphyxia

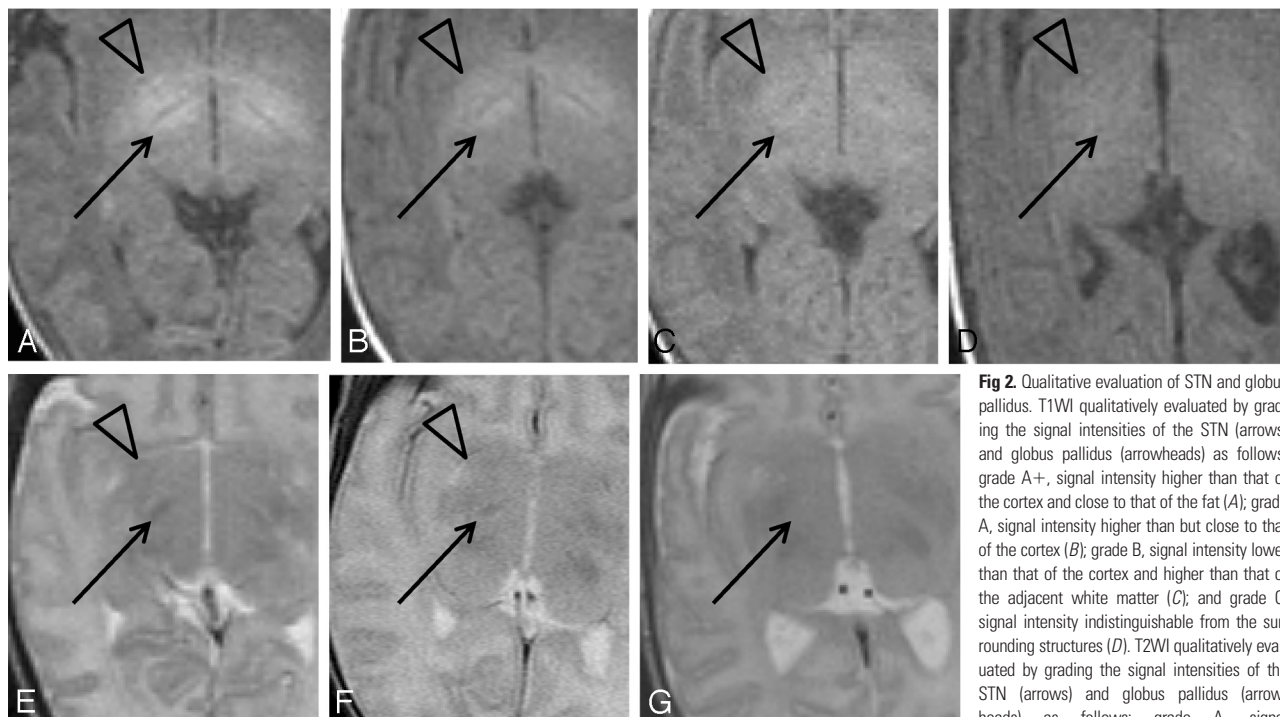

Fig 2. Qualitative evaluation of STN and globus pallidus. T1WI qualitatively evaluated by grading the signal intensities of the STN (arrows) and globus pallidus (arrowheads) as follows: grade A+, signal intensity higher than that of the cortex and close to that of the fat (*A*); grade A, signal intensity higher than but close to that of the cortex (*B*); grade B, signal intensity lower than that of the cortex and higher than that of the adjacent white matter (*C*); and grade C, signal intensity indistinguishable from the surrounding structures (*D*). T2WI qualitatively evaluated by grading the signal intensities of the STN (arrows) and globus pallidus (arrowheads) as follows: grade A, signal intensity lower than that of the cortex (*E*); grade B, signal intensity higher than that of the cortex and lower than that of the adjacent white matter (*F*); and grade C, signal intensity indistinguishable from surrounding structure. There are no cases with globus pallidus grade C; therefore, *G* shows a case with STN grade C and globus pallidus grade B.

intensity lower than that of the cortex (*E*); grade B, signal intensity higher than that of the cortex and lower than that of the adjacent white matter (*F*); and grade C, signal intensity indistinguishable from surrounding structure. There are no cases with globus pallidus grade C; therefore, *G* shows a case with STN grade C and globus pallidus grade B.

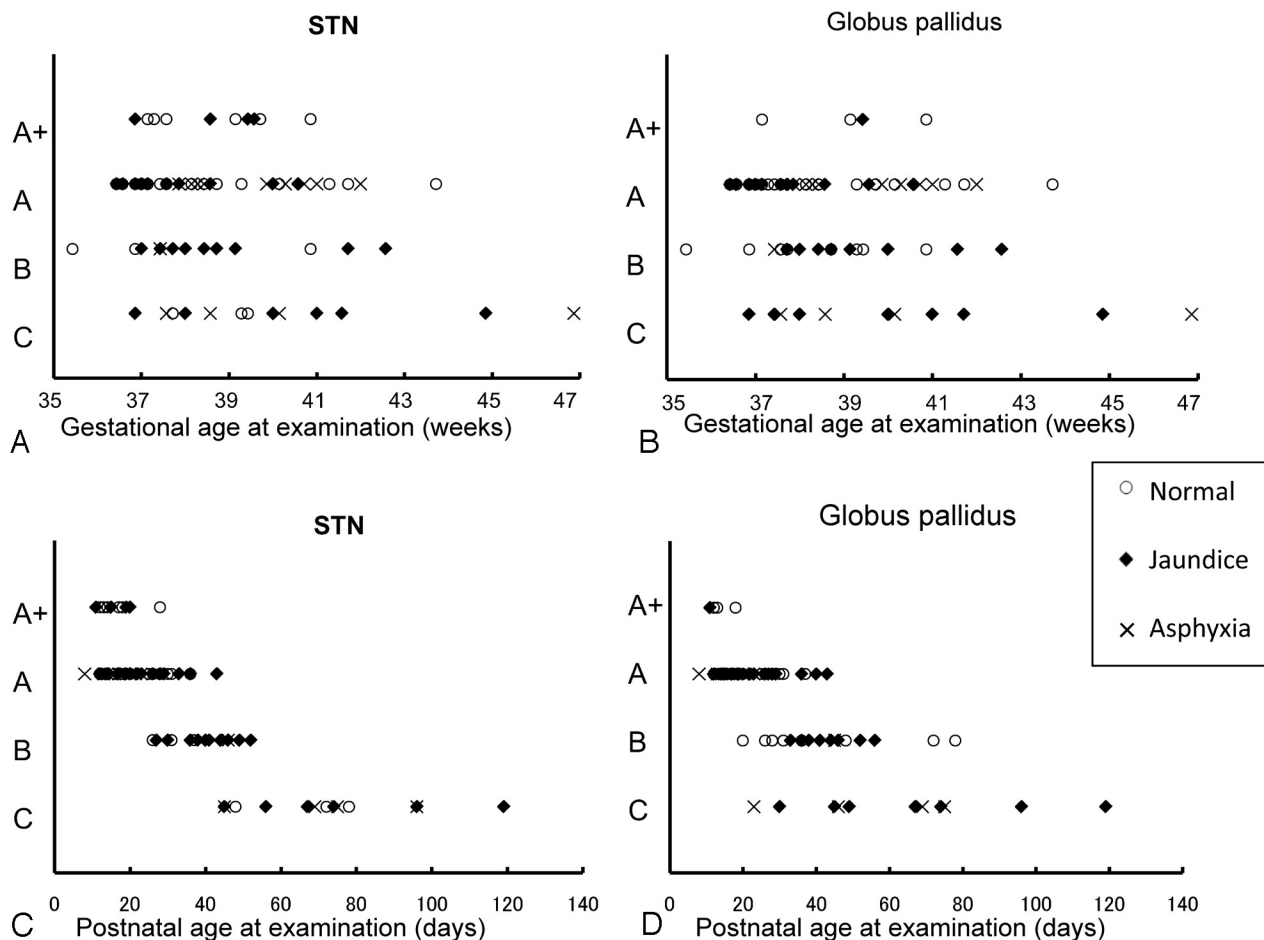


Fig 3. Qualitative evaluation of STN and globus pallidus signal intensities on T1-weighted images. Relationships between age and quantitative grade of signal intensity are shown. *A*, Gestational age at examination and STN. *B*, Gestational age at examination and globus pallidus. *C*, Postnatal age at examination and STN. *D*, Postnatal age at examination and globus pallidus. *A* and *B* show considerable overlap in gestational ages at examination among the grades. The grades for the STN and globus pallidus tend to be lower in subjects whose gestational age at examination was ≥ 44 weeks; however, no other marked trends are observed among the 3 groups. *C* and *D* show a distinct tendency for the signal intensities of both STN and globus pallidus to decrease among the 3 groups as postnatal age increases. Normal, jaundice, and asphyxia subjects are plotted separately.

($n = 30$); the “jaundice” group exhibited jaundice and required phototherapy but did not develop kernicterus ($n = 35$); and the “asphyxia” group exhibited birth asphyxia, with an Apgar score < 7 at 1 minute after birth ($n = 14$). One subject with both birth asphyxia and jaundice was placed into the asphyxia group. The subjects were fed by maternal or artificial milk via bottle or tube.

Imaging and Data Analysis

MR imaging was performed with a 1.5T clinical MR unit (Magnetom Sonata; Siemens, Erlangen, Germany), with a standard infant head coil. All examinations included axial sections of conventional spin-echo T1-weighted (TR = 500 ms, TE = 12 ms) and spin-echo T2-weighted (TR = 4000 ms, TE = 120 ms) sequences and sagittal T1-weighted and coronal T2-weighted sequences. Section thickness was 6 mm, with a 2-mm gap. Images were obtained by using a 256×256 displayed matrix and a 230-mm FOV.

We made qualitative and quantitative analyses of the signal intensities in the STN and globus pallidus. Qualitative analyses of the signal intensities in the STN and globus pallidus were performed by 2 neuroradiologists based on MR images. For qualitative analysis of T1WI, STN and globus pallidus signals were classified as follows (Fig 2A-D): grade A+, signal intensity higher than that of the cortex and close to that of the fat; grade A, signal intensity higher than but close to that of

the cortex; grade B, signal intensity lower than that of the cortex and higher than that of the adjacent white matter; and grade C, signal intensity indistinguishable from the adjacent white matter or thalamus. For qualitative analysis of T2WI, STN and globus pallidus signals were classified as follows (Fig 2E-G): grade A, signal intensity lower than that of the cortex; grade B, signal intensity higher than that of the cortex and lower than that of the adjacent white matter; and grade C, signal intensity indistinguishable from the surrounding structures. For quantitative analysis, ROIs were set in the STN, globus pallidus, and thalamus, and STN/thalamus and globus pallidus/thalamus ratios were calculated. Each ROI cursor was circular, with a 5-mm diameter for the STN and a 1-cm diameter for the globus pallidus and thalamus.

We defined the terms concerning chronologic age of the neonate in the current study as follows: “postnatal age at examination” refers to the period from birth to the day of the MR imaging examination; gestational age at birth refers to the age of the neonate at birth based on the number of weeks gestation, ie, from the first day of the last menstrual period to the day of delivery, and “gestational age at examination” refers to the age of the neonate at the day of the MR imaging examination based on the number of weeks gestation, ie, from the first day of the last menstrual period to the day of the MR examination.

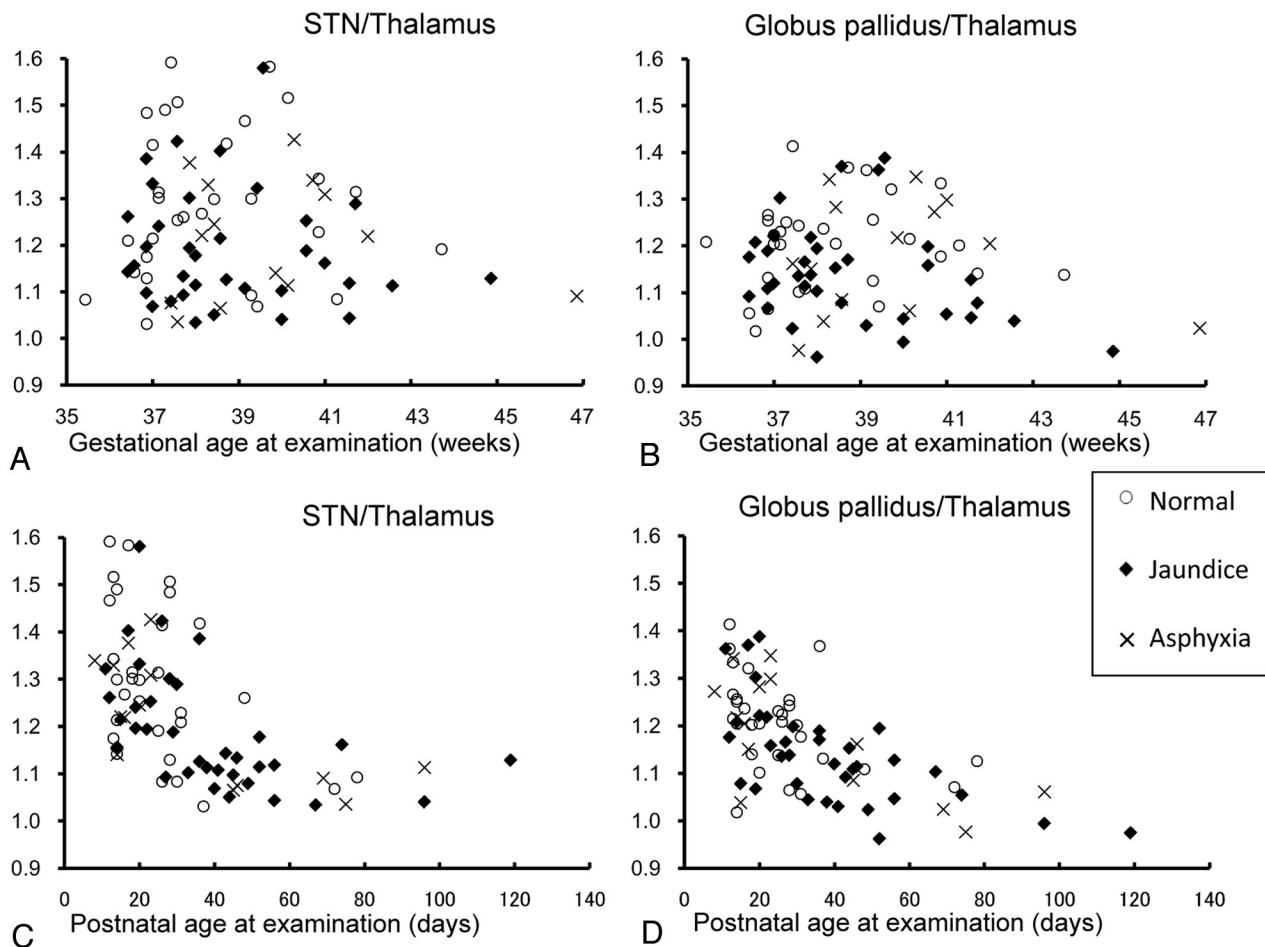


Fig 4. Quantitative evaluation of STN and globus pallidus signal intensities compared with the thalamus on T1-weighted images. Relationships between age and signal intensity ratio to the thalamus are shown. *A*, Gestational age at examination and STN/thalamus. *B*, Gestational age at examination and globus pallidus/thalamus. *C*, Postnatal age at examination and STN/thalamus. *D*, Postnatal age at examination and globus pallidus/thalamus. The ratios of STN/thalamus and globus pallidus/thalamus tend to be lower in subjects whose gestational age at examination was ≥ 44 weeks; however, no other marked trends are observed among the 3 groups (*A* and *B*). *C* and *D* show a distinct tendency among the 3 groups for the signal intensity ratio of both STN/thalamus and globus pallidus/thalamus to decrease as postnatal age at examination increases. Normal, jaundice, and asphyxia groups are plotted separately.

Regarding gestational age at examination, results were categorized into 3 groups: ≤ 37 , 38–39, and ≥ 40 weeks at the time of MR imaging examination. Regarding postnatal age at examination, results were grouped as follows: ≤ 19 , 20–39, and ≥ 40 days at the time of MR imaging examination (Figs 3 and 4). An ANOVA was used to compare the ratios (STN/thalamus, globus pallidus/thalamus) for the gestational age at examination and postnatal age at examination groups (Fig 5). The ratios (STN/thalamus, globus pallidus/thalamus) also were evaluated among the normal, jaundice, and asphyxia groups. A separate ANOVA for these 3 groups also was performed among subjects whose postnatal age at examination was ≤ 40 days (Fig 6A, -B). The ratios (STN/thalamus, globus pallidus/thalamus) also were evaluated for the gestational age at birth groups of ≤ 33 , 34–36, and ≥ 37 weeks. An ANOVA also was performed for these groups among subjects in whom the postnatal age at examination was ≤ 40 days (Fig 6C, -D). Qualitative and quantitative analysis were also performed for T2WI (Figs 7 and 8).

Results

Results of qualitative grading (Fig 3) and quantitative measurements (Fig 4) on T1WI were arranged in order of gestational age at examination and postnatal age at the time of MR

imaging examination. Figure 3 shows the relation between qualitative grading and chronologic ages on T1WI. There was considerable overlap of corrected gestational age at examination among the grades. Conversely, there were certain tendencies observed between the grades and the postnatal age at examination as follows. For the STN, grade A+ was only seen in subjects ≤ 40 days after birth, whereas grade C was only seen ≥ 40 days after birth. For the globus pallidus, grade A+ was only seen in subjects ≤ 20 days after birth, whereas grade C was only seen ≥ 20 days after birth.

The relationship between quantitative grading on T1WI and gestational age at examination is summarized in Fig 4, showing the correlation between the STN/thalamus and globus pallidus/thalamus ratios, and the gestational age at examination and postnatal age at the time of MR imaging examination. As with the qualitative evaluation, there were no distinct tendencies noted with regard to gestational age at examination, especially within 43 weeks. Conversely, there was a negative correlation between the ratios and postnatal age at the time of MR imaging examination for both STN/thalamus ($r = -0.55$, $P < .001$) and globus pallidus/thalamus ($r = -0.61$, $P < .001$).

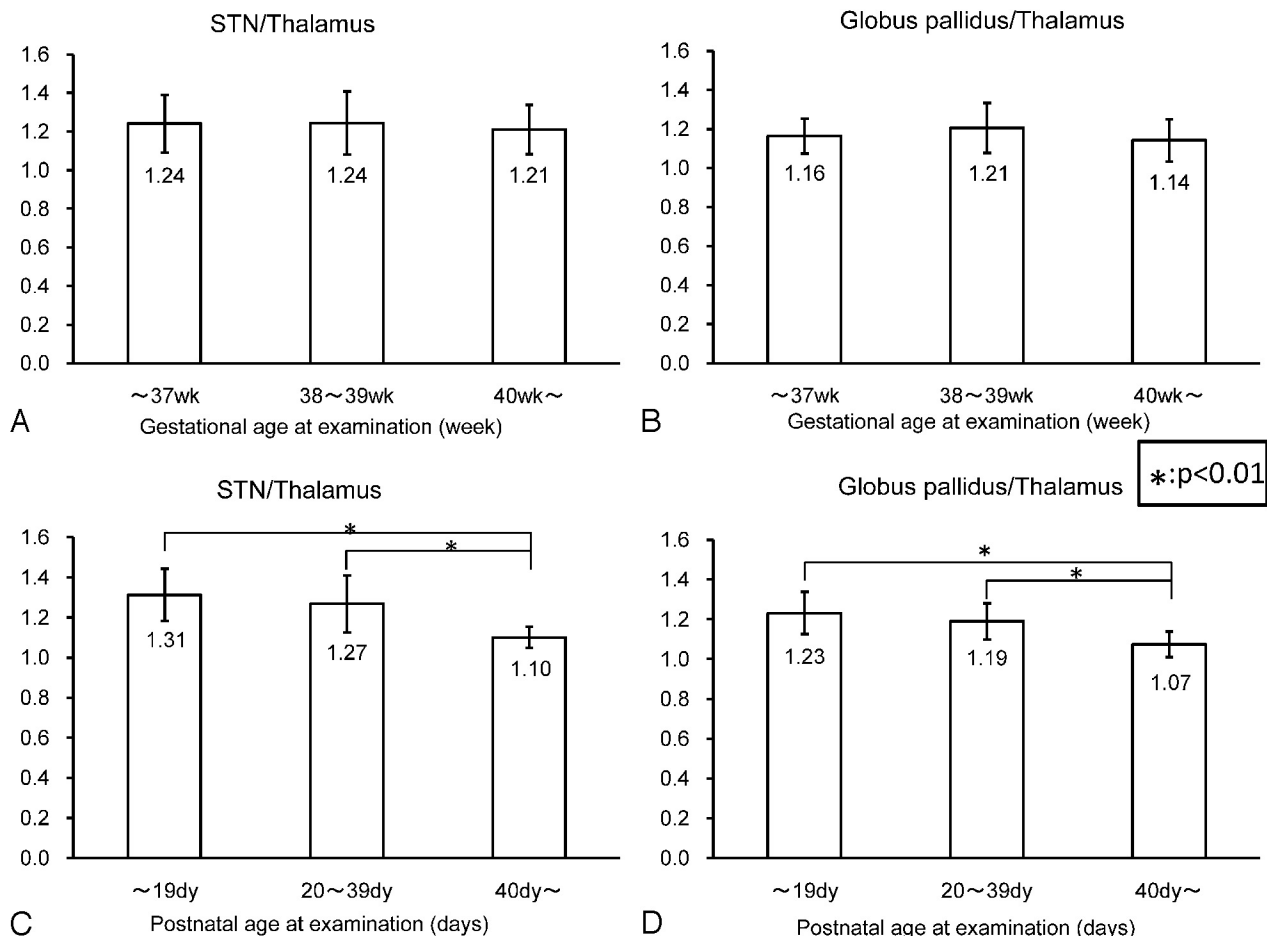


Fig 5. Statistical analysis of STN/thalamus and globus pallidus/thalamus ratios on T1-weighted images. *A* and *B*, Mean STN/thalamus and globus pallidus/thalamus ratios according to gestational age at examination (≤ 37 , 38–39, and ≥ 40 weeks). There is no statistically significant difference among the 3 age groups. *C* and *D*, Mean STN/thalamus and globus pallidus/thalamus ratios according to postnatal age at examination (≤ 19 , 20–39, and ≥ 40 days). ANOVA shows a statistically significant difference ($P < .01$) between < 19 and > 40 days and 20–39 and > 40 days.

Statistical evaluation of the quantitative measurement and the ages is shown in Fig 5. There was no statistically significant difference observed between the 3 gestational age at examination groups. However, statistically significant differences ($P < .01$) were noted among the 3 postnatal age at examination groups for both STN/thalamus and globus pallidus/thalamus.

Evaluations of the difference in the STN/thalamus and globus pallidus/thalamus ratios among the normal, jaundice, and asphyxia group subjects are shown in Fig 6A,–B. There were no statistically significant differences found among the 3 groups for either STN/thalamus or globus pallidus/thalamus. Figure 6C, –D provides an evaluation of the difference in the ratios among the groups whose gestational age at birth were ≤ 33 , 34–36, and ≥ 37 weeks. There were no statistically significant differences among the 3 groups.

On T2WI, changes in signal intensity according to neonate age were not observed for either gestational age or postnatal age at the time of MR imaging examination. In the qualitative evaluation, 62.0% (49/79) of the subjects received grade A for the STN, whereas 87.3% (69/79) of the subjects were grade B for the globus pallidus, regardless of gestational age at examination or postnatal age at examination (Fig 7). Quantitative evaluation also found no statistically significant differences for these groups (Fig 8).

Discussion

Signal intensities of structures in the infant brain undergo dynamic changes in accordance with cerebral development.^{1–7,10} These changes are believed to be mainly due to myelination and a decrease in cerebral water content.¹¹ There are several studies reporting the time course of this signal intensity change in the term or preterm infant or fetus in terms of gestational age at examination, and those studies successfully proved the signal intensity change in most of the structure in the brain.^{3,6} In general, compared with unmyelinated white matter, myelinated white matter of the brain shows high signal intensity on T1WI and low signal intensity on T2WI.

The present study found high-intensity signals on T1WI in the STN and globus pallidus of neonate brains as in previous reports.^{3,12} However, these areas of hyperintensity diminished in older subjects and thus seem to be a transient phenomenon. Disappearance of this hyperintensity was well correlated with postnatal age at examination on both qualitative and quantitative evaluation, whereas gestational age at examination, history of jaundice or transient asphyxia, and gestational age at birth showed no correlation to T1WI hyperintensity. Although hypointensities were observed on T2WI in both the STN and globus pallidus in most subjects, there was no significant correlation to postnatal age or gestational age at examination.

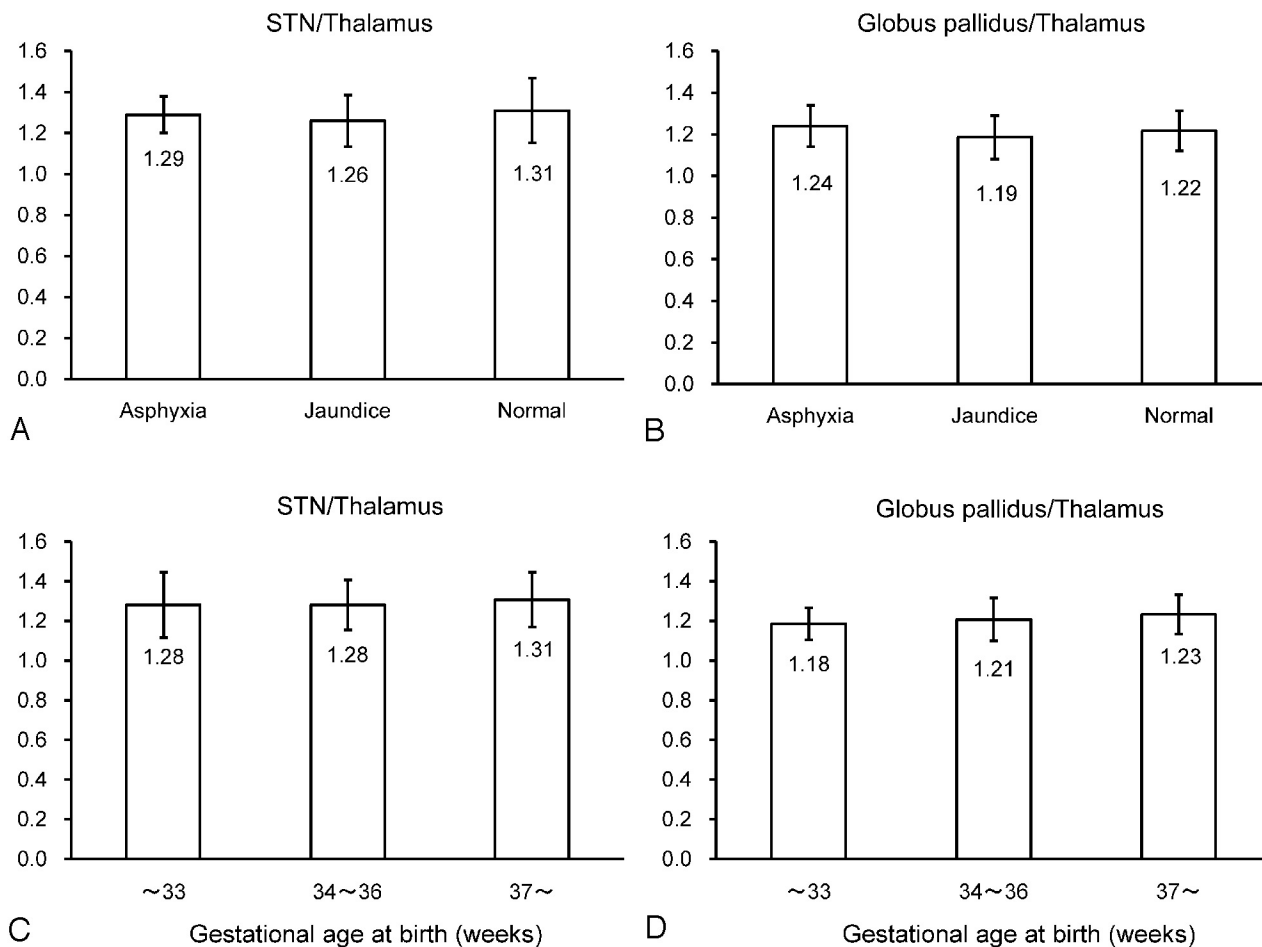


Fig 6. Statistical analysis on T1-weighted images based on clinical status groups and gestational ages at birth. Statistical analysis of STN/thalamus (A) and globus pallidus/thalamus (B) ratios on T1-weighted images among the 3 clinical status groups (normal, jaundice, and asphyxia). There are no statistically significant differences among the 3 groups. Statistical analysis of the differences in STN/thalamus (C) and globus pallidus/thalamus (D) ratios on T1WI among the groups whose gestational age at birth are ≤ 33 , 34–36, and ≥ 37 weeks. There are no statistically significant differences among the 3 groups.

Hyperintensity on T1WI is caused by various factors, mainly paramagnetic effect and immobilization of water molecules. The former includes metal ions, melanin, or free radicals, and the latter includes concentrated solutions of proteins, calcified tissue, and lipids. Myelination is another important cause of hyperintensity on T1WI²; however, it is not involved in all cases. Korogi et al⁵ evaluated perinatal MR imaging signal intensity of the perirolandic gyri and compared the images with histologic findings. They found that though the pre- and postcentral gyri of infants aged postnatal 41–44 weeks showed high-intensity signals on T1WI, histologic examination revealed very little myelination of the respective nerve fibers. They speculate that the changes in signal intensity in the perirolandic gyri may reflect not only the degree of myelination but also the more advanced neuronal development associated with rapid proliferation and formation of oligodendroglial cells, synapses, and dendrites. Similarly, glial activation or glial reaction may be another cause of T1 hyperintensity. Fujioka et al¹³ reported hyperintensity in the putamen of rats with transient ischemia and obtained MR imaging findings with a similar time course to that of the accumulation of tissue manganese accompanied by manganese-superoxide dismutase induction in reactive astrocytes. Hemicholea-hemiballism is known to be associated with T1 hyperintensity in the unilateral basal ganglia. Shan

et al¹⁴ reported that biopsy of a T1WI high-signal intensity lesion in a case of hemiballism indicated the role of reactive microglia, and they suggested that manganese accumulation in reactive astrocytes is the most likely cause. Therefore, these conditions could be classified as “glia-related hyperintensity.”

The mechanism for the phenomenon seen in the present study might be development-associated myelination of the white matter surrounding the areas of high signal intensity, resulting in a decrease in the relative signal intensities between the structures over time. However, if myelination is responsible for the signal intensity changes, there should be a close correlation with the gestational age at examinations. Therefore, we speculate that this is an intrinsic phenomenon within the neonate STN and globus pallidus. Various processes other than myelination take place within the developing cerebral tissue, including neuronal development, which is associated with the rapid proliferation and formation of oligodendroglial cells, synapses, and dendrites as mentioned above.⁵ It also has been suggested that a glutamatergic pathway transiently innervates the globus pallidus during the mammalian perinatal period.¹⁵ This kind of transient innervation may cause synaptic and dendritic formation, resulting in T1 hyperintensity in this region. A stressful environment at delivery may be one

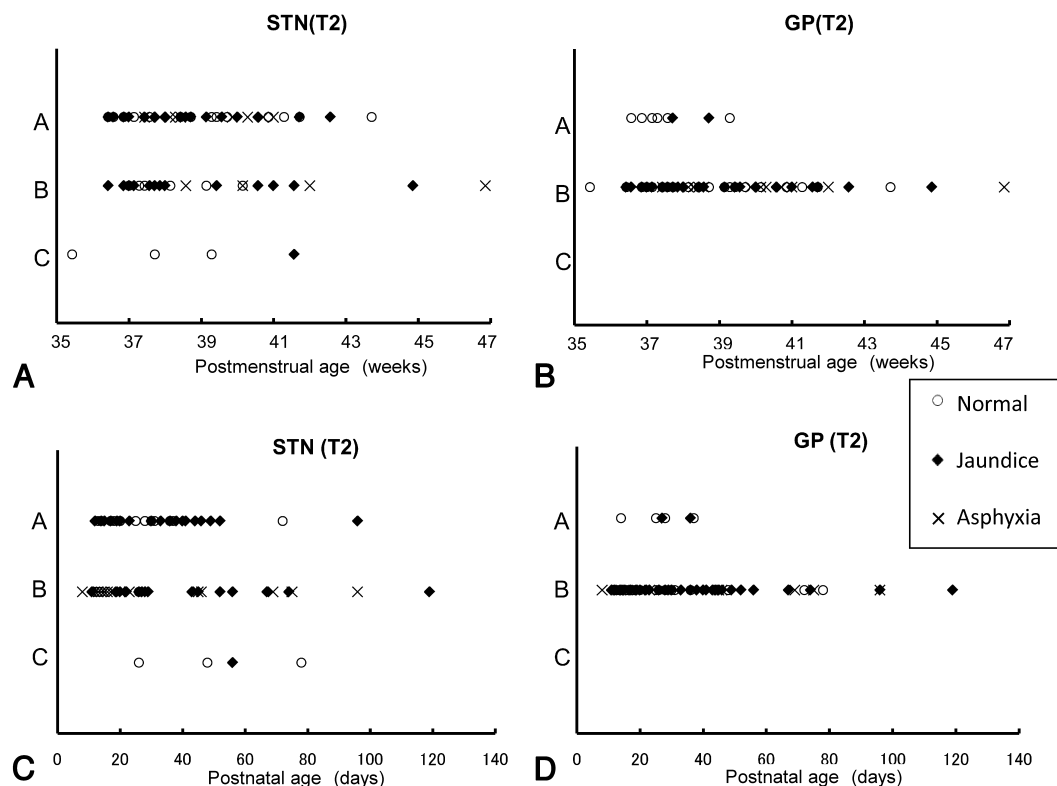


Fig 7. Qualitative evaluation of STN and globus pallidus signal intensities on T2-weighted images. Relationships between age and quantitative grade of signal intensity are shown. *A*, Gestational age at examination and STN. *B*, Gestational age at examination and globus pallidus. *C*, Postnatal age at examination and STN. *D*, Postnatal age at examination and globus pallidus. Trends in signal intensity changes are not observed among the 3 groups for either gestational age at examination or postnatal age at examination. Most subjects show grade A for the STN (62.0%; 49/79) and grade B for the globus pallidus (87.3%; 69/79) regardless of the gestational age at examination or postnatal age at examination. Normal, jaundice, and asphyxia subjects are plotted separately.

cause of cerebral glial reaction, and this may lead to hyperintensity on T1WI. Thus, mechanisms related to glia formation or glial reaction may play a role in neonate STN and globus pallidus hyperintensity. Therefore, the signal intensity changes seen in the current study on T1WI may be due to the glia-related hyperintensity that was mentioned above.

Maternal or fetal hormones also play role in neonate cerebral development. For example, thyroid gland function develops and matures during the fetal stage and is essential for brain maturation. Maternal thyroid hormone plays an important role in early cerebral development and is required for normal fetal corticogenesis during early pregnancy.¹⁶ Thyroid function also changes dynamically before and after delivery, and preterm infants have low thyroxine and free thyroxine values in the first weeks after birth. This transient hypothyroxinemia may influence certain brain structures, and the degree of postnatal thyroid hormone surge is influenced by gestational age.^{17,18} Although the precise relationship with the STN and globus pallidus remains to be established, these maternal and fetal/infant hormones might play some role in the development of these structures and result in the signal intensity changes observed on MR imaging in the present study. Normal signal intensity changes also are seen in other parts of the brain such as anterior pituitary lobe that also depends on postnatal age. Kitamura et al¹⁹ reported that signal intensity pattern changes in the anterior lobe of the pituitary gland depend on postnatal age at examination rather than gestational age. In their report, the anterior lobe of the pituitary gland showed a high signal intensity immediately after birth that gradually de-

creased as postnatal age increased. Gestational age at examination did not seem to influence this change. They proposed that this phenomenon was due to hyperactivity of the pituitary anterior lobe. This report indicates that gestational age at examination is not the only factor that determines signal intensity changes within the developing brain.

There are several limitations to the present study. Although we assumed the subject population to be normal and conducted a follow-up clinical study at postnatal 2 years to confirm normal development, all subjects had been admitted to our neonate intensive care unit for observation of any perinatal problems leading to potential bias. Furthermore, because this was a retrospective study of normal subjects, no histologic data could be obtained and the relationship between T1-signal intensity and STN and globus pallidus histology was not verified. This prevented further elucidation of the mechanism involved in signal intensity changes. With regard to the quantitative study, the quantification was simply the ratio between STN/globus pallidus and the thalamus and may itself reflect signal intensity changes according to the degree of myelination within the thalamus.

Conclusions

We examined the STN and globus pallidus signal intensities in the brains of neonates and tried to determine whether a relationship existed between the signal intensity and the postnatal age or the gestational age at examination. Hyperintensities on T1WI in the STN and globus pallidus were observed. These

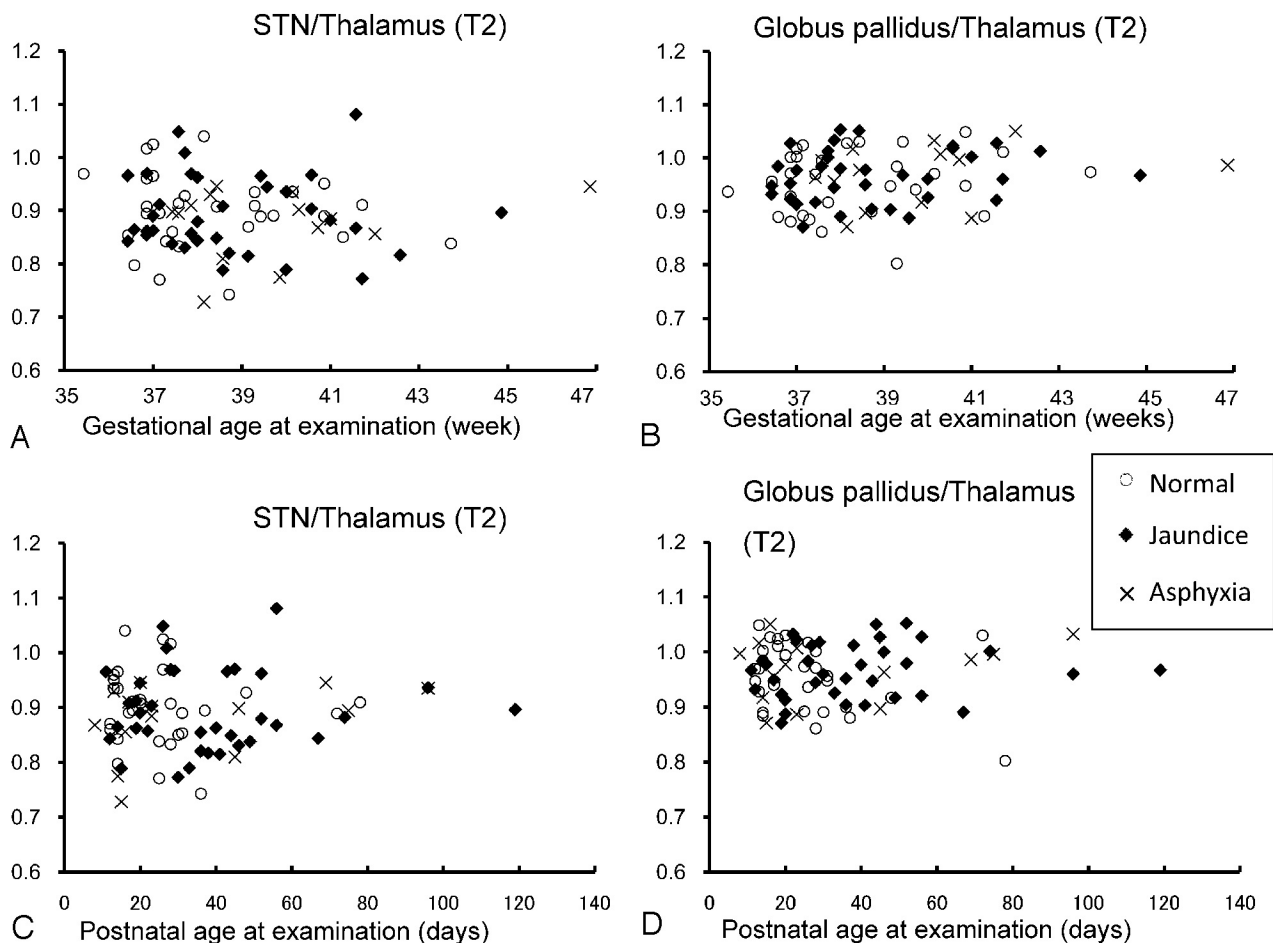


Fig 8. Quantitative evaluation of STN and globus pallidus signal intensities compared with the thalamus on T2-weighted images. Relationships between age and signal intensity ratio to the thalamus are shown. *A*, Gestational age at examination and STN/thalamus. *B*, Gestational age at examination and globus pallidus/thalamus. *C*, Postnatal age at examination and STN/thalamus. *D*, Postnatal age at examination and globus pallidus/thalamus. No chronologic changes in ratios are observed among the 3 groups for either gestational age at examination or postnatal age at examination. Statistical evaluations also demonstrate no significant differences. Normal, jaundice, and asphyxia subjects are plotted separately.

hyperintensities diminished in older subjects and thus seem to be a transient phenomenon. Disappearance of this hyperintensity was well correlated with postnatal age at examination but was not related to gestational age at examination, history of jaundice, transient asphyxia, or gestational age at birth. It is important to be aware of this transient high signal intensity on STN and globus pallidus in the neonate brain so that we do not misinterpret high signal intensity as being due to tissue damage by profound asphyxia.

References

1. Barkovich AJ. Concepts of myelin and myelination in neuroradiology. *AJNR Am J Neuroradiol* 2000;21:1099–109
2. Barkovich AJ, Kjos BO, Jackson DE, Jr., et al. Normal maturation of the neonatal and infant brain: MR imaging at 1.5 T. *Radiology* 1988;166:173–80
3. Counsell SJ, Maalouf EF, Fletcher AM, et al. MR imaging assessment of myelination in the very preterm brain. *AJNR Am J Neuroradiol* 2002;23:872–81
4. Dietrich RB, Bradley WG, Zaragoza EJ, et al. MR evaluation of early myelination patterns in normal and developmentally delayed infants. *AJR Am J Roentgenol* 1988;150:889–96
5. Korogi Y, Takahashi M, Sumi M, et al. MR signal intensity of the periorbital cortex in the neonate and infant. *Neuroradiology* 1996;38:578–84
6. Nakagawa H, Iwasaki S, Kichikawa K, et al. Normal myelination of anatomic nerve fiber bundles: MR analysis. *AJNR Am J Neuroradiol* 1998;19:1129–36
7. van der Knaap MS, Valk J. MR imaging of the various stages of normal myelination during the first year of life. *Neuroradiology* 1990;31:459–70
8. Barkovich AJ, Sargent SK. Profound asphyxia in the premature infant: imaging findings. *AJNR Am J Neuroradiol* 1995;16:1837–46
9. Hokama T, Gushi Ken M, Nosoko N. Iron deficiency anaemia and child development. *Asia Pac J Public Health* 2005;17:19–21
10. Wuttikul C, Taoka T, Akashi T, et al. Prominent signal intensity of T1/T2 prolongation in subcortical white matter of the anterior temporal region on conventional screening MRI of late preterm infants with normal development. *Magn Reson Imaging* 2008;26:1374–80
11. McArdle CB, Richardson CJ, Nicholas DA, et al. Developmental features of the neonatal brain: MR imaging. Part I. Gray-white matter differentiation and myelination. *Radiology* 1987;162:223–29
12. Tortori-Donati P. *Pediatric Neuroradiology: Brain, Head, Neck and Spine*. Berlin: Springer-Verlag;2005
13. Fujioka M, Taoka T, Matsuo Y, et al. Magnetic resonance imaging shows delayed ischemic striatal neurodegeneration. *Ann Neurol* 2003;54:732–47
14. Shan DE, Pan HC, Ho DM, et al. Presence of activated microglia in a high-signal lesion on T1-weighted MR images: a biopsy sample re-examined. *AJNR Am J Neuroradiol* 2007;28:602
15. Greenamyre T, Penney JB, Young AB, et al. Evidence for transient perinatal glutamatergic innervation of globus pallidus. *J Neurosci* 1987;7:1022–30
16. de Escobar GM, Obregon MJ, del Rey FE. Maternal thyroid hormones early in pregnancy and fetal brain development. *Best Pract Res Clin Endocrinol Metab* 2004;18:225–48
17. van Wassenar AG, Kok JH, Dekker FW, et al. Thyroid function in very preterm infants: influences of gestational age and disease. *Pediatr Res* 1997;42:604–09
18. Van Wassenar AG, Kok JH, Briet JM, et al. Thyroid function in very preterm newborns: possible implications. *Thyroid* 1999;9:85–91
19. Kitamura E, Miki Y, Kawai M, et al. T1 signal intensity and height of the anterior pituitary in neonates: correlation with postnatal time. *AJNR Am J Neuroradiol* 2008;29:1257–60