



Discover Generics

Cost-Effective CT & MRI Contrast Agents



WATCH VIDEO

AJNR

Percutaneous Balloon Kyphoplasty with the Patient under Intravenous Analgesia and Sedation: A Feasibility Study

M. Mohr, D. Pillich, M. Kirsch, J.U. Mueller, S. Fleck, N. Hosten and S. Langner

This information is current as of June 23, 2025.

AJNR Am J Neuroradiol 2011, 32 (4) 649-653

doi: <https://doi.org/10.3174/ajnr.A2345>

<http://www.ajnr.org/content/32/4/649>

ORIGINAL
RESEARCH

M. Mohr
D. Pillich
M. Kirsch
J.U. Mueller
S. Fleck
N. Hosten
S. Langner

Percutaneous Balloon Kyphoplasty with the Patient under Intravenous Analgesia and Sedation: A Feasibility Study

BACKGROUND AND PURPOSE: Kyphoplasty is a minimally invasive procedure for the treatment of malignant or osteoporotic vertebral compression fractures, normally performed with the patient under general anesthesia. This may cause a therapeutic dilemma because these patients often have a very high risk for general anesthesia due to concomitant diseases. The aim of this study was to evaluate the safety and feasibility of percutaneous kyphoplasty by using IV anesthesia and sedation with midazolam and piritramide.

MATERIALS AND METHODS: From June 2007 to June 2009, we prospectively included 133 patients (77 women, 56 men; mean age, 69.18 ± 11.45 years) who were referred for BKP. Kyphoplasty was always performed under fluoroscopic guidance with a biplane angiographic system by using a transpedicular or extrapedicular approach. The individual anesthesia risk was assessed by using the ASA criteria. All procedures were performed with the patient under IV anesthesia and sedation with fractionated administration of midazolam and piritramide. Pain was assessed before and after treatment by using a VAS.

RESULTS: Ninety-nine patients (74.4%) had a significantly increased risk for general anesthesia (ASA score, ≥ 3). A total of 162 kyphoplasty procedures were performed. The mean amounts of midazolam and piritramide used were 11.3 ± 4.38 mg and 11.8 ± 3.98 mg, respectively. No complications related to IV anesthesia and sedation occurred. Periprocedural pain management was rated as sufficient, and all patients would undergo the procedure again.

CONCLUSIONS: Percutaneous BKP with the patient under IV anesthesia and sedation with midazolam and piritramide is a safe and feasible method for treating vertebral compression fractures in patients with an increased risk for general anesthesia.

ABBREVIATIONS: ASA = American Society of Anesthesiologists; BKP = balloon kyphoplasty; IV = intravenous; VAS = visual analog scale; VB = vertebral body; VP = vertebroplasty

BKP and VP are 2 minimally invasive percutaneous interventions for the treatment of several vertebral diseases.¹ Vertebral compression fractures related to osteoporosis¹ and due to malignant causes² are the main pathologic conditions treated. Both approaches have been investigated in numerous studies and are considered to be equally effective in relieving pain and restoring mobility.^{3,4}

Published data indicate that VP is generally performed with the patient under local anesthesia with conscious sedation.^{3,5,6} BKP, which is technically more demanding and complex, is typically performed with the patient under general anesthesia.⁶⁻⁸ However, patients undergoing this treatment are generally older and have numerous illnesses simultaneously,^{4,9} increasing the risk of anesthesia-related complications. There are a number of studies describing the anesthesia procedures used for VP,^{10,11} but to the best of our knowledge, there is no report about BKP with the patient under conscious sedation in the literature so far.

The aim of our study was to evaluate the clinical feasibility

and safety of performing BKP in osteoporotic and metastatic vertebral fractures by using conscious sedation with piritramide and midazolam.

Materials and Methods

The study was approved by the local ethics committee, and written informed consent was obtained from all patients.

Between June 2007 and June 2009, 133 consecutive patients were prospectively included in the study. There were 77 women and 56 men with a mean age of 69.18 ± 11.45 years (median, 70 years; range, 22–90 years). Indications for BKP were established by a multidisciplinary neurosurgical-neuroradiologic team.

Vertebral fractures were classified according to the scheme proposed by Magerl et al.¹² The 3 types of fractures in this classification have a fundamental pattern, which is determined by the 3 most important mechanisms of injury: compression, distraction, and axial torque. Type A lesions focus on the injury to the vertebral body (vertebral compression fracture). Type B injuries are characterized by disruption either anteriorly or posteriorly, and type C lesions are injury patterns resulting from axial torque. Eligible patients had 1 or several acute vertebral compression fractures (Magerl type A) or metastatic disease of the thoracic and lumbar spine with a risk of vertebral collapse. The patients included had clinical signs and symptoms related to the affected vertebra. Not included were vertebral fractures due to trauma in patients younger than 30 years of age, fractures involving the posterior border with posterior displacement of a frag-

Received July 13, 2010; accepted after revision August 23.

From the Institute for Diagnostic Radiology and Neuroradiology (M.M., M.K., N.H., S.L.) and Department of Neurosurgery (D.P., J.U.M., S.F.), Ernst-Moritz-Arndt-University Greifswald, Greifswald, Germany.

Please address correspondence to Soenke Langner, MD, Institute for Diagnostic Radiology and Neuroradiology, Ernst-Moritz-Arndt-University Greifswald, Ferdinand-Sauerbruch-Str 1, 17487 Greifswald, Germany; e-mail: soenke.langner@uni-greifswald.de

DOI 10.3174/ajnr.A2345

ment or narrowing of the spinal canal, and vertebral fractures associated with neurologic deficits.^{1,13}

The preinterventional evaluation included medical history and clinical examination with assessment of the neurologic status, conventional radiography of the affected spinal segment in 2 planes, and a CT scan of the vertebral level for evaluation of posterior stability. If the age of the fracture was unknown or if several osteoporotic compression fractures were present on plain radiographs, additional MR imaging with fat-saturated T2-weighted imaging was performed to detect bone marrow edema as an indicator of a recent compression fracture.²

Each patient's physical status was assessed before the intervention to estimate the anesthesia risk according to the criteria of the ASA. Evaluation of pain quality and intensity was performed by using a VAS.

All interventions were performed by using a biplane angiography unit (Integris IV; Philips Healthcare, Best, the Netherlands). Kyphoplasty was bilateral transpedicular for lumbar vertebrae and transpedicular or extrapedicular for thoracic fractures. Each patient received a single IV infusion of ampicillin/sulbactam prior to the intervention. All patients were positioned prone, with the spine extended by placing supports under the thorax and the pelvis to facilitate augmentation of the collapsed vertebra.^{14,15}

Ten milliliters of lidocaine 1% was infiltrated from the skin to the periosteum of the targeted pedicle. BKP was performed by using a standard kyphoplasty kit (KyphoPak Tray; Kyphon, Sunnyvale, California) following published guidelines.⁴ In patients with a vertebral fracture of other etiology than osteoporosis, a biopsy was obtained for histologic work-up (Table).

BKP was performed with the patient under conscious sedation with IV administration of piritramide and midazolam for anesthesia and sedation in all patients. During intervention, continuous pulse oxymetry and electrocardiography and noninvasive blood pressure measurements at 5-minute intervals monitored patients. All patients were given oxygen via a facemask at a flow rate of 2 l/min. This was increased at the discretion of the interventional radiologist if it was deemed necessary. Peri-interventionally, the depth of sedation was assessed by using surrogate parameters including pain-related reactions such as movements or facial expressions and physiologic parameters such as heart rate, blood pressure, and respiratory rate. With respect to these parameters, the administration of piritramide and midazolam was adjusted as needed. The drugs were administered separately in 0.5-mg intervals, followed by a slow saline flush of 10 mL after each medication.

Monitoring was continued on the ward for 6 hours on completion of the intervention. The patient's neurologic status was assessed immediately after the intervention, at 6 hours, and the next day. On the day after the intervention, patients were asked to rate on a 5-point scale (0 = maximum pain, 5 = no pain) whether pain medication during intervention was sufficient and whether they would undergo the procedure again. Postinterventional pain was evaluated by using the VAS score, and conventional radiographs in 2 planes of the treated vertebra were obtained.

Statistical analysis was performed by using the Student *t* test and the χ^2 test. For statistical analysis, patients were divided in 2 groups by ASA criteria (ASA group I = ASA < 3; ASA group II = ASA \geq 3) and by age (age group I, <65 years; age group II, \geq 65 years). Total dose of piritramide and midazolam versus age and ASA score was analyzed by

Demographic and peri-interventional data of the patient cohort

Demographics	Data
No. of patients	133
Women	77
Men	56
Mean age (yr)	69.18 \pm 11.45 (range, 22–90)
ASA Score	
ASA 1	3 (2.3%)
ASA 2	31 (23.3%)
ASA 3	68 (51.1%)
ASA 4	31 (23.3%)
No. of vertebrae treated	162
1 VB per session	113
2 VBs per session	11
3 VBs per session	9
Time of intervention (mean min)	64.2 \pm 25.6
1 VB treated per session	57.9 \pm 24.2
2 VBs treated per session	65.6 \pm 28.8
3 VBs treated per session	70.0 \pm 24.9
Amount of piritramid (mg) (mean total)	11.8 \pm 3.98
1 VB	11.41 \pm 4.29
2 VBs	12.6 \pm 3.0
3 VBs	13.11 \pm 3.4
Amount of midazolam (mg) (mean total)	11.3 \pm 4.38
1 VB	10.8 \pm 4.4
2 VBs	11.9 \pm 3.8
3 VBs	14.0 \pm 3.9
Etiology of vertebral fracture	
Osteoporosis	86 (64.7%)
Metastasis of unknown primary	6 (4.5%)
Metastasis of known primary	22 (16.5%)
Plasmocytoma	15 (11.3%)
Lymphoma	4 (3%)

using the correlations test. The significance of the correlation coefficient *r* was calculated, and *P* \leq .05 was considered significant. We performed all statistical analysis by using Version 14 of the Statistical Package for the Social Sciences (SPSS, Chicago, Illinois).

Results

According to ASA criteria, 74.4% of patients (*n* = 99) in the cohort had a markedly increased surgical risk (ASA score, \geq 3). In these patients, BKP was performed on a total of 162 vertebrae. No more than 3 vertebral bodies were treated per session (Table). The number of vertebral levels treated per session was as follows: 1 vertebral level in 85% of cases (*n* = 113), 2 in 8.3% (*n* = 11), and 3 vertebrae in 6.8% of patients (*n* = 9). The underlying cause of vertebral fractures was osteoporosis in 64.7% (*n* = 86), metastases of known primary in 16.5% (*n* = 22), metastases of unknown primary in 4.5% (*n* = 6), plasmocytoma in 11.3% (*n* = 15), and lymphoma in 3% (*n* = 4).

The average duration of all interventions was 64.2 \pm 25.6 minutes. The mean duration by number of vertebrae treated per intervention was 57.9 \pm 24.2 minutes, 79.58 \pm 28.8 minutes, and 70.0 \pm 24.9 minutes for 1, 2, and 3 vertebral bodies, respectively.

Two interventions had to be discontinued (1.89%). One patient had a concomitant clavicular fracture, which precluded prone positioning; in the other case, no adequate anesthesia and sedation were achieved, and the attempt was aborted following local anesthesia. This was related to analgesic abuse, which was discovered afterward.

The mean amounts of piritramide and midazolam admin-

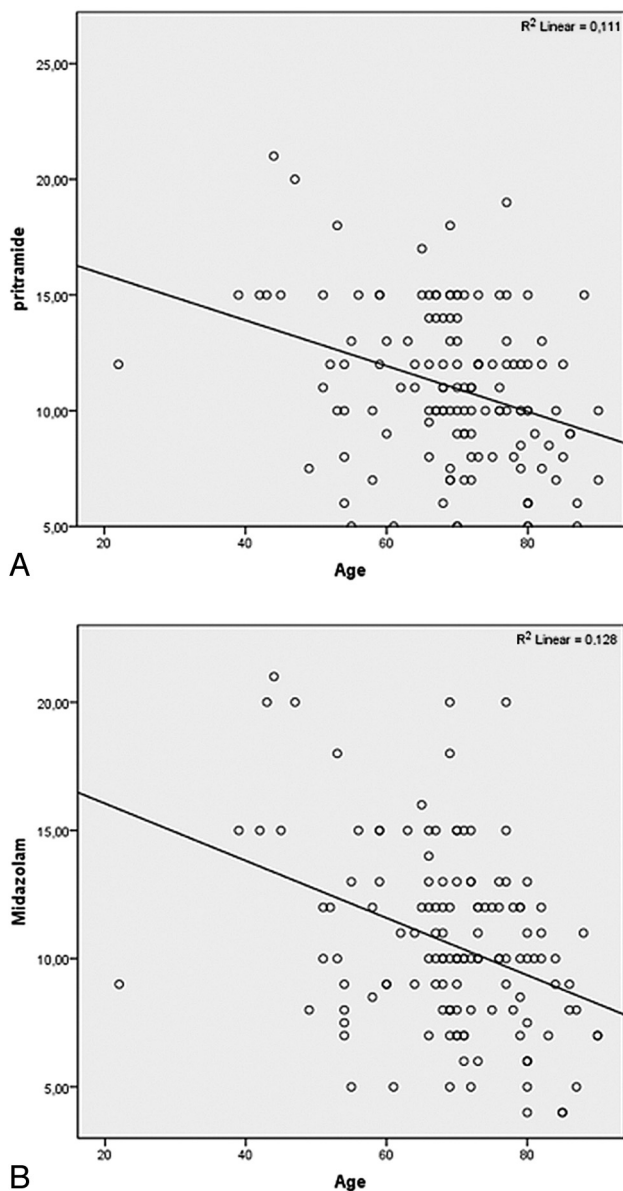


Fig 1. A, Mean amount of piritramide for anesthesia during conscious sedation. The x-axis represents the age (years); the y-axis, the amount of piritramide (milligrams) used. The correlation was significant ($r = -0.334$, $P = .01$). B, Mean amount of midazolam for conscious sedation. The x-axis represents the age (years); the y-axis, the amount of midazolam (milligrams) used. The correlation was significant ($r = -0.358$, $P = .01$).

istered per patient were 11.8 ± 3.98 and 11.3 ± 4.38 mg, respectively. The amounts required according to the number of vertebrae treated were the following: 11.41 ± 4.29 mg of piritramide and 10.8 ± 4.4 mg of midazolam for 1 vertebra, 12.6 ± 3.0 and 11.9 ± 3.8 mg for 2, and 13.11 ± 3.4 and 14.0 ± 3.9 mg for 3 vertebrae. Demographic and peri-interventional details are provided in the Table. There was a significant correlation between age and the mean amount of piritramide ($r = -0.334$, $P = .01$; Fig 1A) and midazolam ($r = -0.358$, $P = .01$; Fig 1B). However, the difference for the mean amount of midazolam and piritramide was not significant for both age groups ($P = .63$). A significant correlation for ASA score was not observed either for piritramide ($r = -0.09$, $P = .29$) or for midazolam ($r = -0.04$, $P = .64$). The difference between both ASA groups with respect to the amounts of piritramide and

midazolam needed was not significant ($P = .66$). No complications related to anesthesia and sedation were observed. There was no neurologic deterioration in any of the patients after the intervention, and clinically relevant cement leakage was not observed.

The initial mean VAS score was 8.3 (median, 8; range, 7–9). On follow-up the next day, there was significant reduction, with a mean VAS score of 2.4 (median, 3; range, 1–5; $P < .05$). According to the questionnaire, all patients would undergo the procedure again and rated peri-interventional anesthesia as sufficient.

Discussion

Since it was first described for treating osteoporotic spinal compression fractures in 2001, the indication for BKP has expanded considerably, now also including traumatic and pathologic fractures as well as spinal metastasis, with the risk of vertebral fracture or lesions associated with multiple myeloma^{1,3} leading to an increased number of procedures every year.

Despite 2 recent reports,^{16,17} the rapid pain relief afforded by both VP and BKP has been confirmed in numerous studies,¹⁸ and this effect is attributed to the immobilization of the fracture fragments by the injected cement.^{4,9,19} Published data suggest that the 2 interventional techniques are equally effective in terms of pain relief and patient mobility.^{4,20} However, several studies indicate that BKP has a lower risk of clinically relevant cement leakage.^{21–23}

Our study demonstrates that BKP with the patient under conscious sedation by using piritramide and midazolam is a safe and feasible method, particularly with regard to patients with increased risk for general anesthesia. Therefore, BKP becomes a true minimally invasive percutaneous treatment procedure like VP.

Unlike VP, most investigators prefer to perform BKP with the patient under general anesthesia because of the pain associated with balloon inflation and the longer duration of the intervention compared with VP.^{6,22,24} There are numerous reports in the literature about pain management during VP, ranging from local infiltration anesthesia to general anesthesia in the operating room.^{24,25} Hierholzer et al³ initially performed VP by using general anesthesia. On the basis of their experience, they then used IV neuroleptanalgesia within the course of the procedure. They stated that this technique is less stressful and demanding. One limitation of their study is that the authors do not mention the medication used within the course of the procedure.

The use of midazolam for conscious sedation is well-established in interventional radiologic procedures.^{26,27} The use of higher amounts carries the risk of apnea,²⁸ which can be specifically treated with flumazenil.^{26,28} In our study, we therefore titrated midazolam with respect to the surrogate parameters for the depth of sedation. The overall mean amount of midazolam was 11.3 ± 4.38 mg, which is slightly above the amounts reported in the literature for VP.^{3,27} This might be related to the pain associated with the inflation of the balloons.^{22,24} In a recent study, a protocol of titrated conscious sedation with fentanyl and propofol and monitoring of vital parameters with good tolerance for the method has been described.¹⁰ Propofol has to be applied by continuous infusion; and compared with

midazolam, it is not anxiolytic. On the other hand, propofol carries a risk for upper airway collapse and also relevant respiratory depression.²⁴

Piritramide is also well-established in radiologic interventional procedures.^{26,27} The amounts used for BKP in our study are within the range reported in the literature for VP.²⁷ An advantage of conscious sedation with piritramide and midazolam is the presence of flumazenil and naloxone as antagonists for benzodiazepines and opioids, respectively. However, resuscitation procedures or medical antagonization were not necessary in our patient cohort. With this medication, conscious sedation and anesthesia were rated as sufficient by all patients (mean postinterventional score, 4.7; range, 4–5), and all patients would undergo the procedure again.

Using a biplane angiography unit, we achieved an average intervention time for a single vertebral body of 57.9 ± 24.2 minutes. This is in concordance with the results reported in other studies. In a prospective study, Wilhelm et al²⁹ reported an average room time of 63 minutes for single-level BKP with the patient under general anesthesia in a similar study population. In our opinion, biplane fluoroscopy significantly contributed to the reduced intervention time, because planning of the access path and introduction of the working cannula and the balloons are significantly improved compared with single-plane fluoroscopy often used in the operating room. In addition, the intervention time mentioned by Wilhelm et al did not include the time required for introduction and reversal of anesthesia. This extra time is not needed when BKP is performed with the patient under conscious sedation.

Complications of BKP are related to leakage into the spinal canal or other related structures and are not usually clinically relevant.^{30–32} Severe complications, such as infections, neural damage, or pulmonary embolism are extremely uncommon.³³ For technical reasons, inadvertent cement leakage is more common in VP compared with kyphoplasty.²¹ This is supported by the results of our study. We observed no clinically relevant leakage in a study population comparable with the series published in the literature in terms of age, sex, and location of the affected vertebra.^{21,34}

Our study has a few limitations that should be mentioned. First, long-term results of pain reduction and vertebral height restoration are lacking. However, the aim of our study was to evaluate the clinical feasibility of BKP with the patient under conscious sedation by using piritramide and midazolam. Therefore, no patient was followed up for >1 year, and we did not obtain data of height restoration of the treated VBs or reduction of kyphosis. Second, the number of patients in whom 2 or 3 VBs were treated is relatively small for the evaluation of statistical differences regarding intervention times and analgesic and sedative requirements for multilevel BKP. In addition, the study population was heterogeneous in terms of fracture cause. While this heterogeneity may impair comparability between the groups, it may, on the other hand, reflect the patient population likely to be candidates for BKP in the clinical setting and is shared by other recent studies.^{3,8,21,34}

Conclusions

BKP with conscious sedation by using piritramide and midazolam is a safe and feasible method for minimally invasive

treatment of metastatic and osteoporotic vertebral fractures in patients with increased anesthesia risk.

References

- Garfin SR, Yuan HA, Reiley MA. New technologies in spine: kyphoplasty and vertebroplasty for the treatment of painful osteoporotic compression fractures. *Spine (Phila Pa 1976)* 2001; 26:1511–15
- Georgy BA. Metastatic spinal lesions: state-of-the-art treatment options and future trends. *AJNR Am J Neuroradiol* 2008;29:1605–11
- Hierholzer J, Depriester C, Fuchs H, et al. Percutaneous vertebroplasty [in German]. *Rofo* 2002;174:328–34
- Jensen ME, McGraw JK, Cardella JF, et al. Position statement on percutaneous vertebral augmentation: a consensus statement developed by the American Society of Interventional and Therapeutic Neuroradiology, Society of Interventional Radiology, American Association of Neurological Surgeons/Congress of Neurological Surgeons, and American Society of Spine Radiology. *AJNR Am J Neuroradiol* 2007;28:1439–43
- Heini PF, Walchli B, Berlemann U. Percutaneous transpedicular vertebroplasty with PMMA: operative technique and early results—a prospective study for the treatment of osteoporotic compression fractures. *Eur Spine J* 2000;9:445–50
- Kobayashi K, Shimoyama K, Nakamura K, et al. Percutaneous vertebroplasty immediately relieves pain of osteoporotic vertebral compression fractures and prevents prolonged immobilization of patients. *Eur Radiol* 2005;15:360–67
- Berlemann U, Franz T, Orlor R, et al. Kyphoplasty for treatment of osteoporotic vertebral fractures: a prospective non-randomized study. *Eur Spine J* 2004;13:496–501
- Kasperk C, Noldge G, Grafe I, et al. Indications and results of kypho- and vertebroplasty [in German]. *Internist (Berl)* 2008;49:1206, 8–10, 12–18
- Lieberman IH, Dudeney S, Reinhardt MK, et al. Initial outcome and efficacy of “kyphoplasty” in the treatment of painful osteoporotic vertebral compression fractures. *Spine (Phila Pa 1976)* 2001;26:1631–38
- Della Puppa A, Andreola C, Frass M. Assisted sedation: a safe and easy method for pain-free percutaneous vertebroplasty. *Minerva Anestesiol* 2008;74:57–62
- Voormolen MH, Mali WP, Lohle PN, et al. Percutaneous vertebroplasty compared with optimal pain medication treatment: short-term clinical outcome of patients with subacute or chronic painful osteoporotic vertebral compression fractures—the VERTOS study. *AJNR Am J Neuroradiol* 2007;28:555–60
- Magerl F, Aebi M, Gertzbein SD, et al. A comprehensive classification of thoracic and lumbar injuries. *Eur Spine J* 1994;3:184–201
- Klimo P Jr, Schmidt MH. Surgical management of spinal metastases. *Oncologist* 2004;9:188–96
- Hiwatashi A, Moritani T, Numaguchi Y, et al. Increase in vertebral body height after vertebroplasty. *AJNR Am J Neuroradiol* 2003;24:185–89
- Teng MM, Wei CJ, Wei LC, et al. Kyphosis correction and height restoration effects of percutaneous vertebroplasty. *AJNR Am J Neuroradiol* 2003;24:1893–900
- Buchbinder R, Osborne RH, Ebeling PR, et al. A randomized trial of vertebroplasty for painful osteoporotic vertebral fractures. *N Engl J Med* 2009;361:557–68
- Kallmes DF, Comstock BA, Heagerty PJ, et al. A randomized trial of vertebroplasty for osteoporotic spinal fractures. *N Engl J Med* 2009;361:569–79
- Baerlocher MO, Munk PL, Liu DM, et al. Clinical utility of vertebroplasty: need for better evidence. *Radiology* 2010;255:669–74
- Santiago FR, Abela AP, Alvarez LG, et al. Pain and functional outcome after vertebroplasty and kyphoplasty: a comparative study. *Eur J Radiol* 2010;75:e108–13. Epub 2010 Feb 6
- Schulte BU, Brucher D, Trompeter M, et al. Balloon-assisted percutaneous vertebroplasty in patients with osteoporotic vertebral body compression fractures: first results [in German]. *Rofo* 2006;178:207–13
- Eck JC, Nachtigall D, Humphreys SC, et al. Comparison of vertebroplasty and balloon kyphoplasty for treatment of vertebral compression fractures: a meta-analysis of the literature. *Spine J* 2008;18:488–97
- Heini PF, Orlor R. Kyphoplasty for treatment of osteoporotic vertebral fractures. *Eur Spine J* 2004;13:184–92
- Hulme PA, Krebs J, Ferguson SJ, et al. Vertebroplasty and kyphoplasty: a systematic review of 69 clinical studies. *Spine (Phila Pa 1976)* 2006;31:1983–2001
- Luginbuhl M. Percutaneous vertebroplasty, kyphoplasty and lordoplasty: implications for the anesthesiologist. *Curr Opin Anaesthesiol* 2008;21:504–13
- Vennmans A, Klazen CA, Lohle PN, et al. Percutaneous vertebroplasty and procedural pain. *AJNR Am J Neuroradiol* 2010;31:1830–31
- Linsenmaier U, Wagner P, Pfeifer KJ, et al. Sedation analgesia in interventional radiology [in German]. *Rofo* 2002;174:208–15
- Pitton MB, Drees P, Schneider J, et al. Evaluation of percutaneous vertebroplasty in osteoporotic vertebral fractures using a combination of CT fluoroscopy and conventional lateral fluoroscopy [in German]. *Rofo* 2004;176:1005–12

28. Reves JG, Fragen RJ, Vinik HR, et al. **Midazolam: pharmacology and uses.** *Anesthesiology* 1985;62:310–24
29. Wilhelm K, Stoffel M, Ringel F, et al. **Preliminary experience with balloon kyphoplasty for the treatment of painful osteoporotic compression fractures** [in German]. *Rofo* 2003;175:1690–96
30. Jensen ME, Dion JE. **Percutaneous vertebroplasty in the treatment of osteoporotic compression fractures.** *Neuroimaging Clin N Am* 2000;10:547–68
31. Levine SA, Perin LA, Hayes D, et al. **An evidence-based evaluation of percutaneous vertebroplasty.** *Manag Care* 2000;9:56–60, 63
32. Yeom JS, Kim WJ, Choy WS, et al. **Leakage of cement in percutaneous transpedicular vertebroplasty for painful osteoporotic compression fractures.** *J Bone Joint Surg Br* 2003;85:83–89
33. Jang JS, Lee SH, Jung SK. **Pulmonary embolism of polymethylmethacrylate after percutaneous vertebroplasty: a report of three cases.** *Spine (Phila Pa 1976)* 2002;27:E416–18
34. Hillmeier J, Meeder PJ, Noldge G, et al. **Balloon kyphoplasty of vertebral compression fractures with a new calcium phosphate cement** [in German]. *Orthopade* 2004;33:31–39