



**Providing Choice & Value**  
Generic CT and MRI Contrast Agents

**FRESENIUS  
KABI**

CONTACT REP

**AJNR**

## **Neuroradiology without Benefit of Computers: A Memoir**

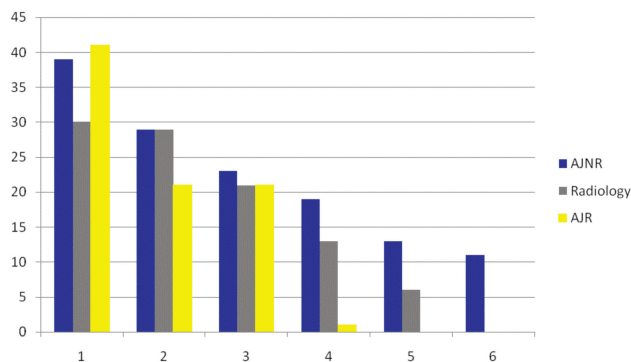
M.S. Huckman

*AJNR Am J Neuroradiol* 2010, 31 (5) 784-786

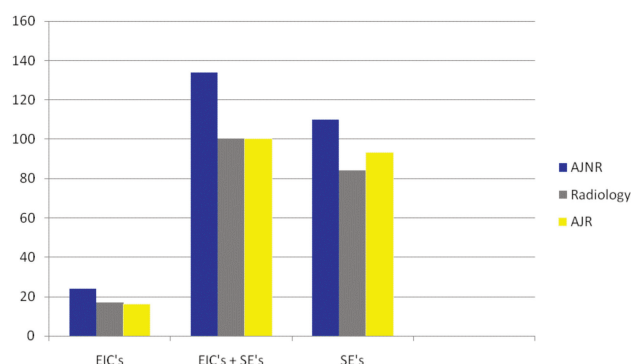
doi: <https://doi.org/10.3174/ajnr.A1935>

<http://www.ajnr.org/content/31/5/784>

This information is current as  
of July 23, 2025.



**Fig 1.** H-indices of individual Senior Editors by Journal by using Publish or Perish. Blue = AJNR, Gray = Radiology, Yellow = AJR



**Fig 2.** H-indices of individual Senior Editors by Journal by using Web of Knowledge. Blue = AJNR, Gray = Radiology, Yellow = AJR

be higher for older individuals, it was not surprising that the highest scores were for the more senior of the editors.

Needless to say, I was gratified to find out how well *AJNR* did when compared with such respected journals as *AJR* and *Radiology*. Our contributors and readers can rest assured that *AJNR*'s contents are being handled by the most qualified neuroradiologists.

## Acknowledgments

I thank Dr. H. Y. Kressel who pointed out some mistakes in my initial calculations that lead to re-writing of this commentary.

## References

1. <http://apps.isiknowledge.com>. Accessed November 23, 2009
2. Hirsch JE. An index to quantify an individual's scientific research output. *Proc Natl Acad Sci U S A* 2005;102:16569–72
3. Lee J, Kraus KL, Couldwell WT. Use of the h-index in neurosurgery. *J Neurosurg* 2009;111:387–92
4. <http://en.wikipedia.org/wiki/H-index>. Accessed on August 17, 2009
5. Egghe L. Theory and practice of the g-index. *Scientometrics* 2006;69:131–52
6. Zhang CT. The e-index, complementing the h-index for excess citations. *PLoS One* 2009;4:e5429
7. Sidiropoulos A, Katsaros D, Manolopoulos Y. Generalized h-index for disclosing latent facts in citations networks. arXiv:cs/0607066v1, 13 July 2006
8. BiHui J, LiMing L, Rousseau R, Egghe L. The R- and AR-indices: complementing the h-index. *Chinese Sci Bul* 2007;52:855–63
9. [www.harzing.com/pop/htm](http://www.harzing.com/pop/htm). Accessed November 23, 2009

M. Castillo  
Editor-in-Chief

DOI 10.3174/ajnr.A1888

## EDITORIAL

# Neuroradiology without Benefit of Computers: A Memoir

At 73 years of age, I feel fortunate still to be engaged in the full-time practice of neuroradiology, quite a different discipline today from the one for which I was trained. As one of the few remaining members of our specialty who trained in the pre-CT era (before August 1973), I thought I might share with those who have come later some reminiscences about what we did in our fellowships and practices before the “cross-sectional revolution.”

Following a rotating internship, a 2-year interval for active duty as a general medical officer in the US Navy, and a 3-year residency in general radiology (therapy and diagnosis) at the “late” Philadelphia General Hospital (PGH), I followed in the footsteps of 4 previous PGH residents, Freddie Gargano, Bassett Kilgore, E. Ralph Heinz, and Irvin Kricheff, in opting for a fellowship in neuroradiology with the late Juan Taveras,<sup>1</sup> a seminal figure in the history of neuroradiology. Whereas my 4 predecessors had taken their fellowships with him at the Neurologic Institute of New York at Columbia-Presbyterian Medical Center, Taveras had left in 1965 to become Chair of Radiology at the Mallinckrodt Institute of Radiology of Washington University Medical Center in St. Louis, where he established a neuroradiology fellowship program.

I arranged to fly out to St. Louis for an interview and, needless to say, was impressed with the personal attention I received from Dr. Taveras. I was surprised to learn that the program was a 2-year commitment and that I would be expected to do procedures such as arteriography, not just interpret them. In the 1960s at PGH, arteriograms were done by residents on clinical services with little or no supervision and had more morbidity than I would have wanted to be associated with. I returned to Philadelphia that night, and the next day my chief called Taveras, who told him that he would accept me as a fellow the following year (there was no matching program for fellowships at that time).

A few days later, I received an acceptance letter telling me to apply to the National Institute of Neurologic Diseases and Blindness for a “Special Fellowship in Neuroradiology” and to tell them that I had already been accepted by Dr. Taveras, which would guarantee that it would be awarded to me. This fellowship provided me with an annual pretax salary of \$12,000, out of which I was supposed to live, pay taxes, and move my family to St. Louis. I was fortunate to have a supplement of \$360 per month from the G.I. Bill, and by some miracle, my family managed to live a normal life. Moonlighting was only permitted when we were on vacation.

There were basically 3 rotations in the program: 1) arteriography, 2) pneumoencephalography and Pantopaque myelography, and 3) supervision of resident readings of plain skull, spine, and head and neck studies, including monitoring of hypocyloidal tomography. In the second year, fellows were periodically assigned to do arteriography at St. Louis City Hospital, where we supervised a senior resident.

One afternoon a week, I would go to the library and skim current issues of journals, jotting down the titles and authors of interesting articles to write postcards for reprints. There was no

Internet in those days. The textbooks we had available included Taveras and Wood,<sup>2</sup> Wilson,<sup>3</sup> Di Chiro,<sup>4</sup> and Robertson<sup>5</sup> and some of the more ancient texts like Davidoff and Dyke.<sup>6</sup> Immediately after my fellowship, there were excellent textbooks by Newton and Potts<sup>7</sup> and Peterson and Kieffer.<sup>8</sup>

In 1968, Taveras believed that the safest route for cerebral angiography was the direct carotid puncture and brachial “blow-back.” However, we began to get word that transfemoral catheter cerebral angiography was feasible and becoming de rigueur in some of the prominent programs, such as those of Hans Newton at the University of California, San Francisco and Bill Hanafey at the University of California, Los Angeles. There were no good commercial manufacturers of shaped catheters, and catheter materials were suspect. Early users of the “West Coast Offense” shaped and tapered their own catheters over the steam from a teakettle.

Learning carotid angiography was a “3 and out” process. The novice was given 3 tries before control of the procedure was seized by a senior fellow or attending. The novice then resumed control after the needle was placed and secured, connecting it to the injector, flushing the interconnecting tubing intermittently, and suffering the ignominy of 10 minutes of manual compression when the procedure was completed. Arteriography was performed for extracranial carotid artery disease and any intracranial mass from glioblastoma to abscess to basal ganglionic hemorrhage and pituitary and cerebellopontine angle masses. Radiologic diagnosis of pituitary microadenomas was unheard of in those days. Pituitary tumors were suspected by a large sella on plain films, and acoustic schwannoma was suspected by a large internal auditory canal seen on plain films and tomograms. If the latter tumors were big enough, there were patterns of vessel displacement to map their extent by arteriography.

Arteriography was the only way to diagnose a subdural or epidural hematoma, and the work-up for subarachnoid hemorrhage could last hours because each vessel required anteroposterior, lateral, and oblique views and each run had to be processed in the darkroom and viewed before proceeding with the next series. Tumor “blushes” were a godsend because they usually told us where a mass was and its degree of malignancy. The avascular mass was the real challenge because it could be anything from hemorrhage to abscess to malignancy, and the location of the mass was determined by inference from the shifts of various arteries and veins from their normal positions. In the supratentorial compartment, it was important to recognize and know the significance of a round, square, or distal arterial shift. These were comparatively easy to understand compared with the “minefield” of the posterior fossa, where much of the diagnostic information depended on shifts of miniscule veins and branches of cerebellar arteries.

Selective angiography only went as far as the internal or external carotid artery. Cerebral blood flow studies were done for research purposes, and at Mallinckrodt, following diagnostic angiography, we would often take the patient with an indwelling catheter or needle in the carotid artery from the third to the ninth floor, where there was an isotope scanner. Mike Ter-Pogossian would produce short half-life oxygen-15 in his basement cyclotron and shoot it to the ninth floor through a pneumatic tube, where we would immediately inject it into the carotid artery and scan the patient.

Interventional neuroradiology was in its infancy, and there

were more accidental than intentional embolizations. The first attempts used such crude materials as steel balls to occlude arteriovenous malformations.<sup>9</sup> I might add that the era was before investigational review boards.

Pneumoencephalography was a frequently used tool to visualize the ventricles and subarachnoid space. First described by the neurosurgeon Walter Dandy,<sup>10</sup> air was insufflated into the subarachnoid space and multiple views of the head were obtained, taking advantage of the antigravity movement of air throughout the ventricular system and subarachnoid space. By the time I was in fellowship, gargantuan apparatuses<sup>11</sup> had been developed for conducting this examination, a procedure which some described as the ultimate example of “man’s inhumanity to man.” The basic design of the unit was an x-ray tube mounted opposite an image amplifier. Between the 2 was a chair with lap and chest belts to secure the patient during rotation. The chair was mounted on a radial arm that rotated through 180° or 360° (depending on design) with the patient’s head always positioned in the center of the beam. The fancier units had fluoroscopic, filming, and tomographic capability. The air was positioned by rotating and swiveling the chair. The patient would undergo lumbar puncture through an opening in the back of the chair. Air would then be injected and rise to the fourth ventricle. So far, so good. However, when the patient was put into a semisupine position, air would rise anterior to the brain stem producing an excruciating “symphonic” headache. At this point, morphine could be administered, which frequently complicated matters by causing vomiting. Certain maneuvers were used to position the air. To fill the temporal horns, we rotated the patient through a forward somersault to a brow-up position, or to refill the fourth ventricle, the chair would take them through a backward somersault to the “prayer” position. Those of us who witnessed these procedures are still plagued by vivid memories of a patient strapped in a chair, hanging upside down at the top of a small Ferris wheel, with headache and emesis. To our regret, it was the only way to directly view the ventricles.

Finally there was Pantopaque myelography. Pantopaque was an oily substance, hyperbaric to CSF, which moved with gravity. The procedure was performed on a tilting fluoroscopic table. Lumbar myelography was a “piece of cake.” Cervical myelography was a bit hazardous. In the latter instance, if the patient was unable to keep the neck extended with the table head-dependent, the contrast would flow “over the hump” into the cerebral subarachnoid space where it might linger forever. Attorneys would often refer to images of the brain filled with Pantopaque as *res ipse loquitur* (the thing speaks for itself). The worst part of the procedure was removing the Pantopaque at the end. It had to be pooled under the fluoroscope by gravity as a single globule and then aspirated through the lumbar puncture needle. Sometimes it was not a problem, but often the negative pressure applied to the needle would manage to suck up a nerve root. The patient usually informed you of this with an unceremonious howl. Pantopaque left behind could become an irritant, causing arachnoiditis, especially if there was also blood in the spinal fluid, and this happening was a frequent cause of litigation. More time was spent removing the last drop of Pantopaque than the first 99%.

Late each day, Taveras or David Davis, Neuroradiology Section Director, would preview the procedural cases, after which the fellows would do the dictations. Preview was held, usually around 5:00 PM in a large reading room with all members of the

service and occasional clinicians and visiting observers in attendance. The reading room had several multicase mechanical viewers. Angiograms were acquired on roll-film changers, processed, cut, and mounted sequentially by an employee dedicated to that task. All lateral views were mounted with the patient facing the viewer's left. Preinjection film was obtained at the start of each angiographic run and was used for subtractions done on the electronic subtractor, which sat in the reading room.

In 1970, I entered the practice of neuroradiology. My hospital invested \$1.3 million to build and equip a neuroradiology suite with "state-of-the-art" pneumoencephalography, arteriography, myelography, and hypocycloidal tomography equipment. Little did any of us know that 3 years later, the advent of CT would make most of the equipment obsolete. Academic efforts, such as the anatomically detailed articles of Huang and Wolf,<sup>12</sup> describing the angiographic anatomy and shifts of the veins of the posterior fossa and striking terror in the hearts of candidates for the American Board of Radiology examination, were suddenly of no practical value. *Sic transit gloriā!* However, some of these would later rise to the surface in the age of modern interventional neuroradiology. The development of nonionic contrast media and digital subtraction angiography would also change the way we did angiography and myelography. It was fortunate that neuroradiologists were well versed in human anatomy because that was about the only thing that did not change, even to the current day.

As I look back today, it is not surprising that MR imaging and multidetector CT make what we did in the pre-CT era seem draconian. However, I suspect that 20 or 30 years from now, someone looking back will exclaim: "You mean they put those patients in those huge claustrophobic tubes with the ear-shattering noise

for 30 minutes. All we have to do now is have the patient touch the cell phone to his or her forehead for 10 seconds to obtain instant images and a printed diagnosis on our own cell phone. And to think they didn't even get the associated psychiatric profile and IQ. It must have been barbaric!"

## References

1. Huckman MS. **In Memoriam: Juan Manuel Taveras, 1919–2002.** *AJNR Am J Neuroradiol* 2002;23:1065–68
2. Taveras JM, Wood EH. *Diagnostic Neuroradiology*. Baltimore: Lippincott Williams & Wilkins; 1964
3. Wilson M. *The Anatomical Foundation of Neuroradiology of the Brain*. Boston: Little Brown and Company; 1963
4. Di Chiro G. *An Atlas of Pathologic Pneumoencephalographic Anatomy*. Springfield, Illinois: Charles C Thomas Publisher; 1967
5. Robertson EG. *Pneumoencephalography*. Springfield, Illinois: Charles C Thomas Publisher; 1957
6. Davidoff LM, Dyke CG. *The Normal Encephalogram*. Philadelphia: Lea and Febiger; 1946
7. Newton TH, Potts DG eds. *Radiology of the Skull and Brain*. St. Louis: C.V. Mosby Company; 1971
8. Peterson HO, Kieffer SA. *Introduction to Neuroradiology*. New York: Harper & Row Publishers Inc; 1972
9. Luessenhop AJ, Spence WI. **Artificial embolization of cerebral arteries: report of use in a case of arteriovenous malformation.** *JAMA* 1960;172:1153–55
10. Dandy WE. **Ventriculography following injection of air into the cerebral ventricles.** *Ann Surg* 1918;68:5–11
11. Potts DG. **A new universal head unit.** *AJR Am J Roentgenol* 1965;95:957–61
12. Huang YP, Wolf BS. **The veins of the posterior fossa-superior Galenic draining group.** *Am J Roentgenol Radium Ther Nucl Med* 1965;95:808–21

M.S. Huckman

Department of Diagnostic Radiology and Nuclear Medicine  
Rush University Medical Center  
Chicago, Illinois

DOI 10.3174/ajnr.A1935