



## Discover Generics

Cost-Effective CT & MRI Contrast Agents



FRESENIUS  
KABI

WATCH VIDEO

# AJNR

## EXPERT ddx Brain and Spine

*AJNR Am J Neuroradiol* 2010, 31 (1) R7

doi: <https://doi.org/10.3174/ajnr.A1838>

<http://www.ajnr.org/content/31/1/R7>

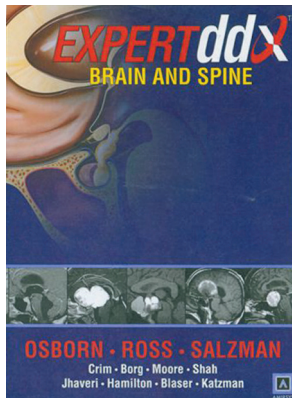
This information is current as  
of June 14, 2025.

## EXPERT ddx Brain and Spine

A. Osborn, J. Ross, K. Salzman, J. Crim, B. Borg, K. Moore, L. Shah, M. Jhaveri, B. Hamilton, S. Blaser, and G. Katzman., eds. Amirsys; 2009, 1000 pages, 3300 illustrations, \$329.00.

In a completion of the neuroradiology *EXPERT ddx* set, the volume on brain and spine (in addition to the previously reviewed volume on head and neck), is now available. As in the *EXPERT ddx Head and Neck*, the layout and concept are exactly the same. Specifically, rather than deal with categories of diseases as is the common way books are written, the volume deals with the presenting appearance on MR imaging and CT scans and proceeds from there to show images with those findings along with bullet-point information (Differential Diagnosis, Essential Information). From a daily clinical radiology standpoint, this volume is most useful and practical.

There are 18 contributors of cases, with Drs. Osborn, Ross, and Salzman serving as the prime editors of the book. There are 2 parts (Part I—Skull and Brain; Part II—Spine). As appropriate to each section, the individual areas are divided further: 1) anatomic-based differentials, 2) generic imaging patterns, 3) clinically based differentials, and 4) technique-specific imaging findings. This makes sense because the radiologist can quickly look up what may be a question or a troubling issue when reviewing images. Under Skull and Brain, the authors divide the material into scalp/skull, meninges, ventri-



cles/periventricular, extra-axial spaces/subarachnoid cisterns, brain parenchyma, supratentorial brain, infratentorial brain, sella/juxtaseilar/pineal, arteries, and veins/venous sinuses. Under Spine, the authors divide the material into trans-spinal, craniovertebral junction, vertebral body and posterior elements, intervertebral disk and endplate, extradural, intradural, extramedullary, and intramedullary.

So how would you, the neuroradiologist, go about using this book? To illustrate, if you were to note disk space irregularities and endplate changes with a signal intensity abnormality, but the patient has no clinical sign of a diskitis-osteitis, you could find examples of other possibilities in the differential diagnosis with a similar pattern. Scenarios such as this abound throughout the book. On the other hand, when confronted with a clinical history such as macrocephaly, all of the possibilities, from common through rare, are listed and shown. Perhaps if you are faced with a case of parenchymal brain calcifications, either solitary or multiples, you can look through a library of images and differential diagnoses, arriving at the most likely diagnosis for the images under consideration.

This book is not meant to be read from cover to cover—that never was the editors' intent—nor is this work intended to impart a deep understanding of each disease. Rather, it is intended to assist the radiologist through myriad imaging findings, and to that end, the book succeeds to its fullest. The innovations that Drs. Osborn and Harnsberger have brought to medical publication are truly remarkable. They have broken all of the old conventions of how to construct a medical book and present information to a radiologist. It is no overstatement that this book (and its sister volume, *Head and Neck*) should find its way onto every shelf in a department or section library, and for the individual neuroradiologist, this book is a highly recommended purchase.

DOI 10.3174/ajnr.A1838