



## Discover Generics

Cost-Effective CT & MRI Contrast Agents



WATCH VIDEO

# AJNR

## **Thunderclap Headache without Subarachnoid Hemorrhage Associated with Regrowth of Previously Coil-Occluded Aneurysms**

E.P. Byrum, J.M. McGregor and G.A. Christoforidis

This information is current as  
of June 2, 2025.

*AJNR Am J Neuroradiol* 2009, 30 (5) 1059-1061

doi: <https://doi.org/10.3174/ajnr.A1382>

<http://www.ajnr.org/content/30/5/1059>

## CASE REPORT

E.P. Byrum  
J.M. McGregor  
G.A. Christoforidis

# Thunderclap Headache without Subarachnoid Hemorrhage Associated with Regrowth of Previously Coil-Occluded Aneurysms

**SUMMARY:** Thunderclap headache is a sudden, high-intensity headache often associated with subarachnoid hemorrhage secondary to a ruptured intracerebral aneurysm. A variety of less common causes have now been described. This report presents the cases of 2 patients who experienced thunderclap headache after regrowth of an aneurysm, without hemorrhage of previously coiled aneurysms. Thunderclap headache after endovascular occlusion of a ruptured intracranial aneurysm may be a symptom of aneurysm regrowth and may warrant angiographic investigation.

Since its approval by the US Food and Drug Administration in 1995, endovascular coiling has become a popular treatment option for both ruptured and unruptured intracerebral aneurysms. Large studies have shown an early survival advantage for endovascular treatment versus neurosurgical clipping.<sup>1</sup> Concerns remain, however, regarding the long-term stability and likelihood of recurrence after endovascular treatment. Such concerns highlight the need for a greater understanding of both the pathophysiologic mechanisms and clinical manifestations of aneurysm recurrence.

The term thunderclap headache was coined in 1986 in a case report describing a patient with sudden, severe headache secondary to an unruptured cerebral aneurysm.<sup>2</sup> The diagnostic criteria have since been refined to include only those headaches with severe pain intensity, hyperacute onset (< 30 seconds), duration of 1 hour to 10 days, and absence of long-term recurrence.<sup>3</sup> Although thunderclap headache is often associated with subarachnoid hemorrhage, the differential diagnosis is actually quite broad. Other causes include cerebral venous sinus thrombosis, cervical artery dissection, pituitary apoplexy, hypertensive crisis, intracranial infection, and retroclival hematoma.<sup>4</sup> This case report describes 2 patients with a history of ruptured intracerebral aneurysm in whom thunderclap headache developed weeks to months after aneurysm occlusion with Guglielmi detachable coils (Boston Scientific, Natick, Mass). Although these patients did not experience recurrent hemorrhage, angiography revealed interval growth of the aneurysms.

## Case Reports

### Case 1

A 42-year-old woman presented with a ruptured right A1 segment internal carotid artery aneurysm (Fig 1A) that led to a subarachnoid hemorrhage. This aneurysm was completely occluded with Guglielmi detachable coils (Fig 1B). The patient was lost to follow-up; however, she presented to the emergency department 1 year later complaining

of a sudden-onset, severe headache, which she described as similar to the headache she experienced after the right A1 segment aneurysm ruptured. The headache was frontal and radiated bilaterally to the posterior aspect of her head. It was accompanied by nausea and blurry vision but no focal neurologic signs or symptoms. On physical examination, no papilledema or nuchal rigidity was noted. CSF analysis was normal. No blood was evident on CT scan.

Given the patient's history, the decision was made to perform an angiogram, which demonstrated recurrence and slight growth of the right A1 segment aneurysm (Fig 1C). The patient later underwent repeated coiling of the aneurysm.

### Case 2

A 46-year-old woman initially presented with severe bilateral frontal headache accompanied by nausea, forceful vomiting, and photophobia. She was diagnosed with subarachnoid hemorrhage from a ruptured right posterior communicating artery aneurysm (Fig 2A). The patient underwent endovascular coiling, and the aneurysm was completely occluded with Guglielmi detachable coils (Fig 2B). The patient presented 1 month later with a thunderclap headache similar to the one at presentation. The patient described 3 additional episodes of headache similar to that of her initial presentation but not as intense as the fourth episode. These headaches came on suddenly, were without warning, and were located in the right retro-orbital region. The patient otherwise complained only of nausea and questionable intermittent double vision in her right eye. No neurologic deficits were noted on examination. Lumbar puncture examination and head CT scan revealed no evidence of intracerebral hemorrhage. Subsequent angiography demonstrated recanalization and slight enlargement of the base of the right posterior communicating artery aneurysm (Fig 2C). The patient opted for repair by neurosurgical clipping. At surgery, the dome of the aneurysm was noted to abut the third cranial nerve. There was no evidence of recent hemorrhage.

## Discussion

Concerns regarding aneurysmal rebleeding have drawn much attention toward the long-term durability of endovascular coiling. The International Subarachnoid Aneurysm Trial (ISAT) showed a 0.65% risk of rebleeding within 1 year.<sup>1</sup> The risk of late rebleeding (occurring after year 1) was less (0.21%) but was still much higher than the late rebleeding rate for patients undergoing neurosurgical clipping (0.063%). It has been suggested that ISAT may not accurately represent the entirety of patients with aneurysms because most patients in the ISAT trial had anterior circulation aneurysms.<sup>5</sup> In addition, the study was terminated in 2002,

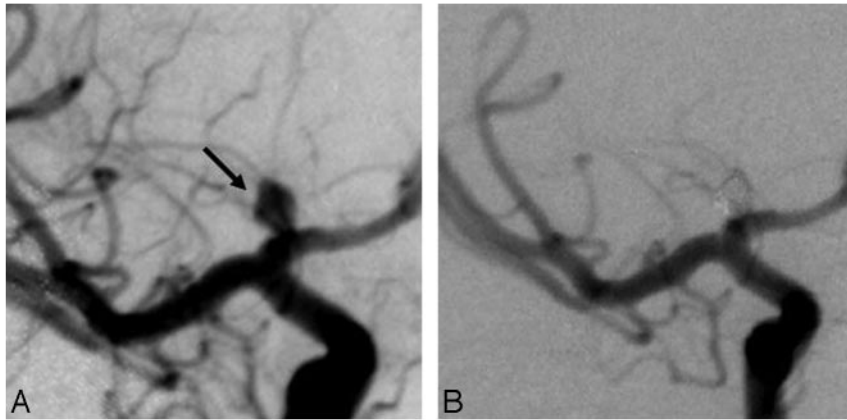
Received September 8, 2008; accepted September 19.

From Departments of Radiology (E.P.B., G.A.C.) and Neurologic Surgery (J.M.M.), Ohio State University Medical Center, Columbus, Ohio.

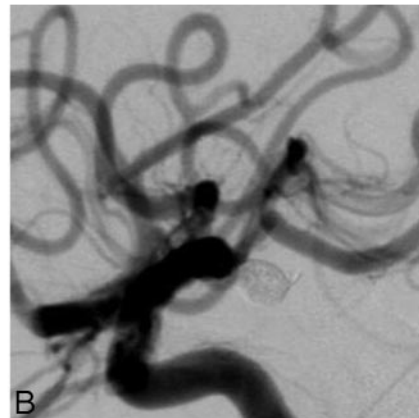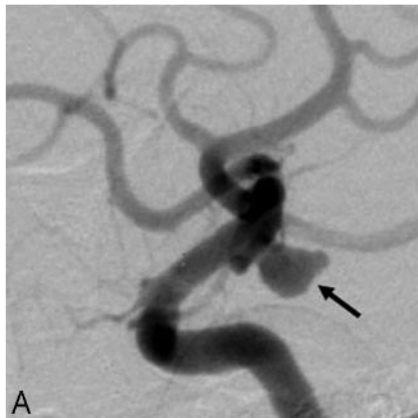
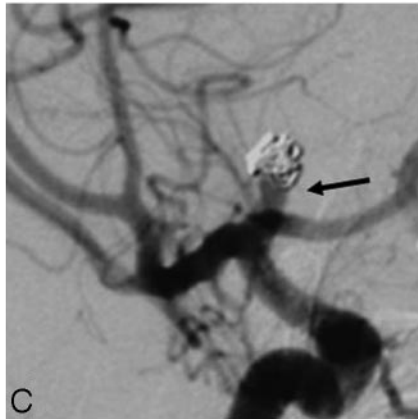
Paper previously presented at: Annual Meeting of the American Society of Neuroradiology, May 13-17, 2002; Vancouver, British Columbia, Canada.

Please address correspondence to Gregory Christoforidis, Ohio State University Medical Center, Department of Radiology, 627 Means Hall, 1654 Upham Dr, Columbus, OH 43210; e-mail: Greg.Christoforidis@osumc.edu

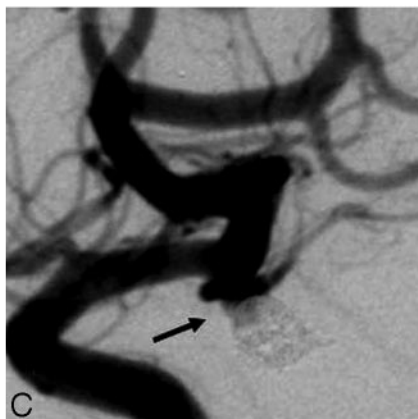DOI 10.3174/ajnr.A1382



**Fig 1.** Case 1. Right internal carotid arteriograms demonstrate a proximal A1 segment aneurysm at the time of subarachnoid hemorrhage (*arrow*, *A*) and after endovascular coil occlusion (*B*). Arteriogram performed 1 year later (*C*) after a thunderclap headache demonstrates aneurysm recurrence (*arrow*).



**Fig 2.** Case 2. Right internal carotid arteriograms demonstrate a posterior communicating artery aneurysm at the time of rupture (*arrow*, *A*) and after endovascular coiling (*B*). Arteriogram performed at the time of a thunderclap headache 1 month after coil occlusion (*C*) indicates regrowth at the aneurysm base (*arrow*).



and recent advances in endovascular treatment may further reduce the risk of rebleeding after coiling. Still, the ISAT results

suggest that the superiority of endovascular coiling versus neurosurgical clipping may be mitigated in some patient populations,

particularly in young people with longer potential exposure to the risks of rebleeding.<sup>6</sup>

Aneurysm recurrence after coiling has also been investigated. The incidence of recurrence of previously ruptured aneurysms has been reported at 20%, and 9% of aneurysms managed with endovascular occlusion required retreatment.<sup>7</sup> These findings are concerning because recurrence is a likely precursor to rebleeding. In a large study of posterior circulation aneurysms, 3 patients with recurrent subarachnoid hemorrhage had a recurrence rate of greater than 10% after coiling.<sup>8</sup>

These numbers are certainly important but leave open the question of pathophysiology. Pain from an unruptured aneurysm may result from one of several mechanisms. Small leaks of blood may cause the classic “sentinel headache” before aneurysm rupture. Alternate causes for the pain include aneurysm thrombosis and hemorrhage within the vessel wall.<sup>9</sup> Whereas cerebral vasospasm is a common complication of subarachnoid hemorrhage, sudden enlargement of an unruptured aneurysm may also trigger vasospasm, though reports clearly linking aneurysm enlargement and vasospasm are rare.<sup>10</sup>

The cases presented here are unusual in the clinical manifestation of aneurysm recurrence: thunderclap headache. This symptom should not be ignored, especially in patients with a history of endovascular coiling, even with negative CT and CSF findings. Angiography may reveal aneurysm recurrence and possibly regrowth, which increases the risk for a potentially devastating rebleed.<sup>1</sup> In addition to conventional angiography, an increased role for MR and CT angiography may be useful, given the importance of accounting for aneurysm

recurrence and growth. Clinicians and radiologists should be mindful of the potential clinical manifestations of regrowth of previously occluded aneurysms without rerupture. Even with unremarkable preliminary studies, thunderclap headache may require definitive angiographic imaging. It might be the only clinical indication of the presence of a growing aneurysm.

## References

1. Molyneux AJ, Kerr RS, Yu L, et al. **International subarachnoid aneurysm trial (ISAT) of neurosurgical clipping versus endovascular coiling in 2143 patients with ruptured intracranial aneurysms: a randomised comparison of effects on survival, dependency, seizures, rebleeding, subgroups, and aneurysm occlusion.** *Lancet* 2005;366:809–17
2. Day JW, Raskin NH. **Thunderclap headache: symptom of unruptured cerebral aneurysm.** *Lancet* 1986;2:1247–48
3. Slivka A, Philbrook B. **Clinical and angiographic features of thunderclap headache.** *Headache* 1995;35:1–6
4. Schwedt TJ, Matharu MS, Dodick DW. **Thunderclap headache.** *Lancet Neurol* 2006;5:621–31
5. Ausman J. **The International Subarachnoid Aneurysm Trial II: comparison of clipping vs coiling: key questions. Are the results of the study generalizable? Should clipping be done for patients less than 40 years of age?** *Surg Neurol* 2008;70:104–07
6. Mitchell P, Kerr R, Mendelow D, et al. **Could late rebleeding overturn the superiority of cranial aneurysm coil embolization over clip ligation seen in the International Subarachnoid Aneurysm Trial?** *J Neurosurg* 2008;108:437–42
7. Campi A, Ramzi N, Molyneux A, et al. **Retreatment of ruptured cerebral aneurysms in patients randomized by coiling or clipping in the International Subarachnoid Aneurysm Trial (ISAT).** *Stroke* 2007;38:1538–44
8. Pandey A, Koebe C, Rosenwasser R, et al. **Endovascular coil embolization of ruptured and unruptured posterior circulation aneurysms: review of a 10-year experience.** *Neurosurgery* 2007;60:626–37; discussion 636–37
9. Raps E, Rogers J, Galetta S, et al. **The clinical spectrum of unruptured intracranial aneurysms.** *Arch Neurol* 1993;50:265–68
10. Paolini S, Kanaan Y, Wagenbach A, et al. **Cerebral vasospasm in patients with unruptured intracranial aneurysms.** *Acta Neurochir* 2005;147:1181–88