



**Providing Choice & Value**  
Generic CT and MRI Contrast Agents



CONTACT REP

**AJNR**

## **EXPERT ddx Head and Neck**

H.R. Harnsberger, C.M. Glastonbury, M.A. Michel, B.L. Koch, C.D. Phillips, K. Mosier, P. Hudgins, R. Wiggins, H.C. Davidson and J. Curé

*AJNR Am J Neuroradiol* 2009, 30 (10) E156

doi: <https://doi.org/10.3174/ajnr.A1765>

<http://www.ajnr.org/content/30/10/E156>

This information is current as  
of July 28, 2025.

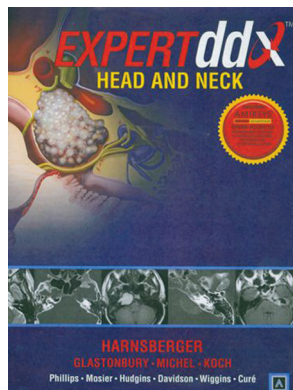
## EXPERT ddx Head and Neck

H.R. Harnsberger, C.M. Glastonbury, M.A. Michel, B.L. Koch, C.D. Phillips, K. Mosier, P. Hudgins, R. Wiggins, H.C. Davidson and J. Curé. Amirsys; 2009, 800 pages, 2500 illustrations, \$329.00.

In a variation on the highly popular *Diagnostic Imaging: Head and Neck* by Dr Harnsberger, which was written to describe and illustrate specific diseases with their differential diagnoses, this book, *Expert ddx: Head and Neck*, takes a different but probably more meaningful and useful approach to daily imaging and reporting. Here specific findings on MR imaging and CT are separated into groups or sections, within which the reader is presented with a series of images with different diagnoses but somewhat similar findings. Included within the sections is also a listing of the differential diagnosis and critical information about each of these diseases. This, of course, is exactly how one goes about reviewing images and constructing plausible diagnostic possibilities.

This remarkable (ground-breaking in concept) book has contributions from 10 well-known radiologists in head and neck imaging (Drs Harnsberger, Michel, Phillips, Hudgins, Wiggins, Glastonbury, Koch, Mosier, Davidson, and Curé), who have selected excellent cases and high-quality images. Twenty-three other radiologists listed in the front of the book allowed the use of material from their collections to be included.

The sections of the book are the following: “Suprahyoid and Infrahyoid; Oral Cavity,” “Mandible, Maxilla,” “Hypopharynx and Larynx,” “Lymph Nodes,” “Transpatial/Mullispatial Diseases,” “Sinus and Nose,” “Orbit,” “Temporal Bone,” “Skull Base,” “CPA/ICA,” “Posterior Fossa,” “Cranial Nerves,” and “Brain Stem.” Each of these sections is divided into a variety of subsections (anatomically based differentials, generic imaging patterns, clinically based differentials, technique-specific imaging findings), some of which seem a bit arbitrary. The clinically based differentials are helpful because in the minority of situations in which the radiologist actually does get a decent history, the listed clinical scenarios are commonly encountered.



A few examples will suffice to show how useful this book can be. In the temporal bone section, there is a portion entitled “Expansile-Destructive Petrous Apex Lesion,” which describes the common, uncommon, and rare entities to be considered. Each is discussed in the familiar bullet point manner (an anathema to traditionalists, but effective nonetheless), followed by 9 examples of different etiologies presenting in the same area and with similar but not identical features. This, like all other areas, is a great review of imaging and can supplement the on-line STAT Dx (<https://my.statdx.com>). As an aside, in some cases like the internal carotid artery aneurysm of the temporal bone, it would have been instructive to somehow refer the reader to the digital subtraction angiography or CT angiography confirming what is seen on axial CT/MR imaging. Similarly when one encounters a sinonasal lesion, the diagnostic possibilities are numerous—this book lays out the many lesions, allowing a comparison between what is on your PACS versus what is shown and described here. Examples of the usefulness of the book abound—one just has to thumb through it to see how it could be of ongoing help to any radiologist.

Beyond the imaging of diseases, excellent examples of variants are shown: For instance, in the section on normal skull base variants, venous channels or prominent foramina area is seen. Some of these are impressive and easily mistaken for pathology, such as a petromastoid canal simulating a fracture or large emissary veins simulating diploic lesions. Examples in other areas serve to stress variants mimicking abnormalities, but of course, the strength of the book is in the abundant image collection cataloged by region. An additional exercise of value is to simply go to a given section and study all the images, convincing yourself that the next time you see a similar lesion you will recall the differential possibilities.

As an added benefit to the purchase, the book comes with access to what Amirsys calls its “eBookAdvantage” (<http://starfields.org/ebook-advantage.htm>). With the enclosed code, one can access additional images and updated information to supplement what appears in the text. There is no question that the extensive series in diagnostic imaging broke the mold for books in radiology. Now the originators of this brilliant concept have taken another step by publishing a reference to cite specific findings. One looks forward to future *EXPERT ddx* in the brain and spine.

No departmental or sectional library should be without this series of textbooks, and I suspect that most neuroradiologists will want their own copies.

DOI 10.3174/ajnr.A1765