



## Discover Generics

Cost-Effective CT & MRI Contrast Agents



FRESENIUS  
KABI

WATCH VIDEO

# AJNR

## **The extraforaminal herniated disk: detection by computed tomography.**

G J Novetsky, L Berlin, A J Epstein, N Lobo and S H Miller

*AJNR Am J Neuroradiol* 1982, 3 (6) 653-655

<http://www.ajnr.org/content/3/6/653.citation>

This information is current as  
of June 28, 2025.

# The Extraforaminal Herniated Disk: Detection by Computed Tomography

Gary J. Novetsky<sup>1</sup>  
Leonard Berlin  
Avrum J. Epstein  
Narciso Lobo  
Sheldon H. Miller

Extraforaminal lumbar disk herniation is unusual and often undetected by myelography. Four cases were detected by high-resolution computed tomography. They were verified by surgery in one, diskography in one, and by the clinical course in two cases. Metrizamide myelography in two of the three patients was normal. This suggests that CT can accurately detect the diagnostically troublesome extraforaminal disk herniation.

Early computed tomographic (CT) equipment demonstrated only those herniated disks that were calcified [1] or that became apparent after intrathecal introduction of metrizamide [2, 3]. Soft herniated disks or other abnormalities within the spinal canal could not be shown due to lack of contrast resolution. With the introduction of high-resolution and thin-section CT, combined with digital radiography for precise positioning, the accuracy of detecting disk herniations markedly increased [4–8]. The CT findings in the typical lumbar herniation have been described [7]. We present the CT findings in the less common but often myelographically missed extraforaminal lumbar disk herniation.

## Material and Methods

Between January 1980 and December 1981, 1,808 patients had lumbar CT examinations for suspected disk herniation at Skokie Valley Computed Tomography Centre. In 394 patients, a CT diagnosis of lumbar disk herniation was made. The images in four cases were interpreted as extraforaminal lateral disk herniations. We defined extraforaminal disk herniation as a soft-tissue density predominantly beyond the intervertebral foramen, with or without a lesser extension into the foramen. Surgery, diskography, myelography, or the clinical course was used to verify this diagnosis. Review of 100 patients without evidence of a disk herniation was used as comparison.

All scans were done on a Pfizer 0450 with the patient supine. A digital radiographic lateral localizer image was used to locate the appropriate intervertebral disk space and to determine the gantry tilt needed to obtain slices through, above, and below the disk plane. Thin sections ranging from 2 to 5 mm depending on the disk height were used to lessen the partial-volume effect of adjacent vertebral bodies. Sections were also routinely taken at the upper and lower laminal levels to survey for possible disk extrusions or spinal stenosis. Technical factors included 5 sec scan time, 100 mA, 120 kV, and 0.5 mm pixel size. All scans were done without intrathecal metrizamide.

## Case Reports

### Case 1

A 37-year-old woman had low back and left leg pain without a known cause. Left straight leg raising was positive at 45°. There was weakness and atrophy of the left foot extensor muscles. Metrizamide myelography was normal. CT examination demonstrated a soft-tissue mass positioned beyond the left L5–S1 neural foramen and interpreted as an extraforaminal disk herniation (fig. 1). Surgical exploration of the spinal canal was negative, but a left

Received April 5, 1982; accepted after revision June 11, 1982.

<sup>1</sup>All authors: Department of Radiology, Skokie Valley Hospital, 9600 Gross Point Rd., Skokie, IL 60076. Address reprint requests to G. J. Novetsky.

*AJNR* 3:653–655, November/December 1982  
0195–6108/82/0306–0653 \$00.00  
© American Roentgen Ray Society



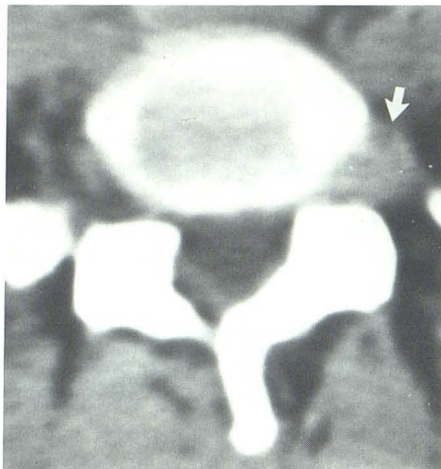


Fig. 1.—Case 1. Extraforaminal herniated L5–S1 disk. Soft-tissue mass beyond spinal canal obscures left nerve root and fat (arrow). Myelography was normal.

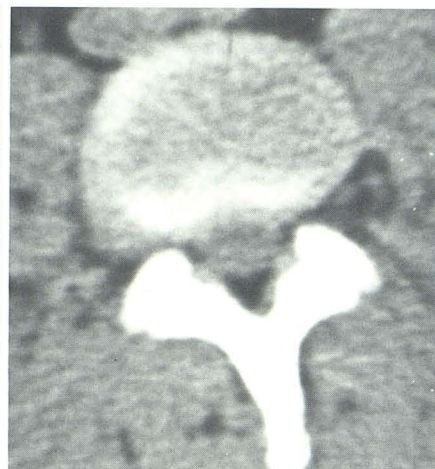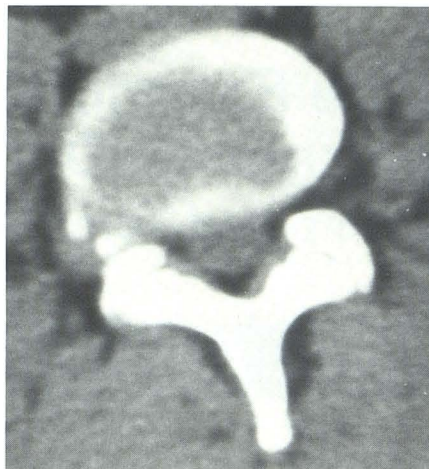


Fig. 2.—Case 2. Extraforaminal herniated L4–L5 disk (A) and L3–L4 disk (B). Soft-tissue masses are contiguous with disks. Both disk herniations are partially calcified, although L3–L4 disk calcification is more pronounced at different imaged section. Myelography was normal.

facetectomy uncovered a large extraforaminal disk herniation which was evacuated. The patient has slowly but progressively recovered muscle strength over a 3 month period.

#### Case 2

A 34-year-old man suffered an injury to the low back while lifting a heavy object. The pain radiated in a right sciatic distribution to the ankle. Straight leg raising was positive at 45°. Right foot extensor muscles were weak. Metrizamide myelography was normal. Electromyography revealed a lesion compatible with a ventral radiculopathy, probably at the right L5 level. A 2 month course of conservative treatment failed to relieve the patient's pain. CT scan showed a partially calcified extraforaminal herniated disk at the right L3–L4 and L4–L5 levels (fig. 2). Foraminotomies were done at the L3–L4 and L4–L5 levels to release the nerve roots that were found to be markedly fixed in the lateral gutter. Subsequently the patient's pain has diminished and muscle strength has improved.

#### Case 3

A 59-year-old woman developed left sciatic pain after lifting a sewing machine. Bed rest failed to relieve the pain which persisted for 9 months. Straight leg raising was positive at 75°. The left knee reflex was depressed. Lumbar CT examination showed a soft-tissue mass compatible with a left L4–L5 extraforaminal disk herniation (fig. 3). Metrizamide myelography demonstrated a left L4–L5 extradural defect. The patient underwent chemonucleolysis using purified chymopapain after diskography confirmed the presence of a L4–L5 disk herniation. Six weeks after injection, the patient experienced sudden incapacitating low back pain. A repeat lumbar CT scan revealed a new central L4–L5 disk herniation in addition to the unchanged extraforaminal disk herniation. Surgery is being contemplated.

#### Case 4

A 34-year-old man experienced low back pain after jumping. The pain progressed in a left sciatic distribution. Straight leg raising was positive at 30°. The patient refused myelography or surgery. CT scan showed a left L5–S1 extraforaminal soft-tissue mass compat-

ible with disk herniation (fig. 4). A 4 month follow-up examination revealed a persistent left foot drop and extensor muscle weakness, although the pain had lessened.

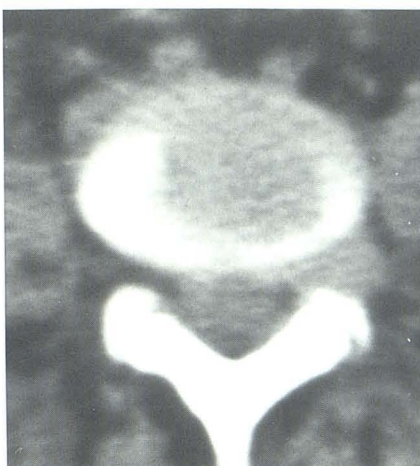#### Discussion

The cases presented all have CT-demonstrated soft-tissue masses located beyond the spinal canal and neural foramina. Two cases (three herniated disks) had partial calcification. The disk herniations obscured the usually seen extraforaminal nerve root or spinal nerve and obliterated the surrounding fat. The CT differential diagnosis of these masses is similar to the usual disk herniation that occurs within the anatomic boundaries of the spinal canal. Tumor or osteomyelitis may simulate the appearance of disk herniation [7]. Although in our cases without surgical confirmation these entities cannot be excluded, they are thought unlikely due to the patients' clinical courses. Metrizamide myelography was negative even on retrospective analysis in two of the three patients. The negative myelogram in the light of a clinically suspect disk herniation has long been a diagnostic problem.

Retrospective and prospective comparisons of iophendylate lumbar myelography and surgical findings report sensitivity for detection of disk herniation as 70%–85% [9]. Conversely, 15%–30% of patients with true disk herniations have normal myelographic studies. The most important causes of false-negative myelograms are herniated disks that (1) protrude too far laterally to affect the opaque column, (2) are fragmented and extruded into the intervertebral foramen, or (3) are associated with an unusual amount of space anterior to the dura, usually at L5–S1 [10]. Abdullah et al. [11] reported an 11.7% incidence of extreme lateral disk herniation. Recently, using CT, Williams et al. [12] reported a suspected lower incidence in the range of 5%. Our own findings suggest an incidence of 1%, however this may merely reflect the difference in CT criteria used for their "lateral" and our "extraforaminal" disk herniation. Lateral disk herniations compressing the nerve root distal to the

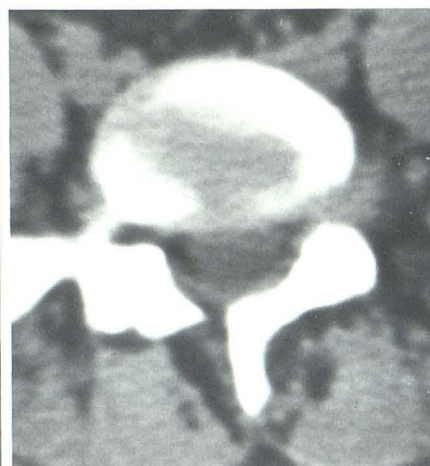

Fig. 3.—Case 3. Left-sided extraforaminal soft-tissue mass compatible with L4–L5 disk herniation. Disk herniation extends toward spinal canal, explaining why metrizamide myelogram demonstrated small extradural defect.



3

Fig. 4.—Case 4. Extraforaminal mass, compatible with left L5–S1 disk herniation. Epidural fat around thecal sac is preserved, while it is obliterated within left nerve root.



4

ganglion defy myelographic detection, because they may not come into contact with the opacified thecal column or because failure to fill an axillary sleeve may occur normally in the absence of disk disease due to the difficulty the viscous oil has entering this space [13]. With the advent of water-soluble contrast material in myelography, the latter deficiency is often eliminated since acceptable nerve root sleeve opacification is 83% compared to only 6% with iophendylate [14]. Nonetheless the few reported clinical trials of water-soluble contrast material in myelography still report an incidence of about 6% false-negative examinations [15, 16].

In summary, besides identifying the herniated disk within the spinal canal, CT can image the infrequent but diagnostically troublesome extraforaminal herniated disk. In addition, preoperative CT localization can forewarn the surgeon to the possible necessity of more extensive surgical exploration than usually expected.

#### ACKNOWLEDGMENTS

We thank Pam Behren, Jim Funk, and Marilou Weber for technical assistance, and Patricia Funk and Pam Behren for secretarial help.

#### REFERENCES

1. Lee BCP, Kazam E, Newman AD. Computed tomography of the spine and spinal cord. *Radiology* 1978;128:95–102
2. DiChiro G, Schellinger D. Computed tomography of spinal cord after lumbar intrathecal introduction of metrizamide (computer assisted myelography). *Radiology* 1976;120:101–104
3. Coin CG, Chan YS, Keranen V, et al. Computer assisted myelography in disk disease. *J Comput Assist Tomogr* 1977;1:398–404
4. Burton CV, Heithoff KB, Kirkaldy-Willis W, et al. Computed tomographic scanning and the lumbar spine. II. Clinical considerations. *Spine* 1979;4:356–368
5. Glenn WV Jr, Rhodes ML, Altschuler EM, et al. Multiplanar display computerized body tomography applications in the lumbar spine. *Spine* 1979;4:282–352
6. Meyer GA, Haughton VM, Williams AL. Diagnosis of herniated lumbar disk with computed tomography. *N Engl J Med* 1979;301:1166–1167
7. Williams AL, Haughton VM, Syvertsen A. Computed tomography in the diagnosis of herniated nucleus pulposus. *Radiology* 1980;135:95–99
8. Coin CB, Coin JT. Computed tomography of cervical disk disease: technical considerations with representative case reports. *J Comput Assist Tomogr* 1981;5:275–280
9. Huggins WR. The predictive value of myelography in the diagnosis of ruptured lumbar discs. *J Neurosurg* 1970;32:152–162
10. Shapiro R, Galloway SJ, Goodrich I. The evaluation of the patient with a negative or indeterminate myelogram. In: Post MJD, ed. *Radiographic evaluation of the spine*. New York: Masson, 1980:603–622
11. Abdullah AF, Ditto EW, Byrd EB, et al. Extreme-lateral lumbar disc herniations, clinical syndrome and special problems of diagnosis. *J Neurosurg* 1974;41:229–234
12. Williams AL, Haughton VM, Daniels DL, Thornton RS. CT Recognition of lateral lumbar disk herniation. *AJNR* 1982;3:211–213
13. Shapiro R. *Myelography*, 3d ed. Chicago: Year Book Medical, 1975:376
14. Kieffer SA, Binet EF, Esquerre JV, et al. Contrast agents for myelography: clinical and radiological evaluation of amipaque and Pantopaque. *Radiology* 1978;129:695–705
15. Spangfort EV. The lumbar disc herniation. *Acta Orthop Scand [Suppl]* 1972;142:5–95
16. Haughton VM, Eldevik OP, Magnaes B, Amundsen P. A prospective comparison of computed tomography and myelography in the diagnosis of herniated lumbar disks. *Radiology* 1982;142:103–110