



**Providing Choice & Value**

Generic CT and MRI Contrast Agents



**FRESENIUS  
KABI**

**CONTACT REP**

**AJNR**

**Percutaneous transluminal angioplasty of the  
external carotid artery: preliminary report.**

J J Vitek and R B Morawetz

*AJNR Am J Neuroradiol* 1982, 3 (5) 541-546

<http://www.ajnr.org/content/3/5/541.citation>

This information is current as  
of July 24, 2025.

# Percutaneous Transluminal Angioplasty of the External Carotid Artery: Preliminary Report

Jiri J. Vitek<sup>1</sup>  
Richard B. Morawetz<sup>2</sup>

Long-term patency of superficial temporal artery and middle cerebral artery anastomosis requires unhindered flow through the external carotid artery. Percutaneous transluminal angioplasty was used to dilate stenotic lesions at the origin of the external carotid artery in three patients. Technical points relevant to transluminal angioplasty in this artery are discussed.

Percutaneous transluminal angioplasty (PTA) using a coaxial catheter system was reported by Dotter and Judkins [1] in 1964. Ten years later in 1974, Grüntzig and Hopff [2] reported the development and successful clinical use of a double-lumen balloon catheter. The smaller diameter and flexibility of the catheter made possible more selective vessel dilatations. The balloon is of low compliance and thus can be inflated to a predetermined diameter and pressure, markedly diminishing the risk of balloon and vessel overdistension. PTA has rapidly evolved as an alternative to surgical therapy for stenotic vascular lesions. Recent reports have described the successful and extensive use of this balloon technique in the treatment of stenotic lesions of the iliac, femoral, popliteal, renal, abdominal, and coronary arteries of both atherosclerotic and nonatherosclerotic etiology [3–8]. Only a few reports describe the use of the technique on brachiocephalic vessels, such as on subclavian, carotid, and vertebral arteries [9–12, 13]. This paper describes PTA of the external carotid artery in which atherosclerotic stenoses complicated planning for superficial temporal–middle cerebral artery bypass procedures for internal carotid occlusion.

## Materials and Methods

Dilatation of the stenotic origin of the external carotid artery was performed in three men. All had complete occlusion of the ipsilateral internal carotid artery with symptoms suggesting insufficient collateral flow in the corresponding territory of the middle cerebral artery. In all patients, the stenosis was atherosclerotic and, in one of the three, an endarterectomy had been attempted. The three patients were candidates for superficial temporal artery–middle cerebral artery bypass based on clinical and radiographic criteria.

Before PTA, all patients underwent diagnostic angiography with selective catheterization of both common carotid arteries and at least one vertebral artery. The groin opposite the one used in previous angiography was always used. By means of 6.5 French polyethylene catheter, the appropriate common carotid artery was catheterized. The head was rotated to the most advantageous position (usually the opposite oblique position) to display the stenotic segment at the origin of the external carotid artery, and this level was marked with lead markers on the skin. Then, a short film series was performed to confirm the optimal position of the head and accurate placement of the radioopaque skin markers. Taking advantage of the distal curve of the polyethylene catheter, a 0.035 inch (0.89 mm) J guide wire was directed under fluoroscopy into the external carotid artery. After passing the wire through the area of stenosis, the polyethylene catheter was gently advanced over the guide wire. Then, the guidewire was withdrawn and under fluoroscopy a small amount of contrast

Received November 19, 1981; accepted after revision March 16, 1982.

<sup>1</sup> Department of Diagnostic Radiology, Division of Neuroradiology, University of Alabama, Birmingham, AL 35294. Address reprint requests to J. J. Vitek.

<sup>2</sup> Department of Surgery, Division of Neurosurgery, University of Alabama, Birmingham, AL 35294.

**AJNR 3:541–546, September/October 1982**  
0195–6108/82/0305–0541 \$00.00  
© American Roentgen Ray Society



agent was injected to confirm the intraluminal position of the catheter.

Using a 0.035 inch (0.89 mm) exchange wire, a balloon catheter was introduced. During the exchange, the level of the stenotic area and the tip of the exchange wire were continuously monitored by fluoroscopy to make sure the tip of the exchange wire did not move distally or slip proximally into the common carotid artery. The balloon was then positioned between the previously marked proximal and distal levels of the stenosis. After the exchange wire was withdrawn, the intraluminal position of the balloon catheter was ascertained again by injection of a small amount of contrast material. The balloon was hand-inflated using a 10 ml syringe filled with a mixture of 50% saline and 50% contrast material. The inflation pressure was registered on a pressure gauge. (It is important not to exceed the maximum pressure indicated by the manufacturer for particular types of balloon catheters.) The shape of the balloon was observed fluoroscopically during inflation to monitor the progress of dilatation. The balloon was inflated twice in the same position for a period of 5–10 sec [3–5, 14]. A 20 ml syringe was used for deflation.

The catheter was withdrawn into the middle part of the common carotid artery and a control arteriogram was obtained. To facilitate removal of the balloon catheter, negative pressure was applied to the balloon during the withdrawal from the femoral artery. In two patients, angiographic studies performed immediately, 20 days, and 5 weeks after percutaneous transluminal angioplasty are available.

#### *Technical Considerations*

1. Introduction of the balloon catheter at the site of previous femoral artery puncture for angiography should be avoided. Scarring and fibrosis surrounding the previously punctured artery could damage the balloon [15]. Also, the introduction of the balloon catheter into a nontraumatized femoral artery is technically easier. An introductory sheath can be used. This would decrease the damage inflicted on the artery during the withdrawal of the balloon catheter and also damage to the balloon catheter itself.

2. It is important to mark accurately both the proximal and distal levels of the stenosis by radiopaque skin markers before the polyethylene catheter is introduced because the dilatation balloon is relatively short and its positioning must be precise. Any head movement during the procedure should be avoided.

3. Avoidance of subintimal passage of the guide wire is critical when traversing the stenosis.

4. The selection of the balloon catheter is of paramount importance. The tip of the catheter, which is relatively sharp, should be short to avoid damage to the distal part of the main trunk of the external carotid artery, which is often tortuous. (In case 2, the tip of the catheter slightly damaged the intima of the external carotid artery and elicited spasm.) The balloon does not need to be longer than 2 cm for the same reason. The length of the balloon catheter must be sufficient to reach the external carotid artery. A 100 cm length, especially in tall patients, is required. The size of the balloon used in the three patients in this report was 6 mm. The reason for this relatively large balloon is explained later. Therefore, we suggest the use of a 100-cm-long balloon catheter, size 7.0 French, with a 0.035 inch (0.89 mm) guide wire and balloon 6 mm in diameter, 2.0 cm long, and having a 1.0 cm tip (7.0–35–100–6–2–1). Currently, this type of balloon catheter must be specially ordered.

5. Splitting of the atheroma and intima has been demonstrated to occur during angioplasty [14, 16]. Therefore, if reintroduction of

the balloon catheter is required due to suboptimal dilatation, there is a significant possibility of subintimal passage. This hazard can be averted by introduction of a small guide wire before removal of the angioplasty catheter.

## **Case Reports**

### *Case 1*

A 50 year-old man was admitted to University Hospital because of intermittent episodes of left cerebral hemisphere transient ischemic attacks manifested by right upper extremity weakness and dysphasia. Angiography showed complete occlusion of the right internal carotid artery with a very tight and ulcerated stenosis of the origin of the left internal carotid artery. The patient underwent left carotid endarterectomy and was discharged. Postoperatively, he experienced the same symptoms as before surgery. Neurologic examination was again unremarkable.

The left superficial temporal artery pulse was palpable, but much weaker than on the right. Repeat angiography (Figs. 1A and 1B) showed complete occlusion of the internal carotid artery with a high degree of stenosis of the origin of the external carotid artery, most likely due to intimal dissection [17] just above the level of the endarterectomy (fig. 1B). We decided that before left superficial temporal artery–middle cerebral artery bypass, the patient would benefit from a left external carotid artery angioplasty, which was subsequently performed without difficulty (fig. 1C). The patient was discharged and readmitted 2 weeks later for the bypass. His postoperative recovery was uncomplicated and he has had no further symptoms. Twenty days after PTA a third angiogram was obtained (figs. 1D and 1E) and demonstrated a good result.

### *Case 2*

A 59-year-old man was admitted because of mental confusion and inability to use his right arm. Dysphasia was presented on neurologic examination. Cerebral angiography (fig. 2A) demonstrated complete occlusion of the left internal carotid artery with stenosis of the origin of the left external carotid artery. The right carotid artery and left vertebral artery studies were unremarkable with filling of the left middle cerebral artery through the left posterior communicating artery. PTA of the left external carotid artery (fig. 2B) was performed followed by a left superficial temporal–middle cerebral artery bypass 4 weeks later. Follow-up arteriography 5 weeks after the angioplasty and 1 week after the bypass (fig. 2C) showed relief of the stenosis.

### *Case 3*

A 60-year-old man presented with left-sided homonymous hemianopia due to a previous right occipital infarct. Recently, he had noted transient blurring of vision on the right side and right retroorbital pain. He was hypertensive, and except for the left homonymous hemianopia his neurologic examination was unremarkable. There were bilateral carotid bruits.

Angiography revealed 80% stenosis of the origin of the left internal carotid artery and complete occlusion of the right internal carotid artery with stenosis of the origin of the right external carotid artery (fig. 3A). The right anterior and middle cerebral arteries were supplied through the anterior communicating artery. The left vertebral artery and basilar artery were patent. The patient underwent a



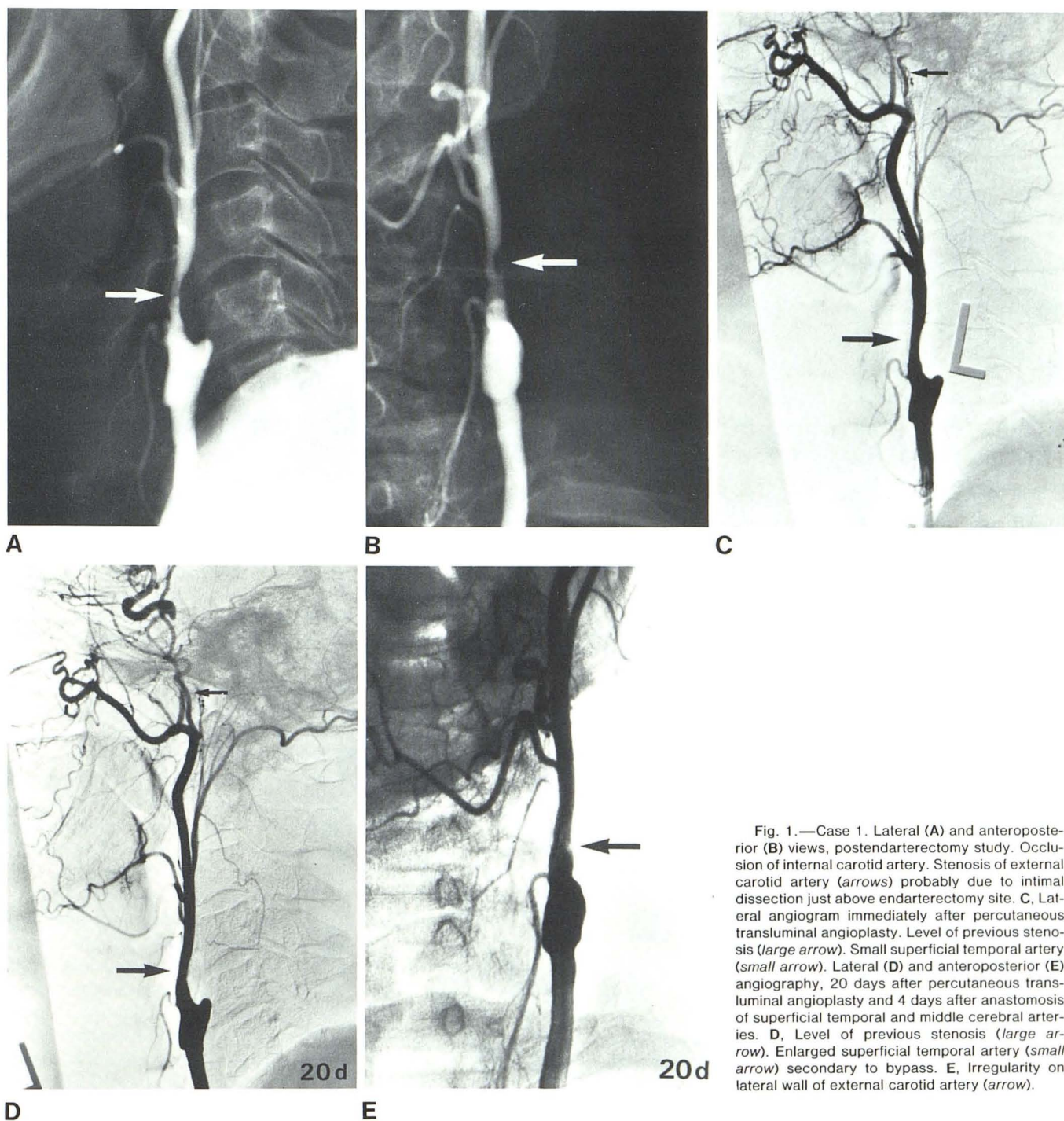


Fig. 1.—Case 1. Lateral (A) and anteroposterior (B) views, postendarterectomy study. Occlusion of internal carotid artery. Stenosis of external carotid artery (arrows) probably due to intimal dissection just above endarterectomy site. C, Lateral angiogram immediately after percutaneous transluminal angioplasty. Level of previous stenosis (large arrow). Small superficial temporal artery (small arrow). Lateral (D) and anteroposterior (E) angiography, 20 days after percutaneous transluminal angioplasty and 4 days after anastomosis of superficial temporal and middle cerebral arteries. D, Level of previous stenosis (large arrow). Enlarged superficial temporal artery (small arrow) secondary to bypass. E, Irregularity on lateral wall of external carotid artery (arrow).

right external carotid artery angioplasty (fig. 3B) in preparation for a right superficial temporal artery–middle cerebral artery bypass. A total of 1,000 U of heparin was injected through the catheter after the angioplasty. After the procedure, the patient developed a relatively large hematoma in the right groin and scrotum. The heparin was reversed and the hematoma gradually resolved. The patient

was discharged 4 days after PTA. He was readmitted and underwent a right superficial temporal artery–middle cerebral artery bypass 4 weeks later without complications. Since discharge, the patient had no recurrence of his blurred vision. After control of hypertension, his headaches disappeared. He subsequently underwent a left carotid endarterectomy.



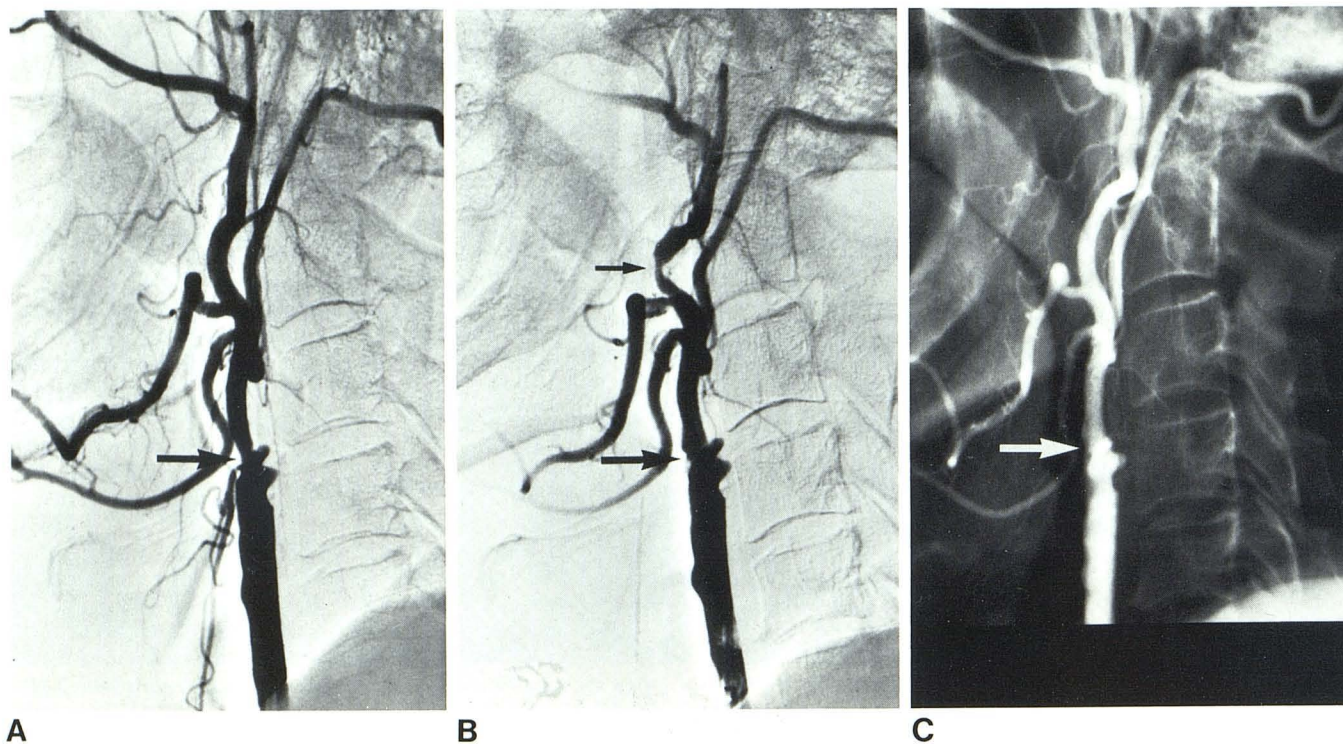


Fig. 2.—Case 2. **A**, Occlusion of left internal carotid artery. Stenosis of origin of external carotid artery (*arrow*). **B**, Angiography immediately after percutaneous transluminal angioplasty. Level of previous stenosis (*large arrow*). Spasm of distal external carotid artery (*small arrow*). **C**, 5 weeks after

percutaneous transluminal angioplasty and 2 weeks after anastomosis of superficial temporal and middle cerebral arteries. Level of previous stenosis (*arrow*).

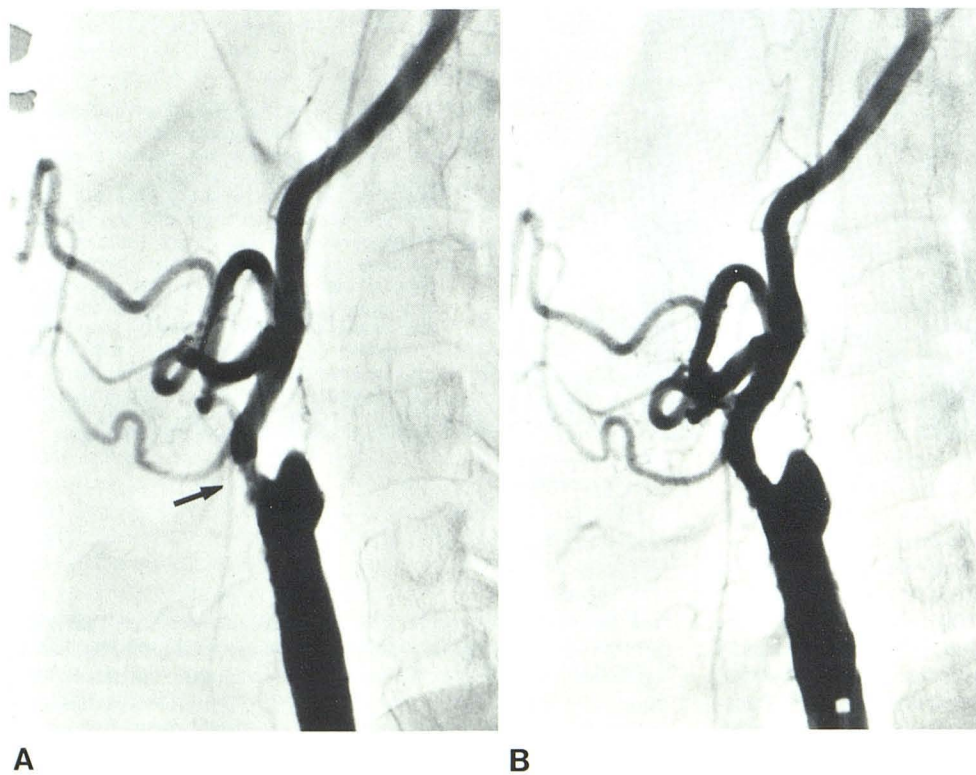


Fig. 3.—Case 3. **A**, Occlusion of right internal carotid artery with stenosis of origin of external carotid artery (*arrow*). **B**, Angioplasty immediately after percutaneous transluminal angioplasty with good result.



## Discussion

Growing acceptance of PTA as an alternative to vascular surgery is evident in the number and diversity of recent reports. When stenotic vascular lesions can be corrected without general anesthesia and surgery, there are obvious benefits for the patient. The objective of PTA [18] is to improve flow through the diseased segment of the vessel so that the likelihood of long-term vessel patency is increased and embolization is decreased. Several reports have described the use of PTA in the treatment of stenosis of the brachiocephalic arteries. Hasso et al. [10] reported two patients with stenotic fibromuscular hyperplasia of the internal carotid artery treated with PTA. Mullan et al. [13] described a weblike stenosis of the internal carotid artery successfully dilated with balloon catheter angioplasty. Motarjeme et al. [11] performed PTA on the origins of the vertebral arteries in patients with vertebrobasilar insufficiency. The dilatation alleviated the symptoms and made surgery unnecessary. Bachman and Kin [9] corrected a subclavian steal syndrome by dilating the proximal segment of the left subclavian artery. Kerber et al. [12] used a coaxial catheter system to dilate the proximal stenosis on the left common carotid artery. The catheter system was introduced into the vessel in a retrograde direction during the carotid bifurcation endarterectomy.

Good flow through the external carotid artery is a prerequisite for long-term patency of superficial temporal-middle cerebral artery anastomoses. If the origin of the external carotid artery is significantly stenosed, then endarterectomy has been the treatment of choice. Because the external carotid artery is a relatively small vessel with multiple branches, thrombosis as a surgical complication is not rare. In one of our cases, an unsuccessful carotid endarterectomy resulted in thrombosis of the internal carotid artery and stenosis of the origin of the external carotid artery. PTA proved satisfactory method for treatment of the external carotid artery stenosis before superficial temporal-middle cerebral artery bypass.

The pathophysiologic events occurring during PTA have not been completely elucidated, but it seems that they may have important implications in the selection of the size of the balloon used. Block et al. [16] postulated that PTA produces endothelial desquamation and shearing of superficial intimal elements overlying the atherosclerotic plaque. Healing of the intima then leads to enlargement of the lumen about 1–2 weeks after angioplasty. In vessels with a tight stenosis, Block et al. described splits in the atheroma out to the internal elastic lamina. This causes an immediate increase in lumen size. At 1–2 weeks, retraction and endothelialization take place and lead to an enlarged lumen. Gruntzig [19] discussed "controlled injury" to the vessel wall. Huffman et al. [20] subscribed to the opinion that for successful angioplasty, the atheromatous material as well as the internal elastic lamina has to be split rather than just compressed. Castaneda et al. [14] maintained that because the atheromatous material is incompressible, pure redistribution and compression of the atheromatous material in the absence of dilatation of the artery itself would not achieve

the desired result. On the other hand, stretching of the media and adventitia, carried beyond a certain point, is irreversible. Thereafter the stretched media distends, carrying the intima and split atheromatous plaque with it. According to Castaneda et al., this theory is supported by further increase in the size and improvement in the appearance of the dilated vessel segment weeks and months after PTA.

If, indeed, permanent overstretching of the media is necessary for satisfactory angioplasty results, there are two important practical implications. First, the size of the balloon should be relatively large. (We used a 6 mm balloon for the external carotid artery.) Second, a complaint of pain in the region of the angioplasty should indicate that balloon deflation is necessary because the adventitia is the only part of the artery that is innervated, and its stretching elicits pain.

The role of anticoagulation (heparin) during angioplasty is uncertain at this time [3, 5, 9–11, 15]. In the only case in which we used heparin, a groin hematoma developed. Distal embolization has been much less common than predicted [4, 9, 15] during and after PTA, but, despite this, common carotid artery and internal carotid artery angioplasty in atherosclerotic disease has not been attempted for fear of cerebral embolization. Close examination of the pre-PTA angiogram is necessary to be sure that no large external carotid–internal carotid anastomoses exist. We did not detect any evidence of distal embolization, and post-PTA angiograms showed all the peripheral branches of the external carotid artery to be patent.

Although our experience is limited to three cases, we found PTA to be a useful initial step in performing superficial temporal-middle cerebral artery bypass in the presence of stenosis of the origin of the external carotid artery.

## REFERENCES

- Dotter CT, Judkins KP. Transluminal treatment of arteriosclerotic obstruction: description of a new technique and preliminary report of its application. *Circulation* 1964;30:654–670
- Gruntzig A, Hopff H. Perkutane Rekanalisation chronischer arterieller Verschlüsse mit einem neuen Dilatationskatheter. *Dtsch Med Wochenschr* 1974;99:2502–2505
- Motarjeme A, Keifer JW, Zuska AJ. Percutaneous transluminal angioplasty of the iliac arteries: 66 experiences. *AJR* 1980;135:937–944
- Greenfield AJ. Femoral, popliteal, and tibial arteries: percutaneous transluminal angioplasty. *AJR* 1980;135:927–935
- Tegtmeyer CJ, Dryer R, Teates CD, et al. Percutaneous transluminal dilatation of the renal arteries. *Radiology* 1980;135:589–599
- Block PC. Percutaneous transluminal coronary angioplasty. *AJR* 1980;135:955–959
- Novelline RA. Percutaneous transluminal angioplasty: newer applications. *AJR* 1980;135:983–988
- Saddekni S, Sniderman KW, Hilton S, Sos TA. Percutaneous transluminal angioplasty of nonatherosclerotic lesions. *AJR* 1980;135:975–982
- Bachman DM, Kin RM. Transluminal dilatation for subclavian steal syndrome. *AJR* 1980;135:995–996
- Hasso AN, Bird CR, Zinke DE, Thompson JR. Fibromuscular dysplasia of the internal carotid artery: percutaneous transluminal angioplasty. *AJNR* 1981;2:175–180

11. Motarjeme A, Keifer JW, Zuska AJ. Percutaneous transluminal angioplasty of the vertebral arteries. *Radiology* **1981**; 139:715-717
12. Kerber CW, Cromwell LD, Loehden OL. Catheter dilatation of proximal carotid stenosis during distal bifurcation endarterectomy. *AJNR* **1980**;1:348-349
13. Mullan S, Duda EE, Patronas NJ. Some examples of balloon technology in neurosurgery. *J Neurosurg* **1980**;52:321-329
14. Castaneda-Zuniga WR, Formanek A, Tadavarthy M, et al. The mechanism of balloon angioplasty. *Radiology* **1980**;135:565-571
15. Athanasoulis CA. Percutaneous transluminal angioplasty: general principles. *AJR* **1980**;135:893-900
16. Block PC, Fallon JT, Elmer D. Experimental angioplasty: lessons from the laboratory. *AJR* **1980**;135:907-912
17. Holder J, Binet EF, Flanigan S, Ferris EJ. Arteriography after carotid endarterectomy. *AJR* **1981**;137:483-487
18. Abele JE. Balloon catheters and transluminal dilatation: technical considerations. *AJR* **1980**;135:901-906
19. Grüntzig A. Percutaneous transluminal angioplasty (editorial). *AJR* **1981**;136:216-217
20. Hoffman MA, Fallon JT, Greenfield AJ, Waltman AC, Athanasoulis CA, Block PC. Arterial pathology after percutaneous transluminal angioplasty. *AJR* **1981**;137:147-149

#### Addendum

Since the acceptance of this manuscript, seven other patients underwent PTA on the stenotic origin of the external carotid artery. Six were successful.