



Discover Generics

Cost-Effective CT & MRI Contrast Agents

 FRESENIUS
KABI

[WATCH VIDEO](#)

AJNR

Low-cost digital subtraction angiography.

K K Ford, E R Heinz, G A Johnson, B D Drayer and P J Dubois

AJNR Am J Neuroradiol 1982, 3 (4) 448-451

<http://www.ajnr.org/content/3/4/448.citation>

This information is current as
of June 22, 2025.

Low-Cost Digital Subtraction Angiography

K. K. Ford,¹ E. R. Heinz, G. A. Johnson,
B. D. Drayer, and P. J. Dubois

Intravenous angiography was an important diagnostic tool earlier in this century [1], however, the technique had many drawbacks. Film timing was critical, the volume of contrast material was high, and the contrast resolution was often poor. When safer techniques for direct arteriography were developed, intravenous angiography was abandoned. Computed digital image processing has brought a resurgence of interest in intravenous angiography [2–13]. The enhanced contrast resolution of this technique approaches the contrast resolution of direct arteriography and requires smaller volumes of contrast material than the older techniques of intravenous angiography. In addition, it can be performed on an outpatient basis.

Several systems capable of performing digital intravenous angiography are commercially available, with prices of \$150,000–\$500,000. We are investigating the clinical application of a digital intravenous angiography system with capital equipment costs of about \$50,000. The system is designed around a Quantex DS-20 (Quantex Corp., Sunnyvale, Cal.) digital image processor. The basic components of our system and the results of some preliminary investigations are presented.

System Description

A schematic diagram of our system for digital intravenous angiography is shown in figure 1. The x-ray equipment is a Phillips remote control fluoroscopic unit with a 22.9 cm, 12.7 cm dual mode cesium iodide image intensifier, coupled to a 525 line plumbicon television system. The x-ray generator was modified to provide up to 30 sec of fluoroscopy at high current, either 10, 20, or 30 mA, with kilovoltage ranging up to 80 kVp. No interface between the generator and Quantex unit is necessary. The x-ray beam is filtered using 1 mm of aluminum and 0.1 mm of copper. The entrance exposure under normal operating conditions (70 kVp, 30 mA) is <5 R/min (1.3 mC/kg/min) as measured with MDH 10 × 5–6 dosimeter at the skin entrance site.

The output from the plumbicon camera is simultaneously recorded onto a Sony 2600 videotape recorder with a 3.5 MHz band width and entered into a Quantex DS-20 digital

image processor. The Quantex unit consists of an 8 bit analog to digital converter with a single image memory capable of storing a 512 × 512 matrix 12 bits deep. Because the Quantex has a single image memory, the videotape recorder was used as an external memory storage device. The Quantex will digitize 30 video frames/sec and can either sum or average the resulting digitized images that are then displayed on the television monitor. For hard copy, the images were photographed on a matrix camera. Further details of the system have been reported [14].

To produce a digital intravenous angiogram, a predetermined number of images (usually 20 to 30) are digitized and summed into the memory of the Quantex before the arrival of contrast material. The image in memory is then inverted to produce a negative mask. After the arrival of contrast material into the field, an equal number of frames is summed into the memory on top of the inverted mask producing a subtraction angiogram. The contrast in the image is then augmented using the output transformation capabilities of the Quantex. This output transformation uses a digital look-up table hard-wired into the Quantex DS-20.

For the studies in both animals and humans, contrast material is injected in an antecubital vein through an angiocath at about 15 ml/sec. The dose of contrast material ranges from 0.5 to 1.0 ml/kg.

Results

By comparing images of phantoms produced in real-time and reconstructed from the videotape, we documented no image degradation from the videotape [14]. Using the method of injection described above, images of diagnostic quality were produced in both the carotid and renal arteries in mongrel dogs. Several animals underwent both digital intravenous angiography and direct angiography, and there was excellent correlation between the two studies (fig. 2).

As we began our clinical studies, we selected patients who had underlying diseases (usually coronary artery disease) that was believed to significantly increase the risk of direct angiography. The digital examination was, therefore, being used as a screening examination. However, in these

Received September 15, 1981; accepted after revision January 7, 1982.

Presented at the annual meeting of the American Society of Neuroradiology, Chicago, April 1981.

¹All authors: Department of Radiology, Duke University Medical Center, Durham, NC 27710. Address reprint requests to K. K. Ford.

patients, we succeeded in providing images of diagnostic quality, and there has been excellent correlation between those patients who have had the digital intravenous angiogram and direct carotid arteriography (fig. 3). As reported by other authors, we have noted a problem with swallowing artifacts using ionic contrast material (fig. 4), however, even in these cases, the images of at least one carotid artery from each injection were of diagnostic quality. In addition, we have successfully examined patients to determine preoperative localization of the intracranial carotid arteries before transsphenoidal surgery (fig. 5).

Discussion

The digital intravenous angiograms that we have been able to produce using our system are of diagnostic quality, but they were obtained without logarithmic amplification. This results in incomplete subtraction of dense bony struc-

tures. For example, on the images of the dog aorta, the spinous processes can be seen through the contrast-filled aorta. This incomplete bony subtraction could be a problem if the artery being examined overlies a dense bony structure. However, with appropriate centering, this problem can be avoided. For the visualization of the carotid arteries in humans, this has not interfered with the diagnostic quality of our examinations.

The system we are describing has both advantages and limitations. One of the main limitations is that the memory is capable of storing only one static image, and, therefore, when multiple images from any given examination are desired, they must be recreated and photographed one image at a time. However, since the examination has been stored on videotape, one can easily go back and play the videotape through again and reconstruct images from various times throughout the examination. A second limitation is quantum noise in the final images [15]. Summing several video frames reduces both the electronic noise and quantum noise in the final image. Electronic noise, however, is reduced more effectively by summing so that quantum noise becomes the dominant noise causing image degradation [16]. Increasing the milliamperage value would decrease the quantum noise, but there are tube limits on the milliamperage in a continuous fluoroscopic mode. Pulsed-radiographic exposures would provide a higher milliamperage, but these would necessitate interfaces between the generator and the digital unit, which is unnecessary in our system.

The advantages of the system we are describing are the simplicity in operating the system and its low cost. In addition, the main components of the system are a videotape recorder and a Quantex unit; both can be mounted easily on a cart and transported from room to room within the department. Some care must be exercised in choice of the

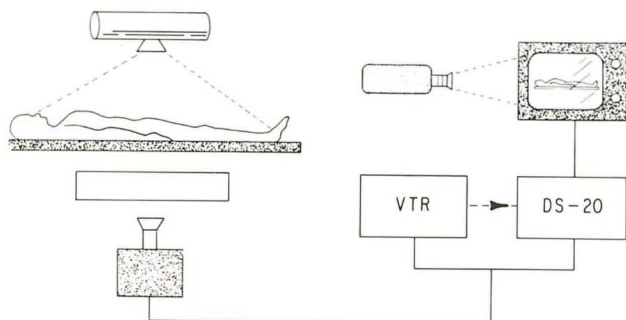


Fig. 1.—Schematic diagram of digital intravenous angiography system. VTR = videotape recorder.

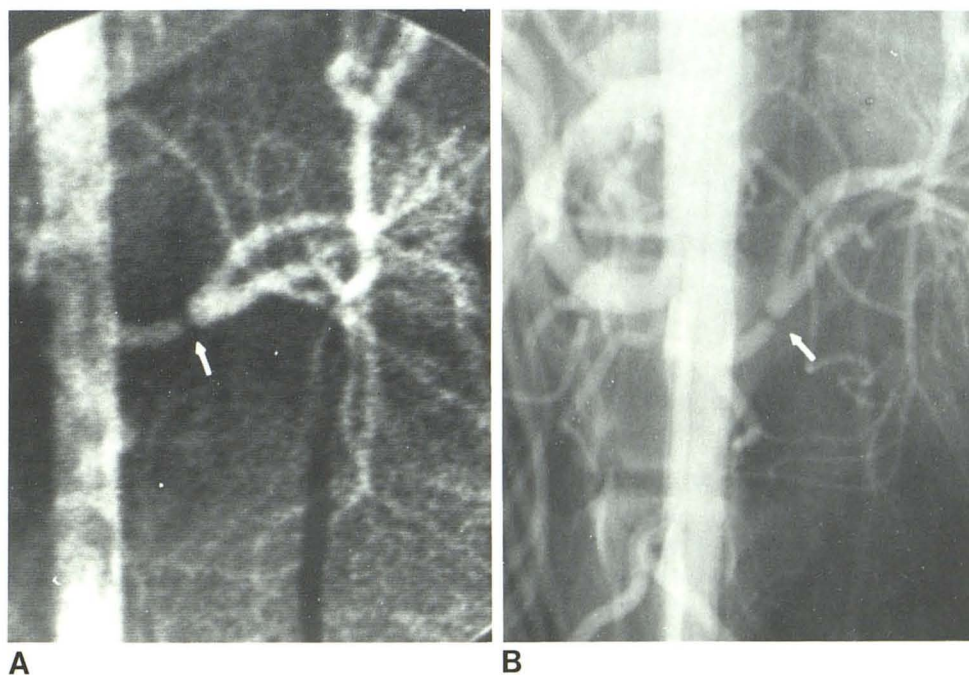


Fig. 2.—Renal artery stenosis (surgical) (arrows) in a dog. Digital intravenous angiogram (A) and conventional aortogram (B).

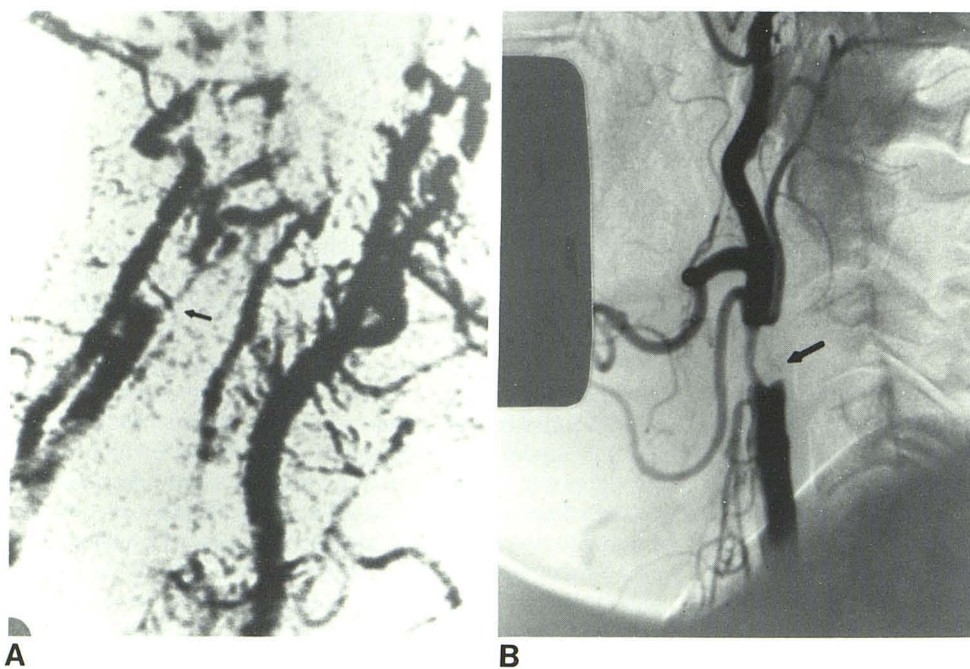


Fig. 3.—Right internal carotid occlusion and stenosis of right external carotid (arrows). Digital intravenous angiogram in left posterior oblique projection (A) and common carotid arteriogram (B).

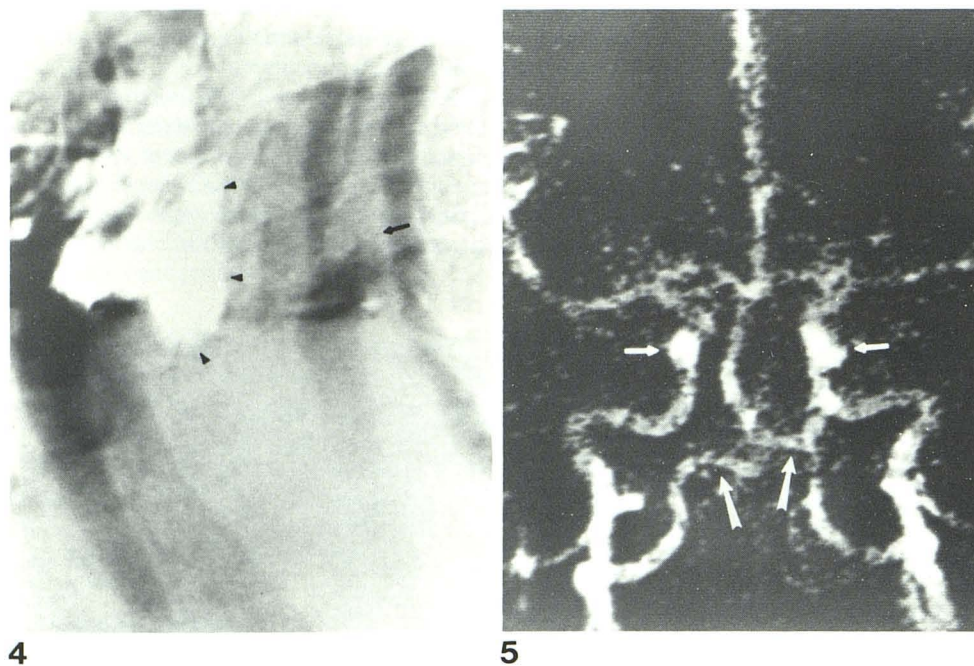


Fig. 4.—Occlusion of left internal carotid artery and stenosis of left external carotid artery (arrow) in right posterior oblique projection. Swallowing artifact obscures right common carotid (arrowheads).

Fig. 5.—Intracranial carotid arteries before transsphenoidal surgery. Both carotid systems (short arrows) and vertebrobasilar system (long arrows) are opacified.

x-ray system and video chain. For example, a plumbicon television system is preferable because of its low signal-to-noise ratio, and the signal-to-noise of the entire TV chain should be ≥ 40 dB. These are not unreasonable criteria for most current fluoroscopic equipment.

The main advantage of the system, however, is its very low cost compared with other commercially available systems. The purchase price for the Quantex DS-20 is \$45,000. A videotape recorder costs about \$3,000 and modifications to provide 30 mA fluoroscopy are estimated to cost

about \$2,000. The total capital equipment cost of the system, therefore, is about \$50,000, excluding a camera to provide hard copies. These cameras are relatively expensive (\$15,000), and a Polaroid camera could easily be used to photograph the images on the television monitor for archival purposes.

Our low-cost digital system has produced intravenous angiograms of diagnostic quality in both the carotid and renal arteries. How much these images can be improved within a reasonable cost will require further investigation

and study. However, we believe it is possible to provide diagnostic digital angiograms at a cost significantly less than commercially available systems.

REFERENCES

1. Robb GP, Steinberg I. Visualization of the chambers of the heart, the pulmonary circulation and the great blood vessels in man. *AJR* 1939;41:1-17
2. Baily NA. Video techniques for xray imaging and data extraction from roentgenographic and fluoroscopic presentations. *Med Phys* 1980;7:472-491
3. Brody WR, Enzmann DR, Deutsch LS, Hall A, Pelc N. Intravenous carotid arteriography using line-scanned digital radiography. *Radiology* 1981;139:297-300
4. Buonocore E, Meaney TF, Borkowski GP, Pavlicek W, Gallagher J. Digital subtraction angiography of the abdominal aorta and renal arteries. Comparison with conventional aortography. *Radiology* 1981;139:281-286
5. Chilcote WA, Modic MT, Pavlicek WA, et al. Digital subtraction angiography of the carotid arteries: a comparative study in 100 patients. *Radiology* 1981;139:287-295
6. Christenson PC, Ovitt TW, Fisher HD III, Frost MM, Nudelman S, Roehrig H. Intravenous angiography using digital video subtraction: intravenous cervicocerebrovascular angiography. *AJNR* 1980;1:379-386, *AJR* 1980;135:1145-1152
7. Crummy AB, Strother CM, Sackett JF, et al. Computerized fluoroscopy: digital subtraction for intravenous angiocardiology and arteriography. *AJR* 1980;135:1131-1140
8. Hillman BJ, Ovitt TW, Nudelman S, et al. Digital video subtraction angiography of renal vascular abnormalities. *Radiology* 1981;139:277-280
9. Kruger RA, Anderson RE, Koehler R, Nelson JA, Sorenson JA, Morgan T. A method for the noninvasive evaluation of cardiovascular dynamics using a digital radiographic device. *Radiology* 1981;139:301-305
10. MacIntyre WJ, Pavlicek W, Gallagher JH, Meaney TF, Buonocore E, Weinstein MA. Imaging capability of an experimental digital subtraction angiography unit. *Radiology* 1981;139:307-313
11. Meaney TF, Weinstein MA, Buonocore E, et al. Digital subtraction angiography of the human cardiovascular system. *AJR* 1980;135:1153-1160
12. Mistretta CA, Crummy AB, Strother CM. Digital angiography: a perspective. *Radiology* 1981;139:273-276
13. Ovitt TW, Christenson PC, Fisher HD, et al. Intravenous angiography using digital video subtraction: x-ray imaging system. *AJNR* 1980;1:387-390, *AJR* 1980;135:1141-1144
14. Johnson GA, Ford KK, Heinz ER. Digital radiography using the Quantex DS-20. *Proc SPIE* 1981;273:114-119
15. Johnson GA, Nelson CE, OFoghludha F. Imaging limits in digital radiography. Presented at the annual meeting of the Association of University Radiologists, New Orleans, April 1981
16. Riederer SJ, DiBianca FA, Georges JPJ, et al. Performance characteristics of a digital fluorographic system. *Proc SPIE* 1981;273:88-95