



**Providing Choice & Value**  
Generic CT and MRI Contrast Agents

**FRESENIUS  
KABI**

**CONTACT REP**

**AJNR**

**Lymphoid adenohypophysitis with radiologic and clinical findings resembling a pituitary tumor.**

G D Hungerford, P J Biggs, J H Levine, B E Shelley, Jr, P L Perot and J K Chambers

*AJNR Am J Neuroradiol* 1982, 3 (4) 444-446  
<http://www.ajnr.org/content/3/4/444.citation>

This information is current as  
of July 23, 2025.

# Lymphoid Adenohypophysitis with Radiologic and Clinical Findings Resembling a Pituitary Tumor

G. Douglas Hungerford,<sup>1</sup> Paul J. Biggs,<sup>2</sup>  
Jon H. Levine,<sup>3</sup> B. Edgar Shelley, Jr.,<sup>1</sup>  
Phanor L. Perot,<sup>4</sup> and Jerre K. Chambers<sup>5</sup>

Lymphoid hypophysitis is an apparently rare condition which was initially reported as a postmortem finding in six patients [1-6]. In these patients, death was related to the relatively rapid development of hypopituitarism. It has recently been described in four living patients [7-9]. In the previous case reported by us, visual fields were normal and a computed tomography (CT) scan was normal although the sella was ballooned at tomography. However, as the present case shows, the radiological and clinical findings may closely simulate a pituitary tumor with suprasellar extension.

## Case Report

A 27-year-old woman, gravida 3, para 2, with one miscarriage, suddenly developed severe, throbbing parietal headaches during the eighth month of her pregnancy. The headaches were relieved by Darvocet and decreased in intensity after 1 week. Four weeks before delivery she developed blurred vision which gradually deteriorated further. She subsequently had an uncomplicated labor and delivery and gave birth to a normal 4,417 g boy. Blood loss was minimal.

Three weeks after delivery she was referred to an ophthalmologist who found a bitemporal field defect, and she was admitted for further workup. There had been no menses since the pregnancy. Physical examination was normal apart from visual abnormalities. Visual acuity was 20/400 in the left eye and 20/50 in the right. A bitemporal hemianopsia was present on visual field testing by Goldmann perimetry. A skull radiograph showed a normal-size sella with some erosion of the dorsum sellae and demineralization of the cortical margins. CT showed a mass in the sella and suprasellar region (fig. 1) which was initially slightly more dense than brain. After administration of 300 ml of diatrizoate meglumine 30% by rapid intravenous infusion, the mass showed intense, uniform enhancement. Bilateral carotid angiograms using  $\times 1.5$  magnification, a 0.18 mm focal spot tube, and subtraction images showed no abnormal vascularity or blush. There was some mass effect, with elevation of the right anterior cerebral artery indicating suprasellar extension of the mass. Random blood glucose levels on several occasions ranged from 128 to 181 mg/dl. Other laboratory studies

showed hemoglobin 14.5 g/dl, serum prolactin 11.5 ng/dl,  $T_3$  uptake 35%,  $T_4$  2.8  $\mu$ g/dl,  $T_7$  0.97 units, thyroid stimulating hormone 2.1  $\mu$ U/ml, and an 8 a.m. serum cortisol was 2.4  $\mu$ g/dl.

The patient was treated with glucocorticoids and thyroxine. Twenty-three days after delivery, she underwent a bifrontal craniotomy with removal of a firm, minimally vascular mass with an unusual grayish-yellow appearance. Postoperatively she has had normalization of her visual fields and is feeling well on replacement with prednisone and thyroxine.

Histologically all of the resected tissue was identified as adenohypophyseal tissue. There was separation of the adenohypophyseal cells into small groups by a mixture of collagenous connective tissue and an extensive infiltrate of chronic inflammatory cells (fig. 2). The groups of adenohypophyseal cells were surrounded by an intact reticulin framework for the most part, although many of these groups did contain some inflammatory cells. Occasional necrotic or degenerating cells were encountered, but it was uncertain whether there was a significant overall loss of adenohypophyseal cells. The cellular infiltrate was composed of small lymphocytes and mature plasma cells, along with a few scattered eosinophilic granulocytes. Lymphoid follicles were often encountered. These contained a few phagocytic histiocytes; however, no germinal centers were noted. No granulomas were seen. Stains for microorganisms were performed, and no organisms could be identified. The histologic findings are typical of previously reported cases of lymphoid adenohypophysitis.

## Discussion

The differential diagnosis of an enhancing intra- or suprasellar mass seen on CT includes tumors, granulomas, aneurysms, and some miscellaneous lesions. Enhancing tumors in this region include pituitary adenoma, craniopharyngioma, meningioma, germinoma [10], chordoma [11], hypothalamic or optic chiasm glioma [12], myeloma, and malignant teratoma [12]. Pituitary apoplexy may cause a similar appearance [13] and aneurysms [14] may mimic a tumor. Sarcoidosis is the most common granuloma in this region (Brooks BS, El Gammal T, Hungerford GD, unpublished

Received October 15, 1981; accepted after revision January 8, 1982.

<sup>1</sup> Department of Radiology, Medical University of South Carolina, 171 Ashley Ave., Charleston, SC 29425. Address reprint requests to G. D. Hungerford.

<sup>2</sup> Department of Pathology, Medical University of South Carolina, Charleston, SC 29425.

<sup>3</sup> Department of Medicine, Medical University of South Carolina, Charleston, SC 29425.

<sup>4</sup> Department of Neurosurgery, Medical University of South Carolina, Charleston, SC 29425.

<sup>5</sup> Department of Ophthalmology, Medical University of South Carolina, Charleston, SC 29425.



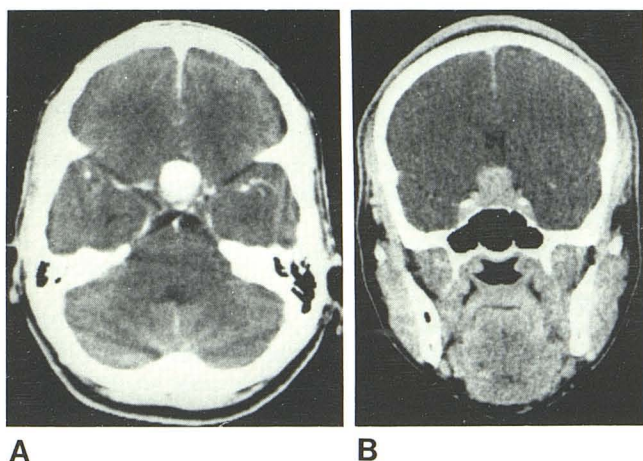


Fig. 1.—Axial (A) and coronal (B) CT sections after infusion of 300 ml of diatrizoate meglumine. Large enhancing mass in sella and suprasellar region.

data). A hamartoma can occur in this region, but it usually does not enhance [15]. Pituitary hyperplasia may present as an enhancing mass [16].

Our patient is the fourth reported example of lymphoid adenohypophysitis in whom computed tomography has shown an abnormality. Asa et al. [9] described two cases. One showed a large intra- and suprasellar enhancing mass, similar to our case. The other was said to show a pituitary fossa mass. Quencer [8] described a patient who showed a slight pituitary enlargement similar to a pituitary microadenoma, the gland having an upward convexity and enhancing uniformly. A previous case studied by CT, which was reported from our institution, had a CT scan using an early model CT scanner which showed no abnormality despite an enlarged sella, but thin section and coronal cuts were not possible [7]. Seven of the patients have had a large pituitary gland, either at autopsy or during life. This is the second case in which a large suprasellar extension has been present.

Angiography has recently been suggested as a possible test for discriminating this lesion from a pituitary tumor preoperatively [17]. Topliss and Volpé [17] considered that angiographically an adenoma would be vascular, and lymphoid adenohypophysitis would be avascular. Our case is the second in which angiography has been performed. It showed no abnormal vascular blush or abnormal vessels; however, the appearance was indistinguishable from an avascular pituitary adenoma.

The frequent association of this condition with rapidly developing hypopituitarism accounts for the death of six of the 11 patients within 1 year of the onset of symptoms. This association makes it important that the diagnosis be considered early in the course of the illness so that appropriate therapy can be instituted. Our own patient had hypopituitarism, which either was sufficiently mild that she could survive childbirth without morbidity or else must have started after pregnancy.

There is also a frequent, but inconstant, association with a recent pregnancy. All patients to date have been women,

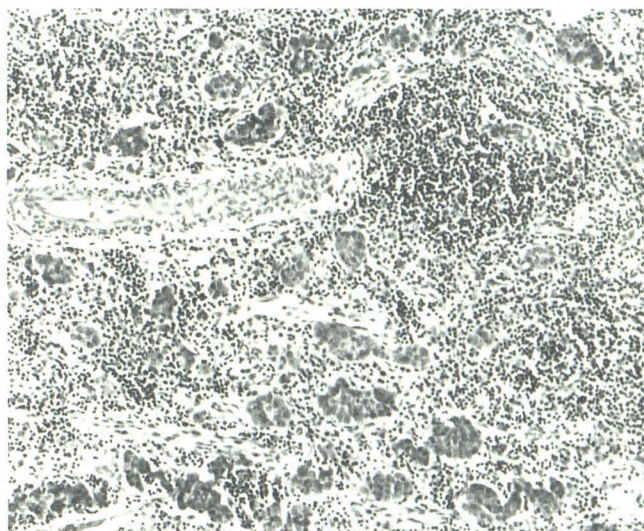


Fig. 2.—H and E, medium-power paraffin section. Adenohypophysis showing lymphoid follicles, interstitial fibrosis and inflammation, and scattered islands of anterior pituitary cells.

and eight have developed symptoms within 1 year after giving birth, leading to speculation that pregnancy may be a factor in the initiation of the disease. Some evidence in support of this is seen in the studies of Engelberth and Ježková [18], who found increased levels of circulating pituitary antibodies in 18% of women 5–7 days after giving birth. Signs of anterior pituitary deficiency subsequently developed in 25% of those women in whom antibody levels remained elevated 6–12 months after delivery. However, the patients so far described in the literature have been aged 22–74 years, and there was one nulliparous patient. Two patients had had hysterectomies, one 22 years earlier.

The inflammatory process of lymphoid hypophysitis has been confined to the anterior pituitary in all cases, with no abnormal lymphocytic infiltration of the pars intermedia or posterior pituitary. Concomitant lymphocytic infiltration of other organs has been described in three cases [1, 2, 4]. Hashimoto thyroiditis was present in two, and one patient had infiltration in a parathyroid gland.

As yet there is no certain method of establishing the diagnosis by radiologic, clinical, or laboratory criteria. It may be suspected if an intra- or suprasellar enhancing mass is found on CT in an woman who has had a normal delivery within the previous 12 months. Suspicion is further aroused if there is evidence of rapidly progressive hypopituitarism. Pituitary autoantibodies may be present in the serum, but they may be found in a variety of disorders [19] and in normal postpartum women [18]. Until more specific diagnostic methods become available, the diagnosis will only be proven by histologic examination of a tissue specimen.

#### REFERENCES

1. Goudie RB, Pinkerton PH. Anterior hypophysitis and Hashimoto's disease in a young woman. *J Pathol Bacteriol* 1961;83:584–585



2. Hume R, Roberts GH. Hypophysitis and hypopituitarism: report of a case. *Br Med J* **1967**;2:548-550
3. Egloff B, Fischbacher W, von Goumoëns E. Lymphomatöse Hypophysitis mit Hypophyseninsuffizienz. *Schweiz Med Wochenschr* **1969**;99:1499-1502
4. Lack EE. Lymphoid "hypophysitis" with end organ insufficiency. *Arch Pathol* **1975**;99:215-219
5. Gleason TH, Stebbins PL, Shanahan MF. Lymphoid hypophysitis in a patient with hypoglycemic episodes. *Arch Pathol Lab Med* **1978**;102:46-48
6. Richtsmeier AJ, Henry RA, Bloodworth JMB, Ehrlich EN. Lymphoid hypophysitis with selective adrenocorticotrophic hormone deficiency. *Arch Intern Med* **1980**;140:1243-1245
7. Mayfield RK, Levine JH, Gordon L, Powers J, Galbraith RM, Rawe SE. Lymphoid adenohypophysitis presenting as a pituitary tumor. *Am J Med* **1980**;69:619-623
8. Quencer RM. Lymphocytic adenohypophysitis: autoimmune disorder of the pituitary gland. *AJNR* **1980**;1:343-345
9. Asa SL, Bilbao JM, Kovacs K, Josse RG, Kreines K. Lymphocytic hypophysitis of pregnancy resulting in hypopituitarism: a distinct clinicopathologic entity. *Ann Intern Med* **1981**;95:166-171
10. Takeuchi J, Hajime H, Nagata I. Suprasellar germinoma. *J Neurosurg* **1978**;4:41-48
11. Banna M, Baker HL, Houser OW. Pituitary and paraspituitary tumours on computed tomography. A review article based on 230 cases. *Br J Radiol* **1980**;53:1123-1143
12. Miller JH, Peña AM, Segall HD. Radiological investigation of sellar region masses in children. *Radiology* **1980**;134:81-87
13. Post JD, David NJ, Glaser JS, Safran A. Pituitary apoplexy: diagnosis by computed tomography. *Radiology* **1980**;134:665-670
14. Macpherson P, Anderson DE. Radiological differentiation of intrasellar aneurysms from pituitary tumours. *Neuroradiology* **1981**;21:177-183
15. Lin SR, Bryson MM, Gobien RP, Fitz CR, Lee YY. Radiologic findings of hamartomas of the tuber cinereum and hypothalamus. *Radiology* **1978**;127:697-703
16. Okuno T, Sudo M, Momoi T, et al. Pituitary hyperplasia due to hypothyroidism. *J Comput Assist Tomogr* **1980**;4:600-602
17. Topliss DJ, Volpé R. Lymphocytic hypophysitis (editorial). *Ann Intern Med* **1981**;95:227-228
18. Engelberth O, Ježková Z. Autoantibodies in Sheehan's syndrome. *Lancet* **1965**;1:1075
19. Bottazzo GF, Doniach D. Pituitary autoimmunity: a review. *J R Soc Med* **1978**;71:433-436