



Providing Choice & Value
Generic CT and MRI Contrast Agents

**FRESENIUS
KABI**

CONTACT REP

AJNR

Improved localization of carotid cavernous fistula during angiography.

C M Mehringer, G B Hieshima, V S Grinnell, F Tsai and H F Pribram

AJNR Am J Neuroradiol 1982, 3 (1) 82-84

<http://www.ajnr.org/content/3/1/82.citation>

This information is current as of July 19, 2025.

Improved Localization of Carotid Cavernous Fistula during Angiography

C. Mark Mehringer,¹ Grant B. Hieshima,¹
Verity S. Grinnell,¹ Fong Tsai,² and
H. F. W. Pribram³

The use of detachable balloons for treating carotid cavernous sinus fistulas is increasing [1–6]. Its success requires exact localization of the fistula site, which may not always be possible with standard angiographic techniques [7]. Rapid opacification of the venous side of the fistula is apt to obscure the point of arteriovenous communication before it is precisely delineated. Rapid filming (four or more films per second), special projections, and subtraction technique are useful adjuncts to standard technique but may not be adequate.

Several carotid occlusive techniques for improving the angiographic localization of carotid cavernous fistulas have been described. Huber [8] used ipsilateral carotid compression during vertebral artery injection to fill the fistula retrogradely via the posterior communicating artery. The fistula is often well localized by this method, but it requires a patent posterior communicating artery. Cares et al. [9] used a Prolo

balloon catheter to occlude the carotid artery at the fistula site or distal to it while injecting contrast medium through a proximal side port. Berenstein and Kricheff [10] used a double-lumen balloon catheter to occlude the carotid artery proximal to the fistula while injecting through an end hole.

Technique

We have used a simple, straightforward technique for improving fistula site localization. First, the internal carotid artery on the side of the fistula is catheterized with a standard angiographic catheter. The carotid artery proximal to the catheter tip is then temporarily occluded by digital compression while contrast injection and filming are simultaneously performed. Occlusion of the artery need be maintained only for the few seconds of filming; we usually film at

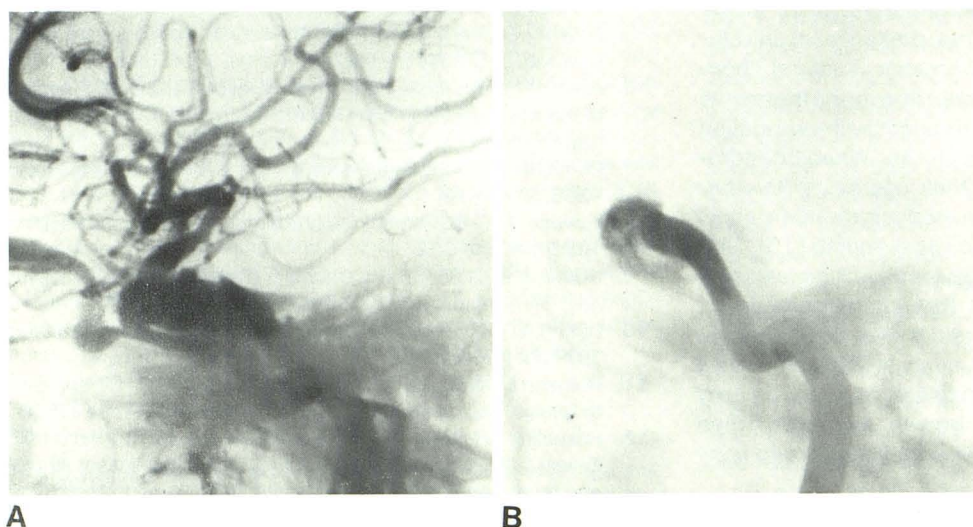


Fig. 1.—**A**, Early film from standard angiographic series. Carotid-cavernous fistula; exact site is unclear. **B**, With ipsilateral compression, level of fistula in carotid is seen.

Received January 26, 1981; accepted after revision July 24, 1981.

¹ Department of Radiology, Harbor-UCLA Medical Center, 1000 Carson St., Torrance, CA 90509.

² Department of Radiology, Orange County, University of California Irvine Medical Center, Orange, CA 92668.

³ Department of Radiology, Veterans Hospital, Long Beach, Ca 90801.

Fig. 2.—**A** and **B**, Routine lateral and frontal views fail to show precise fistula site. **C** and **D**, With ipsilateral compression. Fistula site in posterior medial aspect of cavernous carotid (*arrowheads*).

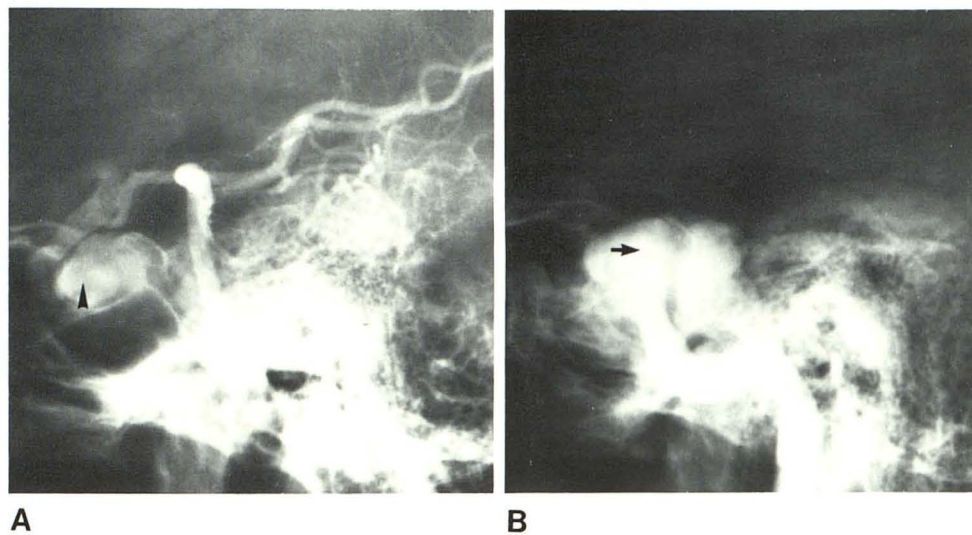
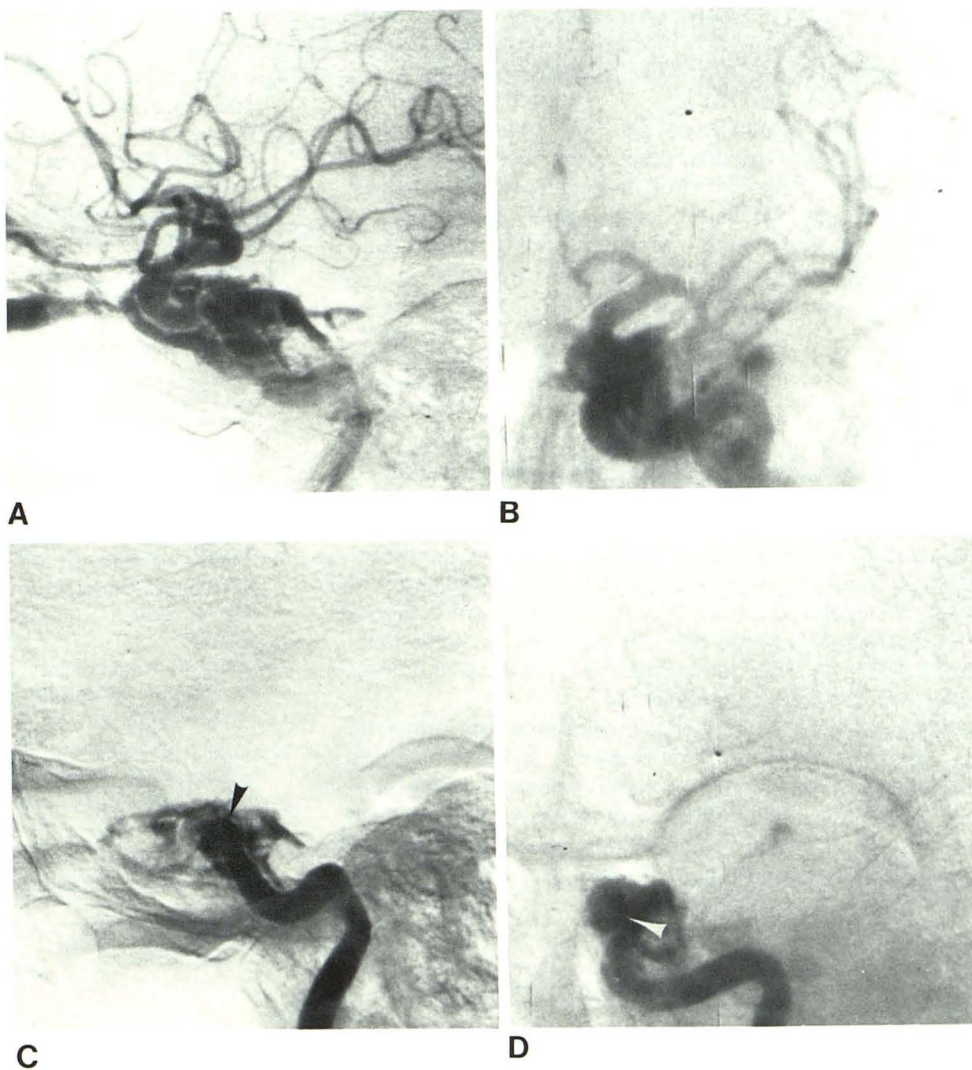


Fig. 3.—**A**, Demonstration of distal carotid and fistula (*arrowhead*) by Huber technique. **B**, Proximal carotid and fistula by carotid compression. Gap in carotid filling (length of *arrow*) using both techniques suggests transection of artery.

2 films/sec for 3 sec. By this maneuver, flow through the fistula is temporarily diminished and films showing the exact fistula site can be acquired before it is obscured by surrounding venous channels (fig. 1). Thorough occlusion of the carotid artery is necessary; this has not been difficult to achieve. The lateral angiographic projection usually provides more information. The frontal projection may be helpful in some cases, but we do not use it routinely (fig. 2). Coning the angiogram to the head or sella and orbital region minimizes radiation exposure to the operator's hand.

Discussion

We have used this technique in evaluating more than 30 of 40 patients with carotid cavernous fistula. It has been successful, demonstrating the exact fistula site in almost all instances. In some cases where there is a complete transection or a lengthy fistulous rent in the cavernous carotid artery, it is useful to employ Huber's technique in conjunction with ours. This better delineates the status of the distal carotid artery and any gap between the proximal and distal ends of the fistulous carotid (fig. 3).

We have found the technique to be safe and effective, and there have been no complications. Anticoagulation is not required and no special catheter is needed. The procedure is no more difficult to perform than angiography itself and can be easily and quickly accomplished during the initial angiographic evaluation.

REFERENCES

1. Serbinenko FA. Balloon catheterization and occlusion of a carotid cavernous fistula with a balloon catheter. *J Neurosurg* **1974**;41:125-145
2. Debrun G, Lacour P, Caron JP, Hurth M, Comoy J, Keravel Y. Inflatable and released balloon technique, experimentation in dog application in man. *Neuroradiology* **1975**;9:267-271
3. Debrun G, Lacour P, Caron JP, Hurth M, Comoy J, Keravel Y. Detachable balloon and calibrated-leak balloon techniques in the treatment of cerebral vascular lesions. *J Neurosurg* **1978**;49:635-649
4. Taki W, Handa H, Yamagata S, Yonekawa Y, Ikada Y, Iwata H. The releasable balloon technique with activated high frequency electrical current. *Surg Neurol* **1980**;13:405-408
5. Peeters FLM, Vander Werf AJM. Detachable balloon technique in the treatment of direct carotid-cavernous fistulas. *Surg Neurol* **1980**;7:11-19
6. Benati A, Maschio A, Perini S, Beltramello A. Treatment of posttraumatic carotid cavernous fistula using a detachable balloon catheter. *J Neurosurg* **1980**;53:784-786
7. Djindjian R, Picard L, Manelfe C. Fistules arterio-venuses carotid intern-somis caverneux aspects radio anatomiques: actuels et perspectives therapeutiques. *Neurochirurgie* **1973**;19:75-90
8. Huber P. A technical contribution to the exact angiographic localization of carotid cavernous fistulas. *Neuroradiology* **1976**;10:239-241
9. Cares HL, Roberson GH, Ground W, Hopkins LN. A safe technique for the precise localization of carotid cavernous fistulas during balloon obliteration. *J Neurosurg* **1978**;49:146-149
10. Berenstein A, Kricheff I. Balloon catheters for investigating carotid cavernous fistulas. *Radiology* **1979**;132:762-764