



Discover Generics

Cost-Effective CT & MRI Contrast Agents



FRESENIUS
KABI

WATCH VIDEO

AJNR

Clinical 3T Magnetic Resonance

AJNR Am J Neuroradiol 2008, 29 (8) e72-e73

doi: <https://doi.org/10.3174/ajnr.A0986>

<http://www.ajnr.org/content/29/8/e72>

This information is current as
of June 22, 2025.

Clinical 3T Magnetic Resonance

V.M. Runge, W.R. Nitz, S.H. Schmeets, and S.O. Schoenberg.
New York: Thieme Medical Publishers; 2007, 264 pages, 326 illustrations, \$49.95.

This soft-covered, nearly pocket-sized book is recommended for radiologists, technologists, and imaging managers who are thinking about purchasing a 3T system, are in the process of purchasing a 3T system, or have recently purchased a 3T system. One is able to quickly review the implications of going from 1.5T to 3T with regard to patient safety, and, centered on clinical examples, the authors discuss their experiences on how to optimize image quality throughout the body and varied clinical conditions.

The book is divided into 104 short, pithy chapters. Chapters dealing with MR physics, as well as clinical conditions, have imaging examples that are the cornerstone of the chapter, with the content of the text primarily focused on the imaging examples. The chapters include the following:

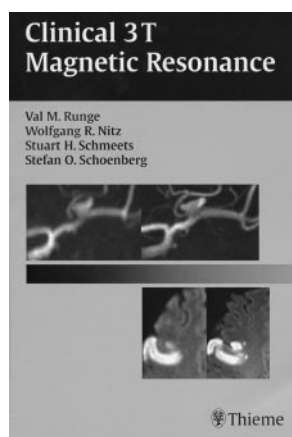
“Basic Principles of MR”; “Components of an MR Scanner”; “SNR and Spatial Resolution”; “SNR and K-Space”; “SNR, Parallel Imaging, and Field Strength”; “CNR and Relaxation Times”; “CNR and Magnetic Susceptibility, CNR, and Dielectric Resonances”; “Torque and Attraction”; “Switching of Magnetic Field Gradients”; “SAR Basics”; “Increased SAR at High Field”; “SAR Guidelines”; “SAR Monitoring and Management”;

“SAR Reduction (mSENSE)”; “SAR Reduction (GRAPPA)”; “SAR Reduction (Hyperechoes)”; “SAR Reduction (SPACE)”; “SAR Reduction (VERSE)”; “Passive Implants; Body Piercing and Tattoos”; “Active Implants Intravascular and Intracavitary Implants”; “Brain: Spatial Resolution”; “Brain: Section Thickness”; “Brain: Screening”; “Brain: Contrast Media, Motion”; “Brain: 3D Time-of-Flight MRA”; “Brain: Ischemia (Part 1)”; “Brain: Ischemia (Part 2)”; “Brain: Ischemia (Part 3)”; “Brain: Ischemia (Part 4)”; “Brain: Infection/Inflammation”; “Brain: Multiple Sclerosis”; “Brain: Hemorrhage”; “Brain: Congenital Malformations”; “Brain: Toxic/Degenerative Disorders”; “Brain: Neoplasia-Introduction”; “Brain: Neoplasia—Screening”; “Brain: Primary Intraaxial Neoplasia”; “Brain: Residual/Recurrent Neoplasia (Part 1)”; “Brain: Residual/Recurrent Neoplasia (Part 2)”; “Brain: Metastases (Part 1)”; “Brain: Metastases (Part 2)”; “Brain: Extra-axial Neoplasia”; “Brain: Pituitary; Head and Neck”; “Brain: Pediatric Imaging”; “Brain: Susceptibility-Weighted Imaging”; “Brain: BOLD”; “Brain: Perfusion”; “Brain: Spectroscopy”; “Brain: Diffusion Tensor Imaging”; “Brain: Arterial Spin La-

beling”; “Spine: Cervical—Introduction”; “Spine: Cervical Cord (Part 1)”; “Spine: Cord (Part 2)”; “Spine: Cervical—Disk Disease”; “Spine: Cervical—Bone, Soft Tissue”; “Spine: Cervical—Canal Compromise”; “Spine: Cervicothoracic Junction”; “Spine: Thoracic—Introduction”; “Spine: Thoracic—Cord”; “Spine: Lumbar—Disk Herniation (Part 1)”; “Spine: Lumbar—Disk Herniation (Part 2)”; “Spine: Lumbar—Postoperative (Part 1)”; “Spine: Lumbar—Postoperative (Part 2)”; “Spine: Lumbar—Intrathecal (Part 1)”; “Spine: Lumbar—Intrathecal (Part 2)”; “Knee: Cartilage”; “Knee: Osteochondral Disease”; “Knee: Cruciate Ligaments”; “Knee: Menisci/Meniscal Ligaments”; “Knee: Collateral Ligament Complexes”; “Wrist; Shoulder: Cardiac Function with CINE SSFP”; “Assessment of Cardiac Morphology”; “Ischemic Heart Disease”; “Assessment of Cardiomyopathy”; “Breast”; “Liver: Spatial Resolution”; “Liver: Imaging Sequences”; “Liver: Ultra-Small Metastases”; “Liver: SPIO”; “Liver: MRCP (Part 1)”; “Liver: MRCP (Part 2)”; “Kidney: (Part 1)”; “Kidney: (Part 2)”; “Kidney: Arterial Spin Labeling”; “Pelvis”; “Prostate: Introduction”; “Prostate: Anatomy”; “Prostate: Contrast-Enhanced Imaging”; “Prostate: Dynamic Contrast-Enhanced Imaging”; “Prostate: Spectroscopy”; “Carotid CE-MRA (Spatial Resolution)”; “Carotid CE-MRA (Time-Resolved)”; “Abdominal Aortic CE-MRA (Resolution)”; “Abdominal Aortic CE-MRA (Aneurysm)”; “Renal CE-MRA (Fibromuscular Dysplasia)”; “Peripheral CE-MRA (Part 1)”; “Peripheral CE-MRA (Part 2)”; and “Peripheral CE-MRA (Part 3).”

There are several limitations of the book. Although this book is not intended to be an all-inclusive account of clinical 3T imaging, one who is experienced in the use of a 3T magnet and interpretation of 3T images will find the book of limited usefulness. There are incomplete descriptions of imaging techniques, a lack of detail in the description of how to optimize imaging sequences, lack of scientific proof (although primarily a problem with the state of the scientific literature at this time) without scientific references, and a lack of correlative examples between 1.5T and 3T. There is an example of a few millimeters of hydromyelia of the cervical cord that is stated to be an abnormality that probably would not have been depicted at 1.5T. The author does not mention that, with improved spatial resolution, it is not uncommon to visualize the central canal at 3T and that it is not uncommon to visualize the central canal in normal patients. The book has a broad scope but has limited depth.

The images are of high quality. The physics chapters are succinct and to the point, easy to understand, and of clinical relevance. The clinically oriented chapters stress how to take advantage of the improved signal-to-noise ratio and spatial resolution, deal with increased specific absorption rate with the adjustment of imaging protocols, and discuss techniques for artifact correction. For example, in the chapter on the thoracic cord, the authors state that, “In the T1-weighted imaging of the cord at 3T, studies have demonstrated that CNR (for spinal cord versus CSF) with T1 FLAIR is superior to T1 FSE, offering more than a three-fold improvement. As a result, for imaging of the cord, T1 FLAIR is recommended. The inversion time with T1 FLAIR can be calculated to optimize CNR, with scan parameters of



TR/TE/TI = 3500/12/1200 providing excellent cord- CSF contrast and to a first approximation an optimized scan.”

In conclusion, this book offers a solid, easily understandable introduction to the world of 3T imaging that can be read

in a few hours. This source is a useful tool for radiologists, technologists, and managers.

DOI 10.3174/ajnr.A0986