



Providing Choice & Value
Generic CT and MRI Contrast Agents

**FRESENIUS
KABI**

CONTACT REP

AJNR

Aberrant Middle Turbinate Masquerading as a Nasopharyngeal Mass

P.H. Lee, A.S. Lee and R.A. Bhadelia

AJNR Am J Neuroradiol 2008, 29 (8) 1564-1565

doi: <https://doi.org/10.3174/ajnr.A1116>

<http://www.ajnr.org/content/29/8/1564>

This information is current as
of July 31, 2025.

CASE REPORT

P.H. Lee
A.S. Lee
R.A. Bhadelia

Aberrant Middle Turbinate Masquerading as a Nasopharyngeal Mass

SUMMARY: We present a unique variant of the middle turbinate that extends posteriorly through the choana to wrap around the posterior free edge of the nasal septum. The embryology and anatomy of the lateral nasal wall and the nasal septum are reviewed.

The anatomy of the nasal cavity and the lateral nasal wall is complex, with many variants. We present a unique variant of the middle turbinate that was initially thought clinically to be a mass.

Case Report

A 43-year-old man presented with approximately 2½ weeks' history of bilateral epistaxes. The medical history was significant only for seasonal rhinitis. There was no history of any facial traumatic injury. On examination of the nasal cavity, dry mucous membranes along the anterior nasal septum bilaterally were noted. Nasal endoscopic examination revealed a well-circumscribed pedunculated mass apparently extending from the left posterior nasal septum. No blood or blood clots were associated with this lesion. A CT scan was performed for further evaluation.

CT examination demonstrated that the right middle turbinate assumed an unusual configuration and location. The turbinate was straightened anteriorly (Fig 1), more posteriorly located than the contralateral normal side, curved posteromedially around the posterior free edge of the nasal septum, and extended into the left nasopharynx (Figs 2,3). It was determined to be a middle turbinate in an unusual location because it had a typical bony attachment to the lateral nasal wall, and there was no normal middle turbinate on that side. No other lesions were identified.

The epistaxis was thought to be from the dry mucous membranes. Because the aberrant middle turbinate was considered to be an incidental finding, no treatment was pursued.

Discussion

There are many anatomic variations of the middle turbinate including paradoxical curvature, pneumatization (concha bullosa and lamella concha), and secondary or accessory middle turbinates.¹ A secondary middle turbinate is described as a bony projection from the lateral nasal wall that has a similar appearance to a normally present middle turbinate. This is thought to be either an incomplete anterior wall of the ethmoid bulla or a supernumerary turbinate.² An accessory middle turbinate is described as an uncinat process that is medially bent with an anterior fold.³ However, to the best of our knowledge, an aberrantly configured middle turbinate, as described in this case report, has not been reported previously.

The embryology and anatomy of the paranasal sinuses and the other nasal structures are complex.^{4,5} Three facial projec-

tions develop in the embryo—the frontonasal, maxillary, and mandibular processes—that join to form the central face. Arising from the frontonasal process is the nasal capsule, which, in turn, forms the nasal cartilaginous structures. The nasal capsule divides into the mesethmoid and the ectethmoid. The mesethmoid joins with the tectoseptal extension of the maxillary process to form the nasal septum. The ectethmoid forms the lateral nasal wall, from which multiple ridges arise and coalesce to 3 or 4 ridges. The inferior turbinate is formed from the maxilloturbinal ridge and is considered to be an independent bone. The other turbinates are part of the ethmoid bone, and the middle turbinate forms from the first ethmoturbinal ridge, the superior turbinate from the second ethmoturbinal ridge, and the supreme turbinate (variably present) from the third ethmoturbinal ridge.

The supporting bony attachments for the free-hanging portions of the turbinates are called lamellae.⁶ Five lamellae start anteriorly: 1) the lamella of the uncinat process; 2) the lamella of the ethmoid bulla; 3) the basal lamella of the middle turbinate; 4) the basal lamella of the superior turbinate; and 5) the lamella of the supreme turbinate, if present.

The middle turbinate is a part of the ethmoid bone. Its anterior portion inserts into the ascending process of the maxilla and the posteromedial margin of the agger nasi cells. Its superior insertion is to the lateral edge of the cribriform plate. The posterior portion is oriented horizontally and attaches to the ethmoid crest of the perpendicular plate of the palatine bone.

The nasal septum is composed anteriorly by the quadrilateral cartilage, posterosuperiorly by the perpendicular plate of the ethmoid bone, and posteroinferiorly by the vomer. The

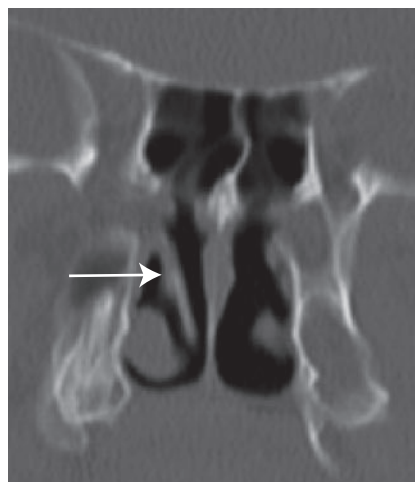


Fig 1. A coronal CT image showing the straightened right middle turbinate (arrow).

Received December 24, 2007; accepted after revision February 6, 2008.

From the Beth Israel Deaconess Medical Center (P.H.L., R.A.B.), Boston, Mass; and Tufts New England Medical Center (A.S.L.), Boston, Mass.

Please address correspondence to Peter H. Lee, MD, Beth Israel Deaconess Medical Center, 330 Brookline Ave, WCCB-90, Boston, MA 02215; e-mail: phlee@caregroup.harvard.edu

DOI 10.3174/ajnr.A1116

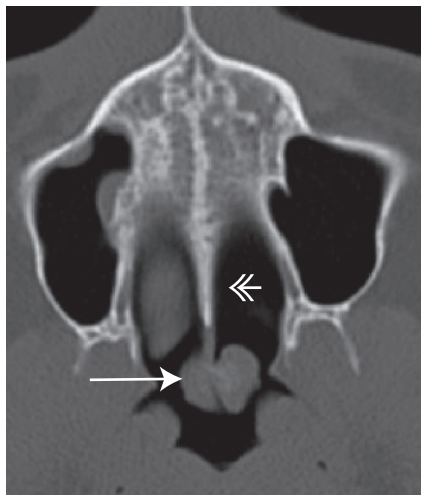


Fig 2. Axial CT image showing the right middle turbinate (arrow) extending through the right choana to wrap around the posterior free edge of the nasal septum (double-headed arrow).

vomer articulates inferiorly with the nasal crest of the maxillae and the palatine bones. The developments of the lateral nasal wall and the nasal septum occur concurrently, but the exact timing can be variable.⁷

The case of our patient is unique in that the right middle turbinate does not have the usual curvature, extends posteriorly through the right choana, and wraps around the posterior free edge of the nasal septum to cross over to the contralateral nasopharynx. This finding is likely not a posttraumatic deformity because there is no history of a traumatic injury and no evidence of deformity or fractures of the adjacent bones. We speculate that the anatomic features of this patient may have developed from the middle turbinate having a medial course or a medial projection that extended posterior to the developing nasal septum and therefore was subsequently pulled to its current configuration as the nasal septum grew.

To the best of our knowledge, a variant middle turbinate as described in this case report has not been described previously.

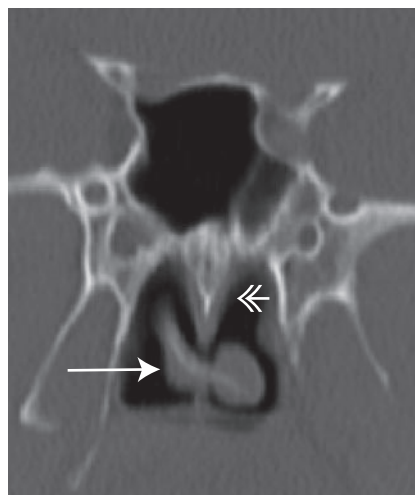


Fig 3. Coronal CT image showing the right middle turbinate (arrow) extending through the right choana to wrap around the posterior free edge of the nasal septum (double-headed arrow).

It is important to document anatomic variations in this region because they may initially be mistaken for masses, as in the case of this patient, and may affect surgical planning.

References

1. Laine FJ, Smoker WR. **The ostiomeatal unit and endoscopic surgery: anatomy, variations, and imaging findings in inflammatory diseases.** *AJR Am J Roentgenol* 1992;159:849–57
2. Apaydin FD, Duce MN, Yildiz A, et al. **Inferomedially projecting pneumatized secondary middle turbinate.** *Eur J Radiol* 2002;43:42–44
3. Aksungur EH, Biççakçı K, Inal M, et al. **CT demonstration of accessory nasal turbinates: secondary middle turbinate and bifid inferior turbinate.** *Eur J Radiol* 1999;31:174–76
4. Arredondo de Arreola G, López Serna N, de Hoyos Parra R, et al. **Morphogenesis of the lateral nasal wall from 6 to 36 weeks.** *Otolaryngol Head Neck Surg* 1996;114:54–60
5. Rice D. **Embryology.** In: Donald PJ, Gluckman JL, Rice DH, ed. *The Sinuses.* New York: Raven Press;1995:15–24
6. Stammberger HR, Kennedy DW. **Paranasal sinuses: anatomic terminology and nomenclature.** The Anatomic Terminology Group. *Ann Otol Rhinol Laryngol Suppl* 1995;167:7–16
7. Levine HW, Clemente MP. *Sinus Surgery: Endoscopic and Microscopic Approaches.* New York: Thieme; 2005