



Discover Generics

Cost-Effective CT & MRI Contrast Agents



FRESENIUS
KABI

WATCH VIDEO

AJNR

Fenestrations of the Anterior Communicating Artery: Incidence on 3D Angiography and Relationship to Aneurysms

A.N. de Gast, W.J. van Rooij and M. Sluzewski

AJNR Am J Neuroradiol 2008, 29 (2) 296-298

doi: <https://doi.org/10.3174/ajnr.A0807>

<http://www.ajnr.org/content/29/2/296>

This information is current as
of June 9, 2025.

ORIGINAL RESEARCH

A.N. de Gast
W.J. van Rooij
M. Sluzewski

Fenestrations of the Anterior Communicating Artery: Incidence on 3D Angiography and Relationship to Aneurysms

BACKGROUND AND PURPOSE: Demonstration of fenestrations of the anterior communicating artery (AcomA) with conventional digital subtraction angiography is very uncommon. The purpose of this study was to assess the incidence of visible fenestrations of the AcomA on 3D rotational angiography (3DRA) and to evaluate the relationship between fenestrations of the AcomA and aneurysms of the AcomA.

MATERIALS AND METHODS: We systematically reviewed 305 datasets of 3DRA of the internal carotid artery in 305 patients with aneurysms of the anterior circulation on a dedicated workstation for the presence of fenestrations on the AcomA.

RESULTS: In 78 of 305 3DRAs, only the ipsilateral A2 segment was visible; thus, the AcomA could not be evaluated. Of the remaining 227 3DRAs, a fenestration of the AcomA was present in 12 (5.3%; 95% CI, 3.0%–9.1%). Of 12 fenestrations of the AcomA, 10 (83%) were associated with 1 or more aneurysms of the AcomA. Of 305 patients, 133 had an aneurysm on the AcomA, and in 127 of these, the AcomA was visible. Of 127 AcomA aneurysms with a visible AcomA, 10 were associated with fenestration, which accounted for an incidence of AcomA fenestrations with AcomA aneurysms of 7.9% (95% CI, 4.2%–14.0%). The proportion of fenestrations of the AcomA with aneurysms of the AcomA was 4.4% (10/227), and the proportion of AcomA fenestration with an aneurysm at another location was 0.9% (2/227). This difference was statistically significant ($P = .040$). Even in retrospect, 11 of 12 fenestrations were not visible on 2D DSA images.

CONCLUSION: In selected patients with aneurysms of the anterior circulation, fenestrations in the AcomA were found with 3DRA in 5.3% of datasets. Most fenestrations were associated with 1 or more aneurysms of the AcomA.

The anterior communicating artery (AcomA) is a small connecting artery between the paired anterior cerebral arteries and provides an important anastomotic channel for collateral circulation through the circle of Willis. In the embryologic stage, the AcomA develops from a multichanneled vascular network that coalesces to a variable degree by the time of birth.¹ A wide variety exists in the anatomy of the AcomA complex. A common variation is aplasia or hypoplasia of one A1 segment. In this variation, the other A1 continues as two A2 segments and an AcomA can hardly be defined.² In large autopsies and surgical series, single, double, or even triple fenestrations of the AcomA are reported in approximately 40% of specimens.^{3–5} Despite this frequent occurrence in anatomic studies, angiographic demonstration of fenestrations of the AcomA is very uncommon. With recent advances in 3D rotational angiography (3DRA), high-resolution images are obtained that can be freely rotated. In this study, we systematically reviewed 305 datasets of 3DRA of the internal carotid artery in 305 patients with aneurysms of the anterior circulation to assess the incidence of visible AcomA fenestrations and to evaluate the relationship between AcomA fenestrations and AcomA aneurysms.

Patients and Methods

3D Rotational Angiography

In our practice, in all patients with suspected intracranial aneurysms in whom treatment is considered, an intra-arterial digital subtraction angiography (IA-DSA) is performed on all cerebral vessels. When an aneurysm is apparent or suspected on IA-DSA, additional 3DRA is performed on the vessel harboring the aneurysm to evaluate its anatomy and to determine the type of treatment (coiling, surgery, or occlusion of the parent vessel). In patients with aneurysms allocated to coiling, 3DRA is repeated under general anesthesia immediately before coiling to find out the best working projection.

We performed angiographic imaging on a biplane neuroangiographic unit (Integris BN 3000 Neuro; Philips Medical Systems, Best, the Netherlands). 3DRA was performed with an 8-second 180° rotational run with acquisition of 200 images and with an injection of 3 to 4 mL of contrast material per second through a large-lumen 6F guiding catheter in the internal carotid artery. On a dedicated workstation, 3D reconstructions can be made in a matrix of maximum 512³. All raw 3DRA datasets are stored on the hard drive of the workstation or on a compact disc. Raw datasets stored on compact discs can be reloaded in the workstation for real-time evaluation.

Patients

Between March 2004 and May 2007, 305 patients with intracranial aneurysms of the anterior circulation had 3DRA of one of the carotid arteries. All of these 305 3D datasets were reevaluated on the workstation for the presence of fenestrations and aneurysms on the AcomA.

Statistical Analysis

In patients with a visible AcomA, we compared the proportion of fenestrations of the AcomA associated with an aneurysm of the

Received June 21, 2007; accepted after revision July 23.

From the Department of Radiology, St. Elisabeth Ziekenhuis, Tilburg, the Netherlands.

Please address correspondence to Willem Jan van Rooij MD, PhD, Department of Radiology, St. Elisabeth Ziekenhuis, Hilvarenbeekseweg 60, 5022 GC Tilburg, the Netherlands; e-mail: radiol@knmg.nl

DOI 10.3174/ajnr.A0807

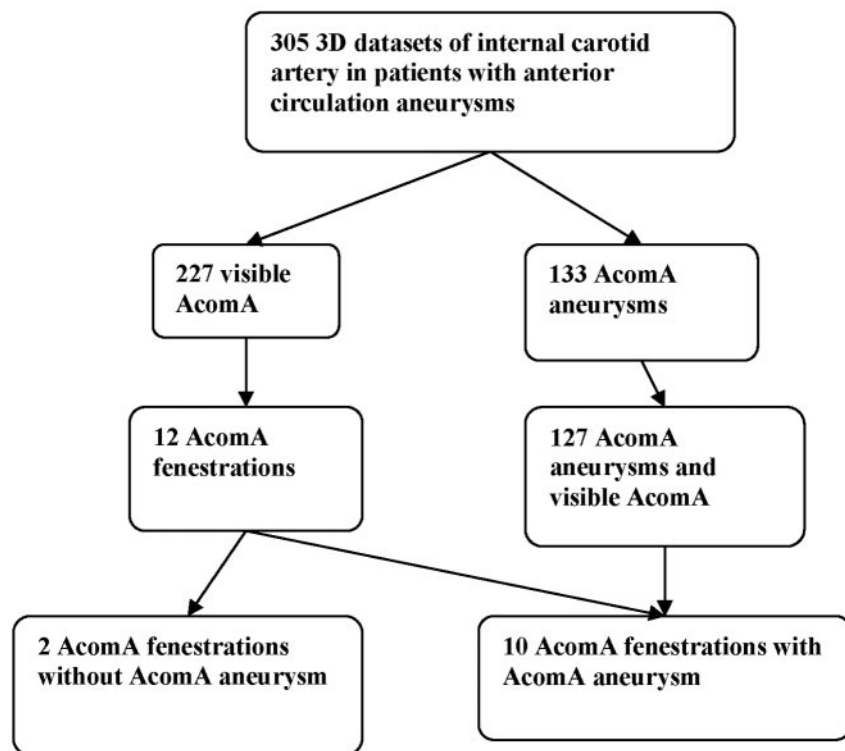


Fig 1. Diagram showing relationship of aneurysms of the AcomA and fenestrations of the AcomA in 305 patients with aneurysms of the anterior circulation.

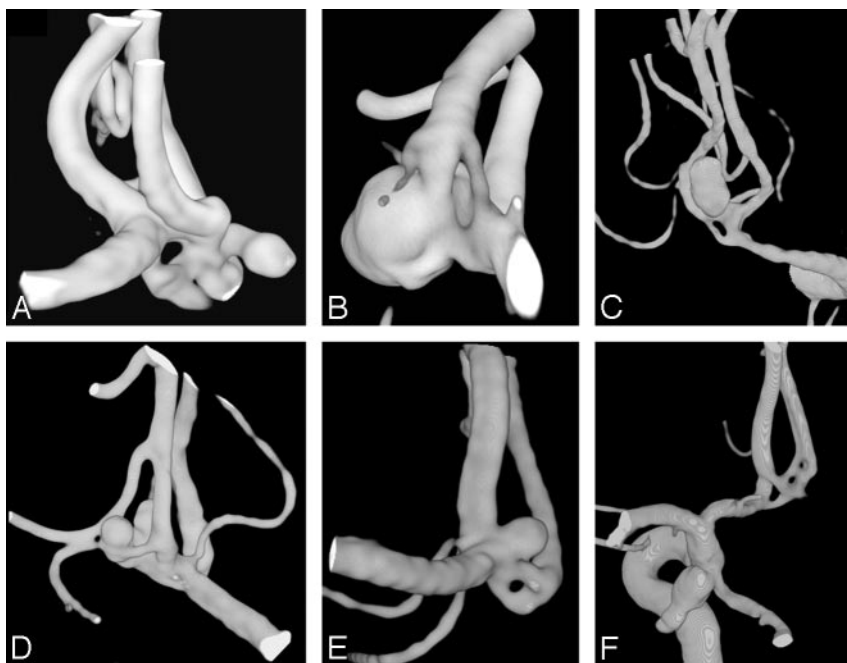


Fig 2. A–F, Examples of fenestrations of the AcomA. A, Fenestration with three A2s and three small aneurysms. B,C, Simple fenestration with aneurysm. D, Multiple fenestrations with 2 aneurysms. E, Simple fenestration with an aneurysm. F, Multiple fenestrations with an aneurysm of the posterior communicating artery.

AcomA with the proportion of fenestrations of the AcomA associated with an aneurysm at another location, using the χ^2 test. In patients with a visible AcomA, we compared the proportion of AcomA aneurysms with AcomA fenestrations with the proportion of aneurysms at other locations with AcomA fenestrations, using the χ^2 test.

Results

Results are summarized in Fig 1. In 78 of 305 3DRAs, only the ipsilateral A2 segment was visible; thus, the AcomA could not be evaluated (an AcomA aneurysm without a visible AcomA was defined as an aneurysm on the transition from A1 to A2).

Of the remaining 227 3DRAs with good visibility of the AcomA, a fenestration was present in 12 (5.3%; 95% CI, 3.0–9.1%) (Fig 2). Of 12 fenestrations of the AcomA, 10 (83%) were associated with 1 or more aneurysms of the AcomA. Of 305 patients, 133 had an aneurysm on the AcomA, and in 127 of these, the AcomA was visible. Of 127 AcomA aneurysms with a visible AcomA, 10 were associated with a fenestration accounting for an incidence of AcomA fenestrations with AcomA aneurysms of 7.9% (95% CI, 4.2–14.0%). Even in retrospect, 11 of 12 fenestrations were not visible on 2D DSA images.

The proportion of AcomA fenestration with an AcomA aneurysm was 4.4% (10/227), and the proportion of AcomA fenestration with an aneurysm at another location was 0.9% (2/227). This difference was statistically significant ($P = .040$).

The proportion of AcomA aneurysms associated with fenestration was 7.9% (10/127), and the proportion of aneurysms at other locations associated with fenestration of the AcomA was 2.0% (2/100). This difference was not statistically significant ($P = .096$).

Discussion

In our study, we found that fenestrations of the AcomA were discernible in 12 (5.3%) of 227 3DRA datasets with a visible AcomA. Of these 12 fenestrations, 10 were associated with 1 or more aneurysms of the AcomA. In a reverse fashion, of 127 aneurysms of the AcomA with a visible AcomA, 10 (7.9%) were associated with fenestration. There is a wide variety in fenestrations of the AcomA from simple duplication (Fig 2C) to stepladder-like configurations (Fig 2F).

Our study is the first with systematic imaging assessment of fenestrations of the AcomA. Although AcomA fenestrations were significantly more often associated with AcomA aneurysms than with aneurysms at other locations in our patient group, a definite relationship cannot be established. First, only a small proportion of expected fenestrations of the AcomA (40% in anatomic studies) are visible on 3DRA. Second, no 3DRA data are available from patients without aneurysms.

The introduction of 3DRA has greatly improved the imaging quality of cerebral vessels and plays an important role in treatment planning and measurements of intracranial aneurysms.⁶⁻⁹ This improvement of imaging quality is illustrated by the fact that, in retrospect, only 1 of 12 fenestrations of the AcomA was visible on 2D IA-DSA. In a review by Sanders et al¹⁰ of 5190 cerebral angiograms, 37 fenestrations were found, but none of these were on the AcomA.

Because the frequency of fenestrations on the AcomA in large surgical and autopsy series is approximately 40%, a substantial proportion of fenestrations remain invisible on 3DRA with current available resolution. This is not surprising because in many fenestrations, bridging arteries are too thin (0.1–0.3 mm) to become perceptible on 3DRA.³

In anatomic studies, important perforating arteries supplying the optic chiasm, infundibulum, subcallosal area, and pre-optic area of the hypothalamus may arise from the AcomA, also from fenestrated AcomAs.^{3,4} This possibility of the presence of perforators implies that with coiling of aneurysms on a fenestrated, double, or triple AcomA, sparing the patency of all channels of the AcomA should be recommended, despite the fact that occlusion of the channel harboring the aneurysm would have no consequences for blood flow to the A2 and A1 segments. In some patients with an aneurysm on a fenestrated AcomA, the anatomy is quite complex (Figs 2A and 2D), and accurate 3D images are helpful in recognizing anatomic landmarks during surgery and general appreciation of anatomy.

Conclusion

In selected patients with aneurysms of the anterior circulation, fenestrations of the AcomA were found with 3DRA in 5.3% of datasets. Most fenestrations were associated with 1 or more aneurysms of the AcomA.

References

1. Padgett DH. **The circle of Willis. Its embryology and anatomy.** In: Dandy WE. *Intracranial Aneurysms*. Ithaca, NY: Comstock; 1944:67–90
2. Suzuki J, Ohara H. **Clinicopathological study of cerebral aneurysms. Origin, rupture, repair and growth.** *J Neurosurg* 1978;48:505–14
3. Yaçsargil MG. *Microneurosurgery*. Vol. 1. Stuttgart, Germany: Georg Thieme Verlag; 1984:99–107
4. Perlmutter D, Rhoton AL Jr. **Microsurgical anatomy of the anterior cerebral-anterior communicating-recurrent artery complex.** *J Neurosurg* 1976;45:259–72
5. Busse O. **Aneurysmen und Bildungsfehler der Arteri communicans anterior.** *Virchows Arch Pathol Anat* 1921;229:178–89
6. Hirai T, Korogi Y, Suginozaka K, et al. **Clinical usefulness of unsubtracted 3D digital angiography compared with rotational digital angiography in the pre-treatment evaluation of intracranial aneurysms.** *AJNR Am J Neuroradiol* 2003;24:1067–74
7. Beck J, Rohde S, Berkefeld J, et al. **Size and location of ruptured and unruptured intracranial aneurysms measured by 3-dimensional rotational angiography.** *Surg Neurol* 2006;65:18–27; discussion 25–7
8. Sugahara T, Korogi Y, Nakashima K, et al. **Comparison of 2D and 3D digital subtraction angiography in evaluation of intracranial aneurysms.** *AJNR Am J Neuroradiol* 2002;23:1545–52
9. Hochmuth A, Spetzger U, Schumacher M. **Comparison of three-dimensional rotational angiography with digital subtraction angiography in the assessment of ruptured cerebral aneurysms.** *AJNR Am J Neuroradiol* 2002;23:1199–205
10. Sanders WP, Sorek PA, Mehta BA. **Fenestration of intracranial arteries with special attention to associated aneurysms and other anomalies.** *AJNR Am J Neuroradiol* 1993;14:675–80