



Providing Choice & Value

Generic CT and MRI Contrast Agents



CONTACT REP

AJNR

**A Rare Complication of Carotid Artery
Stenting: Displacement of Marker Ring
Causing Locking of Stent and Incomplete
Stent Expansion**

E. Akgul, E.H. Aksungur, K. Korur, K. Aikimbaev and H. Yaliniz

This information is current as
of July 29, 2025.

AJNR Am J Neuroradiol 2007, 28 (7) 1403-1404

doi: <https://doi.org/10.3174/ajnr.A0562>

<http://www.ajnr.org/content/28/7/1403>

CASE REPORT

E. Akgul
E.H. Aksungur
K. Korur
K. Aikimbaev
H. Yaliniz

A Rare Complication of Carotid Artery Stenting: Displacement of Marker Ring Causing Locking of Stent and Incomplete Stent Expansion

SUMMARY: We present a rare case of a complication of placement of a carotid artery stent represented by partial opening of a carotid Wallstent caused by displacement of its metal ring marker, which thus hindered complete expansion of the stent. An intraluminally locked carotid stent necessitated referral of the patient for urgent carotid endarterectomy. A possible reason of this unusual complication can be a manufacturing defect, which, to our knowledge, was not documented previously in open public data bases or on the Internet.

Carotid artery stent (CAS) placement is a well-established method for revascularization of the obstructed lumen in patients with carotid artery disease. Complications may occur during the procedure and generally are presented by neurologic symptoms as a result of microembolism or thrombosis, which can be prevented by the use of a protective filter. Less common complications during CAS placement are hemodynamic conditions such as bradycardia and hypotension, which are easily treatable.¹⁻³ Mechanical complications such as spasm or dissection are seen less and less frequently with personal experience and innovations in equipment. Complications caused by unlucky mechanical accidents during stent implantation such as incomplete opening are unusual and therefore can be a reason for unpredictable outcomes of CAS placement. We present a rare case of a CAS complication with incomplete opening of a carotid Wallstent (Boston Scientific, Natick, Mass) caused by displacement of its metal ring marker, which hindered the complete expansion of the stent and required urgent surgical intervention.

Case Report

A 71-year-old woman with a history of transient ischemic attack and right internal carotid artery stenosis of more than 70% in the proximal portion previously diagnosed on CT and MR angiography was referred to our hospital for implantation of a carotid stent. CAS with a carotid Wallstent Monorail⁴ with a cerebral protection filter (EPI Filter Wire; Boston Scientific) was planned.

The patient had received therapy with antiaggregant medications: aspirin 100 mg/day and clopidogrel 75 mg/day for 1 week before stent implantation. A 6F shuttle introducer was placed into the right common carotid artery by the femoral approach, and preprocedure control angiograms were obtained. A cerebral protection filter was placed distally to the obstructed internal carotid artery, and then self-expandable Wallstent (7 × 50 mm) deployment was performed. During deployment, unexpected slipping of the distal ring of the metal marker over the shaft of the stent was observed. The slipped ring at one fourth of the proximal end of the stent hindered the complete expansion of the stent. The shaft of the stent and the protection filter could not be pulled back because the metal ring locked over the stent

(Fig 1). Attempts to rescue the fixed stent and slipped metal ring were unsuccessful, and the patient was rushed to the operating room. During endarterectomy, the stent, stent shaft, and protection filter were removed without any surgical complication (Fig 2). Four days after the operation, the patient was discharged from the hospital without any neurologic deficit.

Discussion

Periprocedural complications of CAS placement generally are hemodynamic, thromboembolic, or mechanical. Hemodynamic changes such as bradycardia, hypotension, and asystole are often seen but are easily treatable complications. Wholey et al¹ reported bradycardia in 10% of patients during pre-stent dilation. In our unpublished series, we observed bradycardia in almost 50% of patients during in-stent dilation and asystole in about 2% of patients. Park et al⁵ revealed development of periprocedural hypotension in 23% of patients. The most important complications of CAS are related to distal embolization from a crushing of atheromatous plaque that occurs before or after dilation. Although cerebral protection devices reduce this kind of embolism, they can cause some mechanical or iatrogenic complications such as vasospasm and dissection of the vessel.^{2,6-8} In cases of serious vasospasm, minor stroke can be seen.⁹ However “mechanical” complications such as incomplete expansion of the stent caused by displacement of a marker ring with intraluminal locking of the stent are unusual.

The low-profile and self-expandable carotid Wallstent Monorail (6–10 mm in diameter and 30–50 mm in length), which has been used extensively by our interventional team for the last 3 years, is composed of a biomedical alloy. The constructive feature of such products is that during deployment, it foreshortens according to the diameter of the target vessel, and a constant radial force allows embedding of the stent into the lumen and adapting to the variable diameter of the vessel across the bifurcation. The main disadvantage is that the Wallstent straightens the vessel more than the expanded open-cell nitinol stent. Two metallic rings on the stent, which are squeezed over a plastic shaft, indicate the proximal and distal ends of the Wallstent. After deployment, the stent carrier shaft must be pulled back to release the stent.^{4,10,11} In our case, the distal metallic ring marker of the stent carrier shaft slipped over the stent before deployment was accomplished. During deployment, although we pulled back the sheath of the shaft fully, we realized that the stent did not open and the distal metallic marker, which was squeezed around the distal end of the plastic shaft, was over the proximal one fourth of the stent,

Received November 13, 2006; accepted after revision December 12.

From the Departments of Radiology (E.A., E.H.A., K.K., K.A.) and Cardiovascular Surgery (H.Y.), Faculty of Medicine, Cukurova University, Adana, Turkey.

Address correspondence to Erol Akgul, Cukurova Universitesi, Tip Fakultesi, Radyoloji AD, 01330, Adana, Turkey; e-mail: akguler@cu.edu.tr

DOI 10.3174/ajnr.A0562

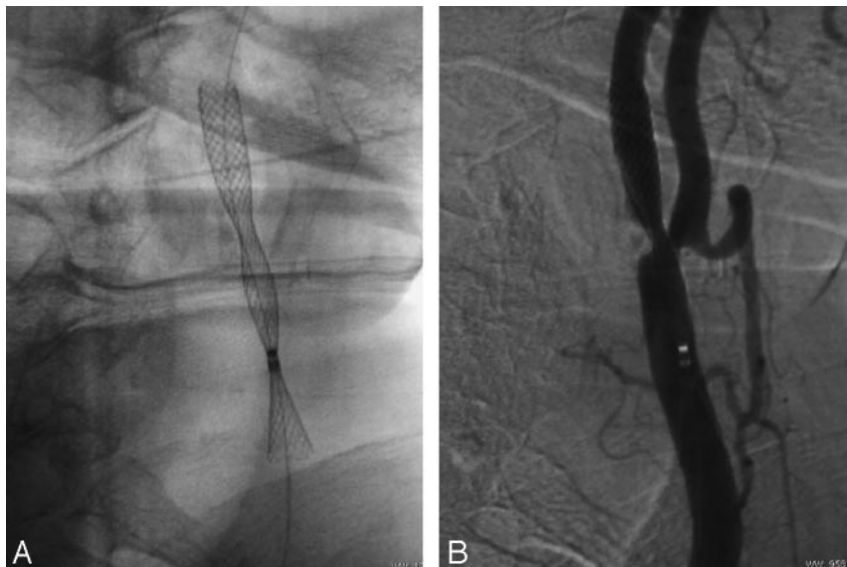


Fig 1. After deployment of the Wallstent, a distal metallic ring marker, causing incomplete expansion, is seen on the stent (A). Digital subtraction angiography of the carotid artery with the Wallstent is shown (B).

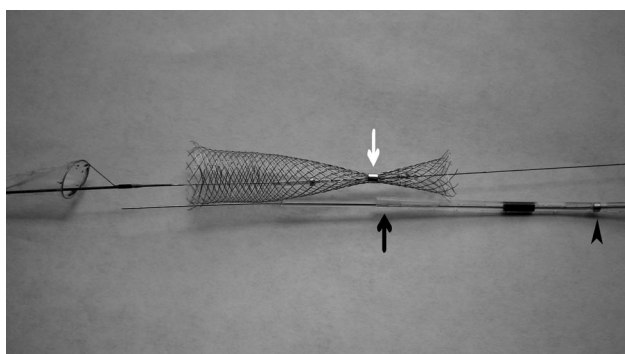


Fig 2. The stent, shaft, and filter are seen after surgical removal of the devices. The distal metallic marker (white arrow), which must be on the distal end of the shaft (black arrow), is on the stent and prevents the complete expansion of the stent. Arrowhead shows the proximal metallic marker on the shaft.

hindering the complete expansion of the stent. To our knowledge, this unusual complication has not been documented previously in an open public data base or on the Internet. The distal metallic marker slipped, possibly because it was not squeezed sufficiently during production.

In conclusion, the distal metallic ring marker of the carotid Wallstent displacement hindered the complete expansion of the stent during CAS placement. This complication can occur and can necessitate referral of the patient for an urgent endarterectomy. Informing the surgical team before CAS for possi-

ble complications requiring urgent endarterectomy may decrease mortality.

References

1. Wholey MH, Wholey MH, Jarmolowski CR, et al. **Endovascular stents for carotid artery occlusive disease.** *J Endovasc Surg* 1997;4:326–38
2. Sztrihai LK, Voros E, Sas K, et al. **Favorable early outcome of carotid artery stenting without protection devices.** *Stroke* 2004;35:2862–66
3. Mathew B, Bhatia V, Francis L. **Nonsurgical carotid revascularization.** *Cardiol Rev* 2005;13:197–99
4. Carotid Wallstent Monorail, Boston Scientific Corporation. Available at: http://www.bostonscientific.ie/med_specialty/deviceDetail.jsp?task=tskBasicDevice.jsp§ionId=4&relId=3,126,127,128&deviceId=12017&uniqueId=MPDB2219. Accessed October 30, 2006.
5. Park B, Shapiro D, Dahn M, et al. **Carotid artery angioplasty with stenting and postprocedure hypotension.** *Am J Surg* 2005;190:691–95
6. Castriota F, Cremonesi A, Manetti R, et al. **Impact of cerebral protection devices on early outcome of carotid stenting.** *J Endovasc Ther* 2002;9:786–92
7. Liistro F, Di Mario C. **Carotid artery stenting.** *Heart* 2003;89:944–48
8. Kovacic JC, Roy PR, Baron DW, et al. **Percutaneous carotid artery stenting: a strategy in evolution.** *Intern Med J* 2005;35:143–50
9. Cardaioli P, Giordan M, Panfili M, et al. **Complication with an embolic protection device during carotid angioplasty.** *Catheter Cardiovasc Interv* 2004;62:234–36
10. Rabe K, Sievert H. **Carotid artery stenting: state of the art.** *J Interv Cardiol* 2004;17:417–26
11. **Incidence of hypotension reduced with Boston Scientific's carotid WALL-STENT Monorail endoprosthesis as compared with slotted-tube nitinol stents.** *Medical News Today* 11 October 2006. Available at: <http://www.medicalnewstoday.com/medicalnews.php?newsid=53807>. Accessed October 30, 2006.