



## Discover Generics

Cost-Effective CT & MRI Contrast Agents



FRESENIUS  
KABI

WATCH VIDEO

# AJNR

## Lightning Strike: A Rare Cause of Bilateral Ossicular Disruption

C. Offiah, M. Heran and D. Graeb

*AJNR Am J Neuroradiol* 2007, 28 (5) 974-975

<http://www.ajnr.org/content/28/5/974>

This information is current as  
of June 16, 2025.

## CASE REPORT

C. Offiah  
M. Heran  
D. Graeb

# Lightning Strike: A Rare Cause of Bilateral Ossicular Disruption

**SUMMARY:** Otologic injury associated with fatal and nonfatal lightning strikes has been sporadically reported in the literature. The most common acoustic insult is a conductive hearing loss secondary to rupture of the tympanic membrane. Although conjecture has been made of the theoretic possibility of ossicular injury from lightning strike, to our knowledge, none has been demonstrated intraoperatively or postmortem. We report the first documented case of ossicular disruption in a lightning-strike victim.

Lightning strikes can produce an array of clinical symptoms and injuries. Indeed, lightning strikes are seldom fatal; the majority of victims survive with various degrees of injury. There is frequently a delay in the detection of audiovestibular sequelae, the most common of which is tympanic membrane rupture. Review of the literature relating to lightning-induced neuro-otologic injury revealed no documented case of ossicular disruption despite reports of cases of middle ear exploratory surgery and postmortem temporal bone dissection. We present a case of ossicular chain damage in a lightning-injured patient confirmed on imaging and discuss some of the pathophysiology of acoustic injury in such cases.

### Case Report

A 37-year-old man was referred to the emergency department following a witnessed lightning strike while jogging in a park during a thunderstorm. He had been wearing an iPod music player with earphones in place at the time. Witnesses saw the lightning strike a tree, and several birds were found dead at the scene in the vicinity of a large broken branch. The patient was thrown approximately 6–8 feet. The victim possibly had momentary loss of consciousness and was amnesic to the event. Burns were observed on his body, and his left training shoe was burnt and torn apart. The iPod he was wearing exhibited significant electrical damage, and there was evidence of burns in the pattern of the earphone cables extending bilaterally down the anterior aspect of his neck to his chest. The patient was unable to hear spoken words but had slight audition in his left ear to shouting.

Physical examination of the patient revealed 1st- and 2nd-degree burns to the neck, chest and abdomen, and lower limbs; comminuted fractures of the mandible; and fractured teeth. Otologic examination demonstrated bilateral ruptured tympanic membranes with blood in both middle ears and external auditory canals.

High-resolution CT (HRCT) of the petrous temporal bones (Fig 1) was performed. This revealed opacification of the mastoid air cells consistent with hemorrhagic effusions. No fractures of the petrous temporal bones were evident. Bilateral dislocation of the incudomalleal joints was noted. The remainder of both ossicular chains and both otic capsules was normal.

Despite conservative management for 3 months, follow-up otologic and radiologic examinations revealed no change in the patient's status other than resolution of mastoid air cell fluid. The patient had

been referred for ossiculoplasty at the time of submission of this report.

### Discussion

To our knowledge, this is the first documented case of ossicular disruption resulting from a lightning injury. Worldwide, there are an estimated 8 million lightning flashes per day.<sup>1-3</sup> Estimates suggest that there are 300–600 deaths from lightning strikes in the United States each year.<sup>1-4</sup>

The current flow of a lightning strike varies from 100 to 110,000 amperes, with a temperature in excess of 20,000°C generated.<sup>3,5,6</sup>

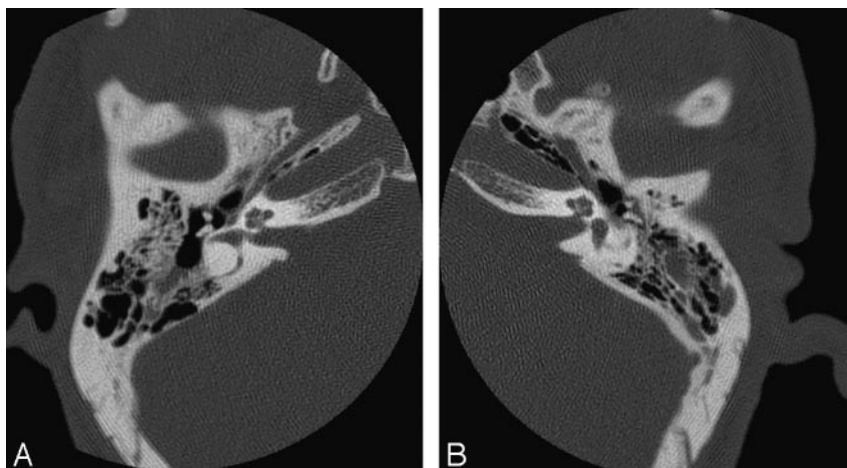
There are 4 mechanisms by which victims of lightning strikes may be injured. The 1st is the direct strike, which occurs when the pathway of the entire energy charge is through the victim. This is potentially the most serious form of strike. The effects are exacerbated if the victim is wearing metal objects near the head such as jewellery or carrying metal objects such as an umbrella or golf clubs and by wet clothing or perspiration. The 2nd mechanism of injury is the side flash, also termed “splash” or “spray” current. This occurs when the energy charge of the lightning strike is conducted from the primary strike area such as a tree or person through the air to the victim standing nearby. It is thought to be the most common mode of lightning-related injury. The 3rd mechanism is the ground strike, sometimes referred to as step voltage or stride potential. Because of the potential difference existing between the legs of a person standing close to the site of a ground strike, current is conducted through the path of least resistance (the ground being greater)—from 1 leg to the other. This is also a common mode of injury seen in lightning-strike victims. The final mechanism is the flash-over phenomenon: Here, most lightning energy flows around the outside of the victim's body. Sweat on the victim's skin or moisture in wet garments acts as the conductor, and the inherent explosive effect of lightning caused by the rapid expansion of the surrounding air as the energy charge travels over the victim may result in blast injuries similar to those sustained in an explosion. Less energy may actually flow through the victim however.<sup>1-7</sup>

The acoustic effects of lightning result from damage to the middle and/or inner ear. In addition, the central audiovestibular system is extremely vulnerable to the effects of lightning.<sup>3,5-7</sup> Postmortem examinations of the temporal bones of lightning victims reveal numerous pathologic findings, including hemorrhagic and purulent effusions of the middle ear and mastoid air cells, rupture of the Reissner membrane, degeneration of the stria vascularis and organ of Corti, edema of the intracanalicular portion of the facial nerve, microfractures

Received June 8, 2006; accepted August 8.

From the Department of Neuroradiology (C.O.), St. Bartholomew and the Royal London Hospitals, West Smithfield, London, UK; and the Department of Neuroradiology (M.H., D.G.), Vancouver General Hospital, Vancouver, BC, Canada.

Please address correspondence to C. Offiah, MD, Department of Neuroradiology, St. Bartholomew and the Royal London Hospitals, West Smithfield, London, UK, EC1A 7BE; e-mail: curtisoffiah@yahoo.co.uk



**Fig 1.** A and B, HRCT of petrous temporal bones. Dislocation of the incudomalleal articulation of each ossicular chain is demonstrated. The remainder of the ossicular chain continuity was maintained—specifically the congruity of the stapes footplate with the oval window was intact. Note the opacification of the mastoid air cells as well as in the region of the aditus ad antrum of the right middle ear, consistent with hemorrhagic effusions. No fractures of the petrous temporal bones were present.

of the otic capsule, and inner ear hemorrhage.<sup>3,5-10</sup> However, although temporary sensorineural hearing loss is frequent in victims, the most common otologic manifestation is rupture of the tympanic membrane, often with an associated conductive hearing loss.<sup>3,5-10</sup> More than 50% of lightning victims have ruptured tympanic membranes.

To our knowledge, there have been no previous recorded reports of lightning-induced ossicular chain disruption in the literature, even in cases in which tympanoplasty with middle ear exploration was performed secondary to large tympanic membrane perforations or temporal bone sections were reviewed postmortem. Middle ear exploration is not routinely performed in victims of lightning injury because the most common acoustic injury of tympanic membrane rupture has a spontaneous healing rate of more than 85% with conservative management.<sup>3</sup>

The pathogenesis of the middle ear otologic injuries remains contested. One mechanism proposed is the cylindric shock wave, which expands from the lightning bolt with enough force to rupture the tympanic membrane and can be transmitted to the inner ear. The force of impact of the sonic shock wave is directly proportional to the distance of the ear from the axis of the lightning bolt. This property of lightning can occur with direct or indirect lightning strikes.<sup>5-10</sup> However, it has proved difficult to substantiate this cylindric shock wave theory with no documented evidence of ossicular disruption in examined victims, despite evidence of tympanic membrane rupture. Our case report provides imaging evidence to support this theory. Furthermore, 3 reports were identified in our literature review of victims who sustained otologic injury (ruptured tympanic membranes) while conversing on the telephone during lightning strikes.<sup>6,9,11</sup> In a similar vein, the patient in our case report had the earphones of his iPod music player in place at the time of the lightning strike, and it is conceivable that these acted as the propagator for the lightning-induced cylindric shock wave that ruptured

his tympanic membranes and caused bilateral ossicular disruption.

### Conclusion

Survival from lightning strike is far more frequent than fatality. However, victims commonly sustain a number of organ-system injuries, including neuro-otologic injury, the most common form of which is rupture of the tympanic membrane. We have demonstrated, with imaging evidence, a case of bilateral ossicular dislocation as well as a cautionary tale of the danger of wearing earphones when caught outdoors during a thunderstorm.

In addition, it may be that HRCT of the petrous temporal bones should be implemented in the management protocol of the subset of patients who demonstrate persisting conductive hearing loss despite healed tympanic membrane perforation following conservative treatment as well as those in whom there is persistent clear otorrhea.

### References

1. Elsom DM. Deaths and injuries caused by lightning in the United Kingdom: analyses of two databases. *Atmospheric Research* 2001;56:325-34
2. Cwinn AA, Cantrill SV. Lightning injuries. *J Emerg Med* 1985;2:379-88
3. Gluncic I, Roje Z, Gluncic V, et al. Ear injuries caused by lightning: report of 18 cases. *J Laryngol Otol* 2001;115:4-8
4. Browne BJ, Gaasch WR. Electrical injuries and lightning. *Emerg Med Clin North Am* 1992;10:211-29
5. Wright JW, Silk KL. Acoustic and vestibular defects in lightning survivors. *Laryngoscope* 1974;84:1378-87
6. Soni UK, Mistry B, Mallya SV, et al. Acoustic effects of lightning. *Auris Nasus Larynx* 1993;20:285-89
7. Ogren FP, Edmunds AL. Neuro-otologic findings in the lightning-injured patient. *Semin Neurol* 1995;15:256-62
8. Bergstrom LV, Neblett LM, Sando I, et al. The lightning-damaged ear. *Arch Otolaryngol* 1974;100:117-21
9. Kristensen S, Tveteras K. Lightning-induced acoustic rupture of the tympanic membrane: a report of two cases. *J Laryngol Otol* 1985;99:711-13
10. Jones DT, Ogren FP, Roh LH, et al. Lightning and its effects on the auditory system. *Laryngoscope* 1991;101:830-34
11. Weiss KS. Otologic lightning bolts. *Am J Otolaryngol* 1980;1:334-37