



Providing Choice & Value

Generic CT and MRI Contrast Agents



CONTACT REP

AJNR

This information is current as
of July 22, 2025.

Cerebral Proton Magnetic Resonance Spectroscopy in Children with Diabetic Ketoacidosis

S.L. Wootton-Gorges, M.H. Buonocore, N. Kuppermann,
J.P. Marcín, P.D. Barnes, E.K. Neely, J. DiCarlo, T.
McCarthy and N.S. Glaser

AJNR Am J Neuroradiol 2007, 28 (5) 895-899
<http://www.ajnr.org/content/28/5/895>

ORIGINAL
RESEARCH

S.L. Wootton-Gorges
M.H. Buonocore
N. Kuppermann
J.P. Marcin
P.D. Barnes
E.K. Neely
J. DiCarlo
T. McCarthy
N.S. Glaser

Cerebral Proton Magnetic Resonance Spectroscopy in Children with Diabetic Ketoacidosis

BACKGROUND AND PURPOSE: Subclinical cerebral edema occurs in many, if not most, children with diabetic ketoacidosis (DKA) and may be an indicator of subtle brain injury. Brain ratios of *N*-acetylaspartate (NAA) to creatine (Cr), measured by proton MR spectroscopy, decrease with neuronal injury or dysfunction. We hypothesized that brain NAA/Cr ratios may be decreased in children in DKA, indicating subtle neuronal injury.

MATERIALS AND METHODS: Twenty-nine children with DKA underwent cerebral proton MR spectroscopy during DKA treatment (2–12 hours after initiating therapy) and after recovery from the episode (72 hours or more after the initiation of therapy). We measured peak heights of NAA, Cr, and choline (Cho) in 3 locations within the brain: the occipital gray matter, the basal ganglia, and periaqueductal gray matter. These regions were identified in previous studies as areas at greater risk for neurologic injury in DKA-related cerebral edema. We calculated the ratios of NAA/Cr and Cho/Cr and compared these ratios during the acute illness and recovery periods.

RESULTS: In the basal ganglia, the ratio of NAA/Cr was significantly lower during DKA treatment compared with that after recovery (1.68 ± 0.24 versus 1.86 ± 0.28 , $P < .005$). There was a trend toward lower NAA/Cr ratios during DKA treatment in the periaqueductal gray matter (1.66 ± 0.38 versus 1.91 ± 0.50 , $P = .06$) and the occipital gray matter (1.97 ± 0.28 versus 2.13 ± 0.18 , $P = .08$). In contrast, there were no significant changes in Cho/Cr ratios in any region.

CONCLUSIONS: NAA/Cr ratios are decreased in children during DKA and improve after recovery. This finding suggests that during DKA neuronal function or viability or both are compromised and improve after treatment and recovery.

Clinically apparent cerebral edema is the most frequent severe complication of diabetic ketoacidosis (DKA) in children, occurring in 0.7%–0.9% of DKA episodes.^{1,2} Children who have this complication have high rates of mortality and permanent neurologic morbidity.^{1–3} Children at highest risk for cerebral edema during DKA are those with greater dehydration and greater hypocalcemia at presentation,¹ but the precise etiology of this complication is not well understood.

Although only a small minority of children with DKA develop clinically apparent cerebral edema, several studies have suggested that some degree of cerebral edema may be present in most children with DKA.^{4–6} It is unclear, however, whether this “subclinical” cerebral edema is associated with underlying cerebral injury.

Proton MR spectroscopy is an imaging tool that is highly sensitive for detecting cerebral injury.^{7,8} *N*-acetylaspartate (NAA) is a putative neuronal marker⁹ and cerebral injury (decreased neuronal viability, decreased neuronal function, or neuronal loss) is reflected by a decrease in the concentration of NAA relative to other cerebral metabolites.^{7,8} Prior work¹⁰ has shown a decrease in parietal NAA/creatine (Cr) ratios in adults with diabetes compared with normal controls. In addition,

children¹¹ with poorly controlled diabetes have decreased parietal NAA/Cr compared with controls. To date, however, changes in the concentrations of cerebral metabolites have not been evaluated during DKA in children. In the current study, we used proton MR spectroscopy to evaluate cerebral metabolism and injury in children during DKA.

Materials and Methods

Patient population. Patients were enrolled in this study over a 3-year time period at 2 institutions. Participation in this study was offered to all children who met the following criteria: 1) They were younger than 18 years of age, 2) were diagnosed with type 1 diabetes mellitus, and 3) had DKA (defined as serum glucose >300 mg/dL, venous pH <7.25 and/or serum bicarbonate <15 mEq/L, and a positive test for urine ketones or serum ketones >3 mmol/L). The study was completed on all children whose parents or guardians gave consent for participation.

Treatment Protocol

The study was approved by the institutional review boards of the participating institutions. After informed consent from parents or guardians, we treated enrolled patients according to a standardized DKA protocol as previously described.⁶

Imaging Procedures. Patients enrolled in the study underwent MR imaging of the brain by using a standard quadrature birdcage head coil and a 1.5T imaging system (Signa Horizon, LX Version 9.1, GE Healthcare, Milwaukee, Wis) at 2 time points: 1) between 2 and 12 hours after the initiation of treatment for DKA and 2) after recovery from the episode of DKA (72 hours or more after the initiation of treatment for DKA, after metabolic acidosis and ketosis had resolved). Axial T2-weighted fluid-attenuated inversion recovery (FLAIR) images

Received July 14, 2006; accepted after revision September 7.

From the Departments of Pediatrics (N.K., J.P.M., T.M., N.S.G.), Radiology (S.L.W.-G., M.H.B.), and Emergency Medicine (N.K.), University of California, Davis School of Medicine, Sacramento, Calif; and Departments of Pediatrics (E.K.N., J.D.) and Radiology (P.D.B.), Stanford University School of Medicine, Stanford, Calif.

This study was supported by research awards from the American Diabetes Association and the University of California, Davis Health System.

Please address correspondence to Sandra Wootton-Gorges, Department of Radiology, University of California, Davis, 4860 Y St, Suite 3100, Sacramento, CA 95817; e-mail: sandra.gorges@ucdmc.ucdavis.edu

(TR/TE/TI, 10 000/147/2200 ms) were obtained with a FOV of 24 cm, a section thickness of 4.2 mm, and a section gap of 0.8 mm and were followed by proton MR spectroscopy. For the initial 11 patients in the study, multivoxel chemical shift imaging was performed by using the Probe-P sequence (GE Healthcare), a point-resolved spectroscopy sequence designed for the detection of resonances with long T2s. This sequence was used at a single-section location that included the occipital lobes and basal ganglia by using TR/TE 1000/144 ms and a section thickness of 20 mm. The region of interest for automatic shimming was a rectangular area of 0.5–1 cm set inside the skull. The distance between this region and air/tissue/bone interfaces in the skull was increased if the line width was greater than 15 Hz, water suppression was less than 97%, or flip angles were outside a $135 \pm 30^\circ$ range. The spectra were displayed by using the Functool package (GE Healthcare).

Additionally, single-voxel spectroscopy was performed on these 11 patients at the level of the periaqueductal gray matter by using the Probe-P sequence with TR/TE 1500/144 ms. One voxel of 8 cm³ was selected, and automatic shimming on the voxel was performed and routinely produced a line width of 4 Hz or less, water suppression of 99%, and a flip angle of $135 \pm 30^\circ$.

Subsequently, the protocol was modified to allow better resolution of lactate and ketone peaks for a separate substudy.¹² Therefore, patients enrolled subsequently ($n = 18$) had single-voxel MR spectroscopy by using the previously mentioned technique in the right basal ganglia and the right occipital gray matter only.

The periaqueductal gray matter, occipital gray matter, and basal ganglia were chosen as regions of interest for spectroscopy interrogation on the basis of previously described regional patterns of brain injury seen in children with DKA and cerebral edema^{13–15} and on previously described diffusion-weighted imaging abnormalities in children with DKA.⁶

Use of pharmacologic sedation during the imaging procedures was avoided whenever possible. However, in cases where sedation was necessary, sodium pentobarbital (2 mg/Kg or less) or midazolam (0.1 mg/Kg or less) was used.

FLAIR images were prospectively reviewed by a single pediatric radiologist at the time the study was performed.

Peaks of cerebral metabolites were identified according to their chemical shifts as follows⁹: NAA (2.02 ppm), creatine and phosphocreatine (Cr, 3.02 ppm), and free choline compounds (Cho, 3.23 ppm). The heights of the metabolite peaks were used to calculate ratios of NAA/Cr and Cho/Cr.

Statistical Analysis

Changes in the ratios of NAA/Cr, and Cho/Cr between the initial imaging studies and the studies performed after recovery from the episode of DKA were analyzed by using the Wilcoxon signed-rank test. We used Stata statistical software for all calculations (Stata Version 8.2, StataCorp, College Station, Tex).

Results

Thirty-five children with DKA were enrolled into the study. Of these 35 children, 6 completed the initial MR imaging studies but did not complete the follow-up studies. For 5 of these children, the follow-up imaging studies were not completed because parents or guardians did not wish the child to receive pharmacologic sedation. One additional child died before the follow-up studies as the result of a thromboembolic event. The remaining 29 children composed the study population. The

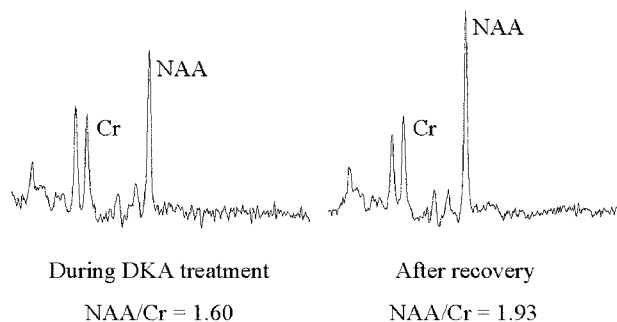


Fig 1. A 13-year-old girl with insulin-dependent diabetes mellitus. Spectra from the right basal ganglia during DKA episode and after recovery, demonstrating a lower NAA/Cr ratio during DKA.

mean age of the patients was 11.9 ± 3.0 years, and 48% were male. Forty-five percent had new-onset diabetes. At the time of presentation to the emergency department, the following mean laboratory measurements were obtained on the enrolled patients: serum glucose concentration 624 ± 221 mg/dL, serum sodium concentration 132 ± 4 mmol/L, blood urea nitrogen concentration 21 ± 8 mg/dL, serum bicarbonate concentration 8.9 ± 3.2 mmol/L, pH 7.12 ± 0.09 , and PCO₂ level 23 ± 9 mm Hg.

Eleven children (38%) manifested abnormalities in mental status (ie, Glasgow Coma Scale [GCS] scores <15) during DKA treatment. For 9 of these 11 children, the mental status abnormalities were mild (minimum GCS scores of 13–14). The other 2 children had greater derangements in mental status, with minimum GCS scores of 12 and 5. Inversion-recovery MR imaging sequence (FLAIR) findings were normal in all patients and did not demonstrate overt cerebral edema in any patient during DKA treatment or after recovery. Specifically, the basal ganglia appeared normal in all patients. One patient received pharmacologic treatment for suspected cerebral edema after the initial MR imaging while awaiting MR imaging results. He had a decline in GCS score to 13 and was treated with mannitol and hypertonic saline. No further treatment was given after findings of the inversion-recovery MR imaging sequence were determined to be normal. All 29 patients recovered fully, without neurologic deficits.

Initial imaging studies were performed a mean of 6.0 ± 2.7 hours after the initiation of therapy for DKA. NAA/Cr ratios were found to be significantly lower in the initial imaging studies of the basal ganglia compared with imaging studies performed in the same brain region after recovery from DKA (Figs 1 and 2). In addition, a trend toward lower NAA/Cr ratios during DKA treatment was seen in the occipital gray matter and periaqueductal gray matter. In contrast, Cho/Cr ratios during DKA treatment and after recovery were not significantly different in any of the regions of interest. Lactate was detected in 5 of the 29 patients (17%) during DKA treatment and was absent in all recovery studies.

Discussion

In this study, we observed a significant decrease in the NAA/Cr ratio within the basal ganglia in children during acute DKA. This ratio increased after recovery from DKA. Similarly, there was a trend toward lower NAA/Cr ratios in the periaqueductal gray matter and the occipital gray matter during DKA com-

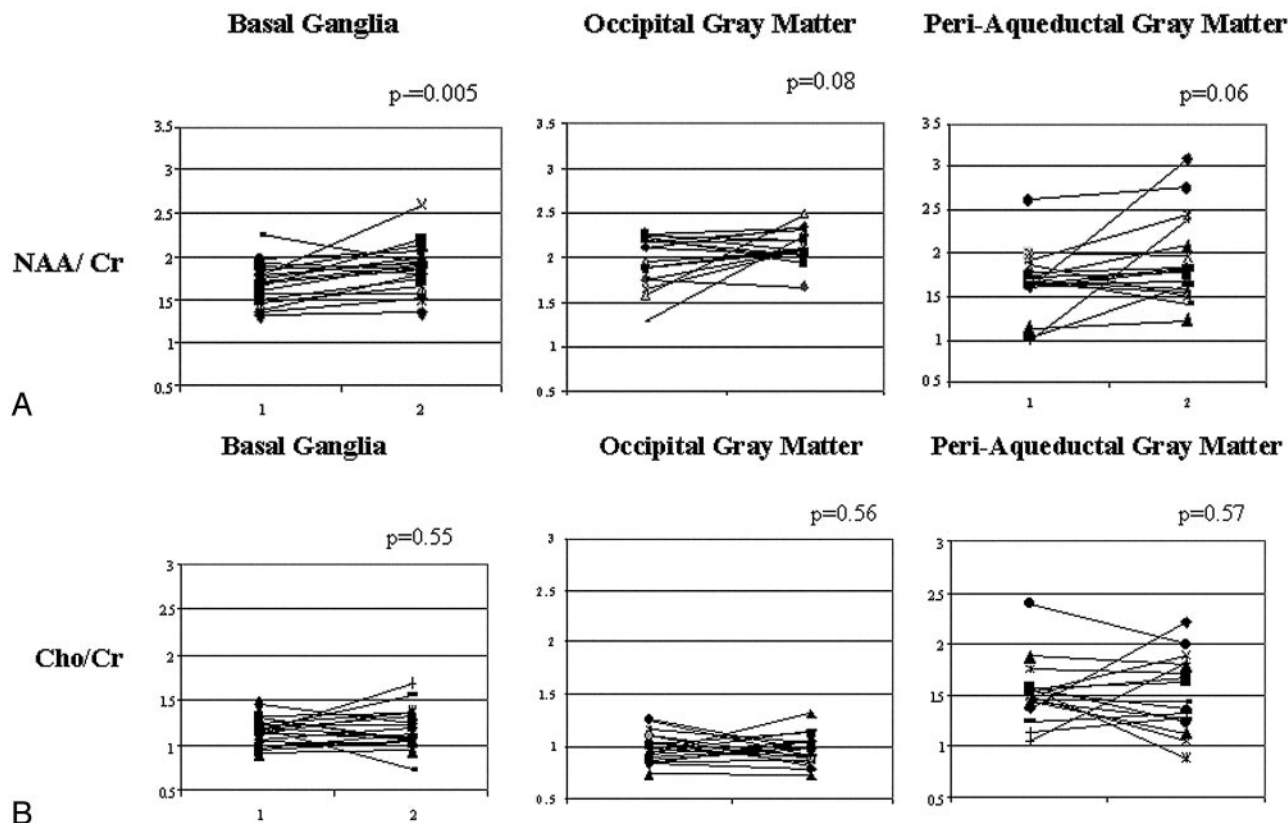


Fig 2. Relative (A) NAA/Cr and (B) Cho/Cr in the basal ganglia, occipital gray matter, and periaqueductal gray matter in study patients during DKA episode and after recovery.

pared with after recovery. In contrast, there were no significant changes in Cho/Cr ratios during and after DKA treatment. These patterns of change imply that neuronal function or viability or both are compromised during DKA.

DKA occurs frequently in children with type 1 diabetes mellitus (DM). Twenty-five percent or more of children with new-onset type 1 DM present with DKA, and children with established type 1 DM have DKA at rates as high as 0.2 events/patient year.¹⁶ Clinically apparent cerebral edema occurs in approximately 1% of pediatric DKA episodes and has a mortality rate of 21%–24%, with many survivors left with permanent neurologic deficits.^{1,2} The exact etiology of cerebral edema in DKA is not yet known and is likely complex and multifactorial. Investigators have evaluated several possible contributing factors including hypoxia-ischemia, alterations in cerebral blood flow, disruption of cell membrane ion transport, generation of intracellular osmolytes, and increased concentrations of various inflammatory mediators.¹⁷

Asymptomatic cerebral swelling occurs with much greater frequency than clinically apparent cerebral edema and may be present in most DKA episodes in children.^{4,5,18} Thus, DKA-related cerebral edema may have varying clinical presentations, ranging from entirely asymptomatic to severe neurologic derangements and manifestations of increased intracranial pressure.

Proton MR spectroscopy is a useful technique for functional interrogation of the brain in many neurologic disorders. Prominent neurotransmitters and metabolites detected within the brain^{9,19} include NAA (2.02 ppm), choline compounds (Cho, 3.23 ppm), and Cr/phosphocreatine (Cr at 3.02

ppm). NAA is a neuronal-axonal marker and is not found in mature glial cells, CSF, or blood.²⁰ Decreases in NAA may result from decreased neuronal viability, decreased neuronal function, or neuronal loss.¹⁹ Decreased NAA has been reported in seizure foci, brain metabolic disorders, neurodegenerative processes, ischemia, and stroke. Reduction of cerebral NAA may be reversible,²¹ and thus it can be used as a dynamic marker of neuronal dysfunction and integrity. The configuration of the NAA molecule and the *N*-acetyl group that gives rise to the 2.02-ppm peak is not influenced by the pH of the blood.¹⁹ Cho compounds (predominantly phosphorylcholine and glycerophosphorylcholine), when membrane-bound, are not MR spectroscopy-visible. Disease processes that result in membrane breakdown, such as neurodegenerative processes or tumors, increase the Cho peak.⁹ Cr and phosphocreatine are high-energy phosphates used in energy-dependent cellular systems. The peak attributable to these metabolites is relatively unaffected by various brain pathologies and therefore has been used as an internal standard to assess changes in other metabolite concentrations.^{9,19} The changes in ratios of peak intensities reflect changes in the corresponding metabolite concentrations.¹⁰

Kreis and Ross¹⁰ have reported decreased NAA/Cr ratios in the parietal region, but not in the occipital cortex, of 22 adults with DM (most of these patients had type 1 DM) in comparison with age-matched controls. Nine of these 22 patients underwent MR spectroscopy imaging within 4 days of treatment for DKA. Two patients had studies performed acutely and after recovery from DKA; however, relative changes in the NAA/Cr ratios in these patients were not reported.

More recently, Surac et al¹¹ noted decreased NAA/Cr ratios in the posterior parietal white matter and in the pons in children with poorly controlled type 1 DM as compared with age-matched healthy children. These authors did not find a similar decrease in NAA/Cr ratios within the basal ganglia; however, no children were imaged during DKA.

The decrease in the NAA/Cr ratio in the basal ganglia during acute DKA suggests that neuronal integrity is compromised and that brain tissue is at risk for neuronal damage or loss. The basal ganglia are known to be particularly susceptible to injury during DKA-induced cerebral edema,^{13,15,22,23} and this susceptibility has been hypothesized to be related to the high adenosine triphosphatase demand of this region.^{14,24} Children at highest risk for cerebral edema during DKA are those with greater dehydration and greater hypocapnia at presentation.¹ It is possible, therefore, that depletion of intravascular volume in combination with cerebral vasoconstriction due to hyperventilation may lead to hypoperfusion and brain ischemia, especially within more vulnerable areas such as the basal ganglia. This scenario is further supported by demonstration of lactate peaks on proton MR spectroscopy within the basal ganglia¹² in children in DKA, suggesting anaerobic cerebral metabolism. Data from animal studies using diffusion-weighted imaging demonstrate that apparent diffusion coefficient (ADC) values are significantly decreased in untreated DKA.²⁵ In human studies using diffusion-weighted imaging and perfusion imaging to evaluate children undergoing treatment for DKA, ADC values were elevated and perfusion was increased.⁶ These data raise the possibility that ischemic injury may occur in untreated DKA, followed by postischemic hyperperfusion during DKA treatment. The current data support this hypothesis by providing evidence of decreased neuronal viability during DKA. In addition, as expected, there were no significant changes in the Cho/Cr ratio in any studied areas of the brain because this ratio would be expected to be elevated only in specific disease processes that result in membrane breakdown, such as neurodegenerative processes or tumors.

Complicating this issue, hyperglycemia is known to worsen the outcome of ischemic neurologic injury. Numerous studies, both in humans and in animal models of stroke and traumatic brain injury, demonstrate that hyperglycemia increases the extent of ischemic damage and the rapidity and degree of edema formation.²⁶⁻²⁹ Although the precise mechanism whereby hyperglycemia enhances ischemic injury is not known, accumulation of lactate and the accompanying intracellular acidosis is thought to play a central role.²⁹ In children with DKA, hyperglycemia may therefore facilitate ischemic injury and endothelial dysfunction leading to edema formation, even under conditions of relatively mild cerebral hypoperfusion.

The increase in the NAA/Cr ratio after recovery from DKA implies some degree of neuronal recovery in these patients without overt evidence of clinical cerebral edema. One limitation of this study, however, is lack of data from normal age-matched controls. We, therefore, cannot determine whether the neuronal recovery observed is complete or whether there may be some residual abnormalities. Long-term impairment of cognitive function is known to occur in patients with type 1 DM and poor glycemic control.³⁰⁻³² It would be reasonable to

surmise that repeated episodes of ischemia during DKA, even in patients without overt cerebral edema, may result in neuronal damage and loss, contributing to subsequent cognitive decline.

In summary, MR spectroscopy may be useful in the evaluation of the brain during DKA in children. The NAA/Cr ratio is significantly decreased in the basal ganglia, and this ratio increases after recovery. Similar trends were observed in the periaqueductal gray matter and the occipital gray matter. These observations imply a loss of neuronal viability and/or function during DKA, with improvement after recovery. This loss of neuronal integrity during DKA may possibly result from ischemia due to hypoperfusion, and hyperglycemia may augment this effect.

Acknowledgments

We also gratefully acknowledge the assistance of Greg Davis and the University of California, Davis MR imaging technology staff in conducting the MR imaging studies.

References

1. Glaser N, Barnett P, McCaslin I, et al. Risk factors for cerebral edema in children with diabetic ketoacidosis. *N Engl J Med* 2001;344:264–69
2. Edge J, Hawkins M, Winter D, et al. The risk and outcome of cerebral oedema developing during diabetic ketoacidosis. *Arch Dis Child* 2001;85:16–22
3. Rosenbloom A. Intracerebral crises during treatment of diabetic ketoacidosis. *Diabetes Care* 1990;13:22–33
4. Hoffman W, Steinhart C, El Gammal T, et al. Cranial CT in children and adolescents with diabetic ketoacidosis. *AJNR Am J Neuroradiol* 1988;9:733–39
5. Krane E, Rockoff M, Wallman J, et al. Subclinical brain swelling in children during treatment of diabetic ketoacidosis. *N Engl J Med* 1985;312:1147–51
6. Glaser NS, Wootton-Gorges SL, Marcin JP, et al. Mechanism of cerebral edema in children with diabetic ketoacidosis. *J Pediatr* 2004;145:164–71
7. Holshouser B, Ashwal S, Shu S, et al. Proton MR spectroscopy in children with acute brain injury: comparison of short and long echo time acquisitions. *J Magn Reson Imaging* 2000;11:9–19
8. Auld K, Ashwal S, Holshouser B, et al. Proton magnetic resonance spectroscopy in children with acute central nervous system injury. *Pediatr Neurol* 1995;12:323–34
9. Moore G. Proton magnetic resonance spectroscopy in pediatric neuroradiology. *Pediatr Radiol* 1998;28:805–14
10. Kreis R, Ross B. Cerebral metabolic disturbances in patients with subacute and chronic diabetes mellitus: detection with proton MR spectroscopy. *Radiology* 1992;184:123–30
11. Surac K, Akinci A, Alkan A, et al. Brain metabolite changes on proton magnetic resonance spectroscopy in children with poorly controlled type 1 diabetes mellitus. *Neuroradiology* 2005;47:562–65
12. Wootton-Gorges S, Buonocore M, Kuppermann N, et al. Detection of cerebral beta-hydroxybutyrate, acetoacetate, and lactate on proton MR spectroscopy in children with diabetic ketoacidosis. *AJNR Am J Neuroradiol* 2005;26:1286–91
13. Roe T, Crawford T, Huff K, et al. Brain infarction in children with diabetic ketoacidosis. *J Diabetes Complications* 1996;10:100–08
14. Muir A, Rosenbloom A, Williams L, et al. Cerebral edema in childhood diabetic ketoacidosis: natural history, radiographic findings and early identification. *Diabetes Care* 2004;27:1541–46
15. Ertl-Wagner B, Jansen O, Schwab S, et al. Bilateral basal ganglia haemorrhage in diabetic ketoacidotic coma: case report. *Neuroradiology* 1999;41:670–73
16. Kaufman F. Diabetes in children and adolescents: areas of controversy. *Med Clin North Am* 1998;82:721–38
17. Edge J. Cerebral oedema during treatment of diabetic ketoacidosis: are we any nearer finding a cause? *Diabetes Metab Res Rev* 2000;16:316–24
18. Glaser N, Wootton-Gorges S, Buonocore M, et al. Frequency of sub-clinical cerebral edema in children with diabetic ketoacidosis. *Pediatr Diabetes* 2006;7:75–80
19. Govindaraju V, Young K, Maudsley AA. Proton NMR chemical shifts and coupling constants for brain metabolites. *NMR Biomed* 2000;13:129–53
20. Birken D, Oldendorf W. N-acetyl-L-aspartic acid: a literature review of a compound prominent in 1H-NMR spectroscopic studies of the brain. *Neurosci Biobehav Rev* 1989;13:23–31
21. Demougeot C, Garnier P, Mossiat C, et al. N-acetylaspartate, a marker of both

- cellular dysfunction and neuronal loss: its relevance to studies of acute brain injury. *J Neurochem* 2001;77:408–15
22. Keller R, Wolfsdorf J. Isolated growth hormone deficiency after cerebral edema complicating diabetic ketoacidosis. *N Engl J Med* 1987;316:857–59
 23. Rogers B, Sills I, Cohen M, et al. Diabetic ketoacidosis: neurologic collapse during treatment followed by severe developmental morbidity. *Clin Pediatr (Phila)* 1990;29:451–56
 24. Jones M. Energy metabolism in the developing brain. *Semin Perinatol* 1979;3:121–29
 25. Lam TI, Anderson SE, Glaser N, et al. Bumetanide reduces cerebral edema formation in rats with diabetic ketoacidosis. *Diabetes* 2005;54:510–16
 26. Warner D, Smith J, Siesjo B. Ischemia in normo- and hyperglycemic rats: effects on brain water and electrolytes. *Stroke* 1987;18:464–71
 27. Parsons M, Barber P, Desmond P, et al. Acute hyperglycemia adversely affects stroke outcome: a magnetic resonance imaging and spectroscopy study. *Ann Neurol* 2002;52:20–28
 28. Rovlias A, Kotsou S. The influence of hyperglycemia on neurological outcome in patients with severe head injury. *Neurosurgery* 2000;46:335–43
 29. Els T, Klisch J, Orszagh M, et al. Hyperglycemia in patients with focal cerebral ischemia after intravenous thrombolysis: influence on clinical outcome and infarct size. *Cerebrovasc Dis* 2002;13:89–94
 30. Widom B, Simonson D. Glycemic control and neuropsychologic function during hypoglycemia in patients with insulin-dependent diabetes mellitus. *Ann Intern Med* 1990;112:904–12
 31. McCarthy A, Lindgren S, Mengeling M, et al. Effects of diabetes on learning in children. *Pediatrics* 2002;109:E9
 32. Franceschi M, Cecchetto R, Minicucci F, et al. Cognitive processes in insulin-dependent diabetes. *Diab Care* 1984;7:228–31