



Providing Choice & Value

Generic CT and MRI Contrast Agents



**FRESENIUS
KABI**

CONTACT REP

AJNR

**Endovascular Treatment of Epistaxis in
Patients with Hereditary Hemorrhagic
Telangiectasia**

K.F. Layton, D.F. Kallmes, L.A. Gray and H.J. Cloft

AJNR Am J Neuroradiol 2007, 28 (5) 885-888

<http://www.ajnr.org/content/28/5/885>

This information is current as
of July 28, 2025.

K.F. Layton
D.F. Kallmes
L.A. Gray
H.J. Cloft

Endovascular Treatment of Epistaxis in Patients with Hereditary Hemorrhagic Telangiectasia

BACKGROUND AND PURPOSE: The treatment of epistaxis in patients with hereditary hemorrhagic telangiectasia can be very challenging. The purpose of our study was to evaluate our experience with endovascular epistaxis embolization in patients with hemorrhagic hereditary telangiectasia and to compare this with our experience in patients treated for idiopathic epistaxis.

MATERIALS AND METHODS: Over a 6-year period, we treated 22 patients with epistaxis by using endovascular embolization. Twelve of 22 patients had hereditary hemorrhagic telangiectasia; 10 patients had idiopathic epistaxis. The angiographic findings, efficacy of treatment, and complications for both groups were compared.

RESULTS: Patients with hereditary hemorrhagic telangiectasia had angiographic abnormalities in 92% of cases compared with only 30% in the idiopathic epistaxis group. Compared with a group of 10 patients treated for other causes of epistaxis, those with hereditary hemorrhagic telangiectasia required significantly more re-embolization treatments or additional surgical procedures because of continued or recurrent bleeding episodes after embolization ($P = .03$). Complications were rare; a single patient in the idiopathic epistaxis group had a self-limited groin hematoma and postembolization facial pain.

CONCLUSION: Endovascular embolization of epistaxis is a safe procedure that can be useful for patients with severe acute epistaxis or chronic persistent bleeding. Patients who undergo endovascular embolization for epistaxis related to hereditary hemorrhagic telangiectasia require repeat embolization and subsequent surgical procedures more often than those with idiopathic epistaxis.

Hereditary hemorrhagic telangiectasia (HHT), also known as Osler-Weber-Rendu disease, is a hereditary disorder involving vascular abnormalities of various organs. Epistaxis from telangiectasias of the nasal mucosa is a common manifestation of this disease and can be an extremely difficult management issue for clinicians.¹⁻³ At our institution, we have a large population of patients with HHT who are referred to the Otorhinolaryngology department for management of epistaxis. Accordingly, a larger proportion of our epistaxis embolization procedures are performed on patients with HHT compared with most practices. We describe our experience and technique for the endovascular treatment of epistaxis in patients with HHT and compare this to a group of patients treated endovascularly for epistaxis unrelated to HHT.

Materials and Methods

Institutional Review Board approval was granted for this retrospective study. All patients treated for epistaxis in the Neuroradiology department between March 2000 and March 2006 were retrieved from an interventional procedures data base. All patients' electronic medical records, angiograms, and embolization procedure notes were reviewed. Twenty-two patients were treated for epistaxis over this period during 27 endovascular treatment sessions.

Endovascular Technique

After obtaining informed consent, patients were brought to the angiography suite. All procedures were performed on a biplane fluoroscopy unit by using conscious sedation or general anesthesia. Using standard techniques, procedures were performed with femoral or ra-

dial artery access. After placement of 5F or 6F arterial sheaths, patients were given 3000 U of heparin intravenously for thromboembolic prophylaxis. A 5F or 6F guiding catheter was then placed in the common carotid arteries, and cervical angiography was performed. Selective internal carotid artery (ICA) and external carotid artery (ECA) digital subtraction angiography was then performed with imaging over the face and skull base. Although embolization was performed exclusively in the ECA territory, ICA imaging was performed for 2 reasons. First, it was important to adequately characterize potentially dangerous ECA-ICA collateral pathways and define the predominant supply to the ophthalmic artery. Second, assessment of anterior and posterior ethmoidal artery supply to the nasal cavity and nasopharynx was useful to document a source of bleeding that was not amenable to safe embolization. Because the ethmoidal arteries generally arise from the ophthalmic artery, embolization of these vessels carries a significant risk of blindness.

After placing the guiding catheter in the proximal ECA trunk and performing an initial control angiogram, a microcatheter was then advanced over a microguidewire into the various ECA branches. After selecting the branches, a superselective angiogram was performed through injection of the microcatheter to define any potentially dangerous ECA-ICA or ECA-ophthalmic artery anastomoses that would preclude safe embolization. We generally selected the internal maxillary artery (IMAX) first and positioned the microcatheter distal to any branches that did not supply the nasal mucosa. Embolization was facilitated by use of a 0.021-inch (i.d.) microcatheter, which allowed for injection of large particles, absorbable gelatin sponge, and fibered coils as needed. Our preferred embolic agent was polyvinyl alcohol particles (PVA) (Contour; Boston Scientific, Fremont, Calif). To prevent tissue necrosis, we generally used 250–355- μ m particles or larger. Although sizes smaller than this can be used, the risk of skin and mucosal necrosis is elevated with smaller particles, and the procedure must be performed with caution. Except for cases of traumatic pseudoaneurysms, we preferred to avoid permanent vessel occlusion

Received June 12, 2006; accepted after revision August 15.

From the Mayo Clinic, Department of Radiology, Rochester, Minn.

Address correspondence to Kenneth F. Layton, MD, Baylor University Medical Center, Department of Radiology, 3500 Gaston Ave, Dallas, TX 75246; e-mail: klayton@americanrad.com

with coils because this may prevent further treatment in the target vessel in cases of epistaxis recurrence. Embolization in a specific vessel was terminated when stagnant flow was observed. After carefully clearing the microcatheter of particles, a final superselective microcatheter angiogram was performed. Because of the rich collateral ECA supply to the nasal mucosa, treatment of multiple ECA branches was often required. ECA branches that contributed significant supply to the mucosa include the IMAX, transverse facial, facial, lingual, and ascending pharyngeal arteries.

In cases of nontraumatic epistaxis, we performed bilateral ECA embolizations. This was important because of the robust side-to-side ECA anastomoses that can be recruited to bleeding mucosa. If the epistaxis was predominantly unilateral, we vigorously embolized the affected side until all ECA vessels with supply to the nasal mucosa were occluded. The contralateral side was treated less vigorously, with fewer arterial pedicles treated and smaller volumes of PVA injections, to avoid tissue necrosis. After the ECA branches were embolized, a final ECA angiogram was performed to assess for adequacy of treatment and to assure that no additional sources of bleeding had appeared.

In those cases in which recurrent epistaxis was encountered, patients were sometimes re-embolized if requested by the otorhinolaryngologist. Short-term re-embolization consisted of treating additional ECA branches that were not embolized during the initial procedure or that were found to have recanalized since the initial procedure. In general, re-embolization was not offered to those patients with short-term recurrent epistaxis in whom angiographically complete embolization had been performed and in whom there was documented robust ophthalmic origin supply.

Study Parameters

Patients were divided into 2 subgroups: 12 patients with HHT and 10 patients with idiopathic epistaxis. Differences in angiographic findings, treatment efficacy, and complications between the 2 groups were evaluated.

Results

The mean age of patients treated for epistaxis was 60 years (range, 19–86 years). Thirteen of the 22 patients (59%) were male. In the HHT and idiopathic groups, 5 of 12 (42%) and 8 of 10 (80%) patients, respectively, were male. A comparison of angiographic findings, number of embolization sessions, number of arterial branches embolized, percentage of bilateral ECA embolizations, and history of previous surgery for epistaxis for the 2 groups is shown in Table 1. Most patients with epistaxis related to HHT had abnormal angiogram results; most patients in the idiopathic group had a normal angiogram. Angiographic abnormalities in patients with HHT included mucosal telangiectasias (Fig 1) in 8 of 12 (67%) and unusually prominent mucosal blush in 3 of 12 (25%). Angiographic abnormalities in the idiopathic epistaxis group consisted of 2 pseudoaneurysms (20%) and one patient with an unusually prominent mucosal blush (10%). It is noteworthy that 11 of 16 (69%) patients with HHT had prominent mucosal supply from ethmoidal branches of the ophthalmic artery compared with only 1 of 11 (9%) of patients in the idiopathic group. This difference was very statistically significant, with a *P* value of .0047 calculated by using the Fisher exact test. Furthermore, 2 patients with HHT were found to have new angiographically demonstrated supply to the nasal mucosa from

Table 1: Comparison of angiographic findings and treatment parameters between patients with HHT and patients with idiopathic epistaxis

	Normal Angiogram	Required Multiple Embolizations
HHT	1/12 (8%)	6/12 (50%)
Idiopathic	7/10 (70%)	1/10 (10%)
	<i>P</i> = .0062	<i>P</i> = 0.0743
Previous surgery for epistaxis		
HHT	8/12 (67%)	
Idiopathic	4/10 (40%)	
	<i>P</i> = .3913	
Mean number of vessels embolized		
HHT	2.75	
Idiopathic	2.27	
	<i>P</i> = .1975	
Bilateral ECA vessel embolization performed		
HHT	15/16 (94%)	
Idiopathic	7/11 (64%)	
	<i>P</i> = .1252	

Note:—HHT indicates hereditary hemorrhagic telangiectasia; ECA, external carotid artery. *P* values were calculated using the Fisher exact test for categorical data and *t* test for continuous data.

these ethmoidal branches after previous IMAX embolization. However, there was no significant correlation between the presence of ethmoidal branches of the ophthalmic artery and the need for re-embolization (*P* = .5758).

Six of 12 patients (50%) with HHT underwent multiple endovascular embolization treatments. Two of the 6 patients had been embolized at another institution before our treatment, and 4 patients were treated multiple times at our institution. Eight of 12 (67%) patients with HHT had undergone surgical treatment for epistaxis before endovascular embolization, and only 2 of these patients benefited from endovascular therapy. In patients with idiopathic epistaxis, 4 of 10 (40%) had undergone previous surgery. In contrast to patients with HHT, all patients in with idiopathic epistaxis who had undergone previous surgery benefited from embolization. A comparison of efficacy between the 2 groups is shown in Table 2. Using the Fisher exact test, success after a single embolization treatment was found to be statistically significantly higher in patients with idiopathic epistaxis, with a *P* value of .03. A procedure was considered a success if the patient no longer had significant epistaxis and required no additional embolization or surgical procedures.

In all 22 patients, the mean number of vessels embolized in patients who rebled versus those that did not was 2.4 and 2.7, respectively. In patients with HHT, the mean number of vessels embolized in those that rebled and those that did not was 2.5 and 3.3, respectively. Using a 2-tailed, nonpaired *t* test, the number of vessels embolized was not found to be statistically significant in either the entire epistaxis population or the HHT cohort.

Complications were rare in our experience. There was a single, self-limited groin hematoma and one instance of postembolization facial pain that eventually resolved. Both of these events occurred in the same patient. We experienced no complications of significant tissue necrosis or stroke.

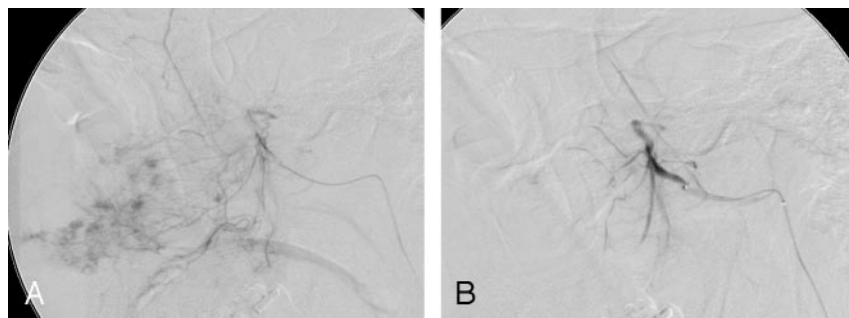


Fig 1. A, Lateral angiogram image after superselective injection of the internal maxillary artery before embolization demonstrates the characteristic patchy mucosal telangiectasias in a patient with HHT.

B, After embolization with 250–355- μ m PVA particles, the abnormal mucosal telangiectasias are no longer visualized.

Table 2: Comparison of embolization efficacy between patients with HHT and those with idiopathic epistaxis

	HHT	Idiopathic
Resolved after 1 embolization	3/12 (25%)	8/10 (80%)
Resolved after multiple embolizations	3/12 (25%)	1/10 (10%)
Rebleed requiring surgery	4/12 (33%)	1/10 (10%)
Significant continued bleeding despite surgery and embolization	2/12 (17%)	0/10 (0%)

Note:—HHT indicates hereditary hemorrhagic telangiectasia.

Discussion

A significant number of patients with HHT experience severe epistaxis that often requires transfusions, surgical therapy, and endovascular embolization. Management of epistaxis in these patients can be very frustrating, and recurrent episodes of bleeding after treatment are common. Despite many reports on the medical, surgical, and endovascular treatment options for epistaxis in patients with HHT, treatment is variable and generally depends on institutional preferences.^{1–6}

Although all of the treatments in current practice allow some relief to patients with HHT with epistaxis, no treatment allows for a definitive cure in most patients. Treatment is generally aimed at reducing the number and severity of epistaxis episodes to improve quality of life and reduce the number of trips to the emergency department. Although we have had great success treating epistaxis in patients without HHT, our results in patients with HHT have not been as impressive. In patients without HHT, we were able to provide a cure with a single endovascular procedure in 80% of cases. This compares with a single procedure cure in only 25% of patients with HHT. Although we were able to reduce the severity and rate of epistaxis episodes in patients with HHT, 58% required subsequent surgery or re-embolization, and 17% continued to have severe epistaxis that was managed medically because all surgical treatment options had been exhausted.

There are few reports in the English literature on the endovascular treatment of epistaxis in patients with HHT. The first successful cases were described in the 1970s.^{7–10} Various case reports since then have demonstrated the safety and feasibility of epistaxis embolization in patients with HHT.^{11–14} Reported efficacy rates vary widely, depending on the definition of a positive response. Andersen et al⁴ reported a positive benefit in 80% of patients with HHT defined as a reduced duration and number of episodes of epistaxis. However, their experience was similar to ours; only 13% of procedures effected an ultimate cure. These authors reported that patients experienced facial pain, numbness, or necrosis in most procedures. In contrast, we experienced this problem in only 1 of 22 (5%) pa-

tients, and this may be due to our routine use of larger particle sizes.

Elden et al¹³ reported a 90% success rate in their experience treating epistaxis with endovascular techniques. More than half of the long-term failures in their series occurred in patients with HHT. Fischer et al¹⁵ documented an average time to epistaxis recurrence after embolization of 3.5 days in patients with HHT. Furthermore, they reported only a 20% long-term benefit to embolization, which is similar to our experience.

No randomized trials have compared endovascular therapy with medical and surgical options for epistaxis in patients with HHT. Such a study would be difficult to construct given the limited number of patients with HHT. There are variations in opinion regarding the preferred order of treatment in patients with HHT. Some authors have suggested initial embolization followed by surgical ligation; others favor surgery first followed by embolization.^{9,16} Comparison of the limited case series on this subject is also difficult given the wide variation in positive treatment end points and variations in technique.

We found that a significantly higher proportion of patients with HHT had noticeable arterial supply to the nasopharyngeal mucosa from ethmoidal branches of the ophthalmic and internal carotid arteries compared with those with idiopathic epistaxis. The increased supply from ethmoidal branches is probably related to the underlying diffuse vascular abnormality present in these patients that is capable of recruiting collateral supply after embolization procedures. Because the ethmoidal branches of the ophthalmic artery generally cannot be embolized safely because of the risk of blindness, this may account for the higher rate of continued epistaxis and recurrent bleeding after embolization procedures in patients with HHT.

Even though many of the patients with HHT whom we have treated for epistaxis have required re-embolization or subsequent surgical therapy, we feel that endovascular therapy still has a role to play in HHT-related epistaxis. The optimal initial endovascular treatment should include complete embolization of all ECA vessels that supply the nasal mucosa, keeping in mind that the risk of mucosal and skin necrosis increases as more ECA vessels are occluded. Permanent occlusion of the proximal vessels with coils is generally not advised because this may preclude re-embolization in the target vessel if distal collaterals are formed and result in recurrent epistaxis. Based upon the results of our experience, we carefully counsel patients about our experience treating HHT-related epistaxis and the high rate of re-embolization or subsequent surgery required.

Conclusion

The results of our and others' experience show that endovascular embolization of epistaxis is a safe procedure when performed by experienced operators. Patients with HHT are more likely to have angiographic abnormalities than those with idiopathic epistaxis. Although embolization cannot be expected to provide a long-term cure in most patients with HHT, it can reduce the severity and duration of bleeding in some patients and can be performed on an emergent basis for control of severe epistaxis until patients are stabilized.

References

1. Fiorella ML, Ross DA, White RI, et al. [Hereditary hemorrhagic telangiectasia: state of the art]. *Acta Otorhinolaryngol Ital* 2004;24:330–36
2. Pau H, Carney AS, Murty GE. Hereditary haemorrhagic telangiectasia (Osler-Weber-Rendu syndrome): otorhinolaryngological manifestations. *Clin Otolaryngol* 2001;26:93–98
3. Guttmacher AE, Marchuk DA, White RI Jr. Hereditary hemorrhagic telangiectasia. *N Engl J Med* 1995;333:918–24
4. Andersen PJ, Kjeldsen AD, Nepper-Rasmussen J. [Selective embolization in the treatment of intractable epistaxis.] *Acta Oto-Laryngologica* 2005;125:293–97
5. Kantor I, Winiarski M, Jurkiewicz D, et al. [The use of superselective embolization of the maxillary artery in treatment of bleedings in the Rendu-Osler-Weber syndrome.] *Otolaryngol Pol* 2005;59:215–17
6. Duncan IC, Van Der Nest L. Intralesional bleomycin injections for the palliation of epistaxis in hereditary hemorrhagic telangiectasia. *AJNR Am J Neuroradiol* 2004;25:1144–46
7. Sokoloff J, Wickbom I, McDonald D, et al. Therapeutic percutaneous embolization in intractable epistaxis. *Radiology* 1974;111:285–87
8. Strother CM, Newton TH. Percutaneous embolization to control epistaxis in Rendu-Osler-Weber disease. *Arch Otolaryngol* 1976;102:58–60
9. Riche MC, Chiras J, Melki JP, et al. The role of embolization in the treatment of severe epistaxis. *J Neuroradiol* 1979;6:207–20
10. Merland JJ, Melki JP, Chiras J, et al. Place of embolization in the treatment of severe epistaxis. *Laryngoscope* 1980;90:1694–704
11. Weissman JL, Jungreis CA, Johnson JT. Therapeutic embolization for control of epistaxis in a patient with hereditary hemorrhagic telangiectasia. *Am J Otolaryngol* 1995;16:138–40
12. Kramann B, Roth R, Schneider G, et al. [Percutaneous therapeutic embolization in therapy refractory, non-traumatic epistaxis.] *HNO* 1998;46:973–79
13. Elden L, Montanera W, Terbrugge K, et al. Angiographic embolization for the treatment of epistaxis: a review of 108 cases. *Otolaryngol Head Neck Surg* 1994;111:44–50
14. Lasjaunias P, Appel B, Carriere T. [Rendu-Osler-Weber disease. Diagnostic and therapeutic assessment by angiography.] *Ann Otolaryngol Chir Cervicofac* 1983;100:203–15
15. Fischer M, Dietrich U, Labisch C, et al. [Critical evaluation of vascular embolization in patients with Rendu-Osler disease.] *Laryngorhinootologie* 1997;76:490–94
16. Parnes LS, Heeneman H, Vinuela F. Percutaneous embolization for control of nasal blood circulation. *Laryngoscope* 1987;97:1312–15