



**Providing Choice & Value**

Generic CT and MRI Contrast Agents



**FRESENIUS  
KABI**

**CONTACT REP**

**AJNR**

**Underestimation of Cerebral Perfusion on  
Flow-Sensitive Alternating Inversion  
Recovery Image: Semiquantitative  
Evaluation with Time-to-Peak Values**

H.S. Kim, S.Y. Kim and J.M. Kim

This information is current as  
of July 15, 2025.

*AJNR Am J Neuroradiol* 2007, 28 (10) 2008-2013

doi: <https://doi.org/10.3174/ajnr.A0720>

<http://www.ajnr.org/content/28/10/2008>

## ORIGINAL RESEARCH

H.S. Kim  
S.Y. Kim  
J.M. Kim

# Underestimation of Cerebral Perfusion on Flow-Sensitive Alternating Inversion Recovery Image: Semiquantitative Evaluation with Time-to-Peak Values

**BACKGROUND AND PURPOSE:** We assessed the underestimation of cerebral perfusion measured by the flow-sensitive alternating inversion recovery (FAIR) technique in patients with carotid stenosis and compared the technique with dynamic susceptibility contrast (DSC) MR images.

**MATERIALS AND METHODS:** We studied 42 areas of decreased cerebral blood flow (CBF) using 3 FAIR images with different inversion times (TIs) in 42 consecutive patients with unilateral carotid stenosis of more than 50%. The width of decreased CBF area (wCBF) was qualitatively assessed. We analyzed the ratio of CBF (rCBF) and the time-to-peak (TTP) difference (dTTP) between the ipsilateral hemisphere to carotid stenosis and contralateral normal area using regions of interest (ROIs) at the same location.

**RESULTS:** In the areas with more prolonged TTP ( $\text{dTTP} \geq 3.2$  s), the wCBF obtained from the FAIR images with TI of 1600 ms was smaller than those from the FAIR images with a TI of 800 ms and 1200 ms in all cases. The mean rCBF obtained from the FAIR images with a TI of 1200 ms was significantly lower than that obtained from the FAIR images with a TI of 1600 ms ( $P < .01$ ) in the areas with more prolonged TTP. In the areas with less prolonged TTP ( $\text{dTTP} < 3.2$  s), the wCBF and mean rCBF were not significantly different between the 2 FAIR images (TI, 1200 and 1600 ms).

**CONCLUSION:** If TTP is delayed significantly ( $\text{dTTP} \geq 3.2$  s), the FAIR with intermediate or short TI showed underestimation of perfusion in the same area with delay in TTP.

Hemodynamic parameters obtained by various imaging techniques provide important information on the perfusion status of the ischemic brain, which can be used to determine whether a patient should receive a specific treatment such as medication or a recanalization procedure. MR images allow for dynamic susceptibility contrast (DSC) perfusion technique with the use of exogenous, nondiffusible contrast agents with arterial input function correction,<sup>1,2</sup> and for the arterial spin-labeling (ASL) perfusion techniques with use of endogenous diffusible contrast agents.<sup>3-5</sup> Both ASL and DSC methods of perfusion have been applied in stroke studies on humans.<sup>6,7</sup> With ASL, the protons of the arterial water in the feeding arteries are electromagnetically labeled; after the spin-labeling, a certain delay is necessary before acquisition of an image. This delay (inversion time, TI) allows the labeled arterial water spin to flow through the arterial vascular tree and exchange magnetization with the unlabeled tissue water. The subsequent change in tissue magnetization yields information about the cerebral blood flow (CBF) and can be detected on MR imaging.<sup>8</sup>

TI is related to the fundamental problem that the time required for tagged arterial blood to travel from the tagging region to the capillary is similar to the T1 of blood. This makes it necessary to acquire the image while many dynamic processes are taking place (delivery, exchange, clearance by T1, and

flow). If images are acquired too early after application of the tag, then CBF can be underestimated because of the presence of a transit delay, or overestimated because of tagged intravascular signal intensity traveling through the imaging section. If images are acquired for a long time after the application of the tag, then the tag signal intensity is small because of T1 decay and more difficult to quantify because the tagged blood water exchanges into brain tissue, where the rate of T1 decay is different from that of blood.<sup>9,10</sup>

In clinical studies, ASL has been shown to be useful for the noninvasive assessment of CBF in patients with carotid stenosis.<sup>11,12</sup> However, in these patients, the quantification of CBF is complicated because of the relatively large contribution of collateral blood flow to the ipsilateral area of the carotid stenosis. Labeled blood flow via the collateral vessels has a delayed arrival in this region. Therefore, this phenomenon results in an underestimation of the CBF. With ASL performed at a single TI, delayed collateral flow causes a decrease in signal intensity on ASL images to erroneously indicate a decrease in CBF, whereas the signal intensity decay is primarily because of transit time effects.<sup>8,13</sup>

We assessed the underestimation of cerebral perfusion measured by flow-sensitive alternating inversion recovery (FAIR) and compared this technique with the DSC MR perfusion parameter by using time-to-peak (TTP) values.

## Materials and Methods

### Patients

Between May 2005 and March 2006, 42 consecutive patients (mean age, 57 years; age range, 15–80 years; 22 male, 20 female) with unilateral carotid stenosis underwent pulsed ASL MR imaging with the

Received May 9, 2006; accepted with revision April 2, 2007.

From the Department of Diagnostic Radiology, Ajou University, College of Medicine, Kyunggi-do, Republic of Korea.

Please address correspondence to Ho Sung Kim, MD, Department of Diagnostic Radiology, Ajou University, School of Medicine, Mt. 5, Woncheon-dong Yeongtong-gu Suwon-si, Gyeonggi-do 442-749, Republic of Korea; e-mail: J978005@lycos.co.kr

DOI 10.3174/ajnr.A0720

FAIR technique, as well as DSC MR images. We evaluated 42 areas of decreased CBF in these patients. To determine the degree of stenosis of the internal carotid artery (ICA), we used the criteria of the North American Symptomatic Carotid Endarterectomy Trial (NASCET).<sup>14</sup> We evaluated stenosis of the ICA with CT angiograms ( $n = 42$ ) and conventional digital subtraction angiograms ( $n = 25$ ). In all cases with ICA stenosis, the degree of stenosis of the ipsilateral ICA was greater than 50% (50% to 70%, 35 patients; 70% to 90%, 7 patients), and the contralateral ICA was normal. ICA stenosis was found at the origin of the ICA around the carotid bifurcation in 32 patients and at the distal supraclinoid ICA in 10 patients. No patients had a major stroke, and none were thrombolytic candidates. The patients had experienced single or recurrent episodes of a transient ischemic attack ( $n = 19$ ) or a minor stroke ( $n = 5$ ). Transient neurologic deficits were defined as symptoms that lasted for less than 24 hours. A minor disabling deficit was associated with a Rankin scale score ( $<3$ ) and symptoms that persisted for longer than 24 hours.<sup>15</sup> We obtained informed consent from all patients and their relatives, and the institutional review board of our hospital approved the study protocol.

### MR Imaging Protocol

We performed MR images with a 1.5T system (Signa Excite; GE Healthcare, Milwaukee, Wis) and included the following sequences: axial fast spin-echo T2-weighted imaging, axial spin-echo T1-weighted imaging, fluid-attenuated inversion recovery imaging, diffusion-weighted imaging, FAIR imaging, and DSC MR imaging. An 8-channel head coil was used for radio-frequency transmission and signal intensity reception during all MR images.

The FAIR sequence comprised alternating section-selective and nonselective radio-frequency inversion pulses and was performed with TIs of 800, 1200, and 1600 ms between the labeling and image acquisitions. This range of TIs (800–1600 ms) was selected on the basis of the T1 decay of magnetically labeled water.<sup>16</sup> We obtained the final FAIR maps by subtracting the nonselective inversion recovery images from the section selective images at each of the 3 different TIs. Other imaging parameters used to perform the multisection FAIR technique were TR, 2000 ms; TE, 15 ms; FOV, 24 cm; matrix,  $128 \times 128$ ; NEX, 100; section thickness, 5 mm; number of sections, 7; and section gap, 2 mm. The total acquisition time for FAIR imaging was 3 minutes, 22 seconds. Seven FAIR image sections were acquired at the same locations as the DSC MR images.

The DSC MR images were performed with gradient-echo echo-planar sequences during the injection of 0.2 mmol/kg of body weight gadopentetate dimeglumine (Magnevist; Schering, Berlin, Germany) at a rate of 4 mL/s with an MR-compatible power injector (Spectris; MedRad, Indianola, Pa). The bolus of contrast material was followed by a 15-mL bolus of saline that was administered at the same injection rate. A gradient-echo echo-planar sequence was used with the following parameters: TR, 1600 ms; TE, 80 ms; flip angle,  $90^\circ$ ; FOV, 24 cm; matrix,  $128 \times 128$ ; section thickness, 5 mm; number of sections, 7; and section gap, 2 mm. All images were transferred to a workstation (Advantage Workstation 4.1, GE Healthcare). Perfusion maps of relative cerebral blood volume (CBV), TTP, and relative CBF were generated off-line at a workstation. We used a gamma-variate fit to derive hemodynamic parameters from the DSC MR image to obtain a map of relative CBF, relative CBV, and TTP in arbitrary units. After eliminating the recirculation of contrast agent with gamma-variate curve fitting, we computed the relative CBV with a numeric integration of the curve. We generated the TTP by computing the arrival time of contrast material to maximum concentration. The relative CBF map

was obtained with the method of singular value decomposition deconvolution. The shape of the arterial input function was determined from the proximal middle cerebral artery contralateral to the affected hemisphere, and the relative CBF was determined as the height of the deconvoluted tissue curve.

### Image Analysis

Images were analyzed prospectively by 2 neuroradiologists who were blinded to the clinical data of the patients and to the findings obtained with the other imaging technique. The neuroradiologists qualitatively evaluated the width of the area in which the CBF was diminished (wCBF) ipsilateral to the carotid stenosis on each of the 3 FAIR images. To compare the wCBFs between the 3 FAIR images, the 2 observers examined the images together and reached a final decision that was consensual. Each wCBF region obtained with a TI of 800 was categorized as being greater than, less than, or equal to the corresponding wCBF region with TIs of 1200 and 1600. The wCBF region obtained with a TI of 1200 was also categorized as being greater than, less than, or equal to the corresponding wCBF region with a TI of 1600.

To analyze the regions of interest (ROIs), we spatially coregistered all pulsed arterial spin-labeling (PASL) images to the DSC MR images to superimpose the ROIs delineated on the TTP map with use of SPM2 software (Wellcome Department of Cognitive Neuroscience, London, England). All PASL and DSC MR images were coregistered into the volume data with the same  $128 \times 128$  matrix. After selection of patients with delay in TTP, the 2 observers consensually identified the most prolonged area of TTP and independently drew a ROI in the visually most prolonged area of TTP ipsilateral to the carotid stenosis. These ROIs were transferred to the corresponding coregistered PASL images. Each ROI value on the TTP and 3 FAIR images was averaged from the measurements obtained by the 2 observers. For comparison, mirror ROIs were manually redrawn on the TTP maps for the contralateral hemisphere. The relative ratio of CBF (rCBF) on the PASL images was calculated by dividing the lesion values by the mirror ROI value of the contralateral hemisphere. Delay in TTP was defined as the difference between the TTP (dTTP) of a lesion and that of the contralateral hemisphere. The size of each ROI was  $300 \text{ mm}^2$ . We defined the cutoff value of dTTP as the minimum value that produced a significant difference in rCBF between the FAIR image with the longest TI (1600 ms) and that with the intermediate TI (1200 ms). Differences in wCBF and rCBF between the 3 FAIR images were analyzed according to the dTTP cutoff value.

### Statistical Analysis

The rCBF data obtained by the 3 FAIR images were pooled according to the values of dTTP. Pearson correlation coefficients of rCBF values between the 3 FAIR images were calculated according to the cutoff value of the dTTP. Repeated measures analysis of variance (ANOVA) was used to test for a statistically significant difference of the rCBF among the 3 FAIR images according to the cutoff value of the dTTP. If a significant difference was found, the Tukey-Kramer multiple comparisons test was used for post hoc analysis. A  $P$  value  $<.05$  was considered to indicate a statistically significant difference.

### Results

The T2-weighted images revealed multiple small areas of high signal intensity predominantly within the affected centrum semiovale and corona radiata in 7 patients. None of the patients exhibited evidence of territorial infarcts. The areas

**Table 1: Width of decreased CBFs among the three FAIR maps with different inversion times according to the TTP difference**

wCBF	dTTP <3.2 s (%)	dTTP ≥3.2 s (%)
FAIR 800 < FAIR 1200	0/25 (0)	0/17 (0)
FAIR 800 = FAIR 1200	23/25 (92)	12/17 (71)
FAIR 800 > FAIR 1200	2/25 (8)	5/17 (29)
FAIR 800 < FAIR 1600	0/25 (0)	0/17 (0)
FAIR 800 = FAIR 1600	17/25 (68)	3/17 (18)
FAIR 800 > FAIR 1600	8/25 (32)	14/17 (82)
FAIR 1200 < FAIR 1600	0/25 (0)	0/17 (0)
FAIR 1200 = FAIR 1600	22/25 (88)	5/17 (29)
FAIR 1200 > FAIR 1600	3/25 (12)	12/17 (71)

**Note:**—wCBF, width of decreased CBF; dTTP, TTP difference; FAIR 800, TI = 800 ms; FAIR 1200, TI = 1200 ms; FAIR 1600, TI = 1600 ms.

where the CBF was diminished and the TTP was prolonged included the external watershed areas between the middle cerebral artery (MCA) and the anterior or posterior cerebral artery territories, the internal watershed areas, and the ipsilateral MCA territories.

The wCBF obtained from the FAIR images was smaller than that of the TTP map (Table 1). The mean dTTP of all patients was 3.0 s (range, 0.8–8.0 s). The cutoff value of the dTTP that produced a significant difference in rCBF between the FAIR image with the longest TI (1600 ms) and that with the intermediate TI (1200 ms) was 3.2 s. Among the 42 areas of

**Table 2: Correlation coefficients of rCBF among the three FAIR maps**

Groups	dTTP <3.2 s	dTTP ≥3.2 s
FAIR 800 vs FAIR 1200	$r = 0.764, P < .01$	$r = 0.712, P < .01$
FAIR 800 vs FAIR 1600	$r = 0.667, P < .01$	$r = 0.595, P < .01$
FAIR 1200 vs FAIR 1600	$r = 0.791, P < .01$	$r = 0.612, P < .01$

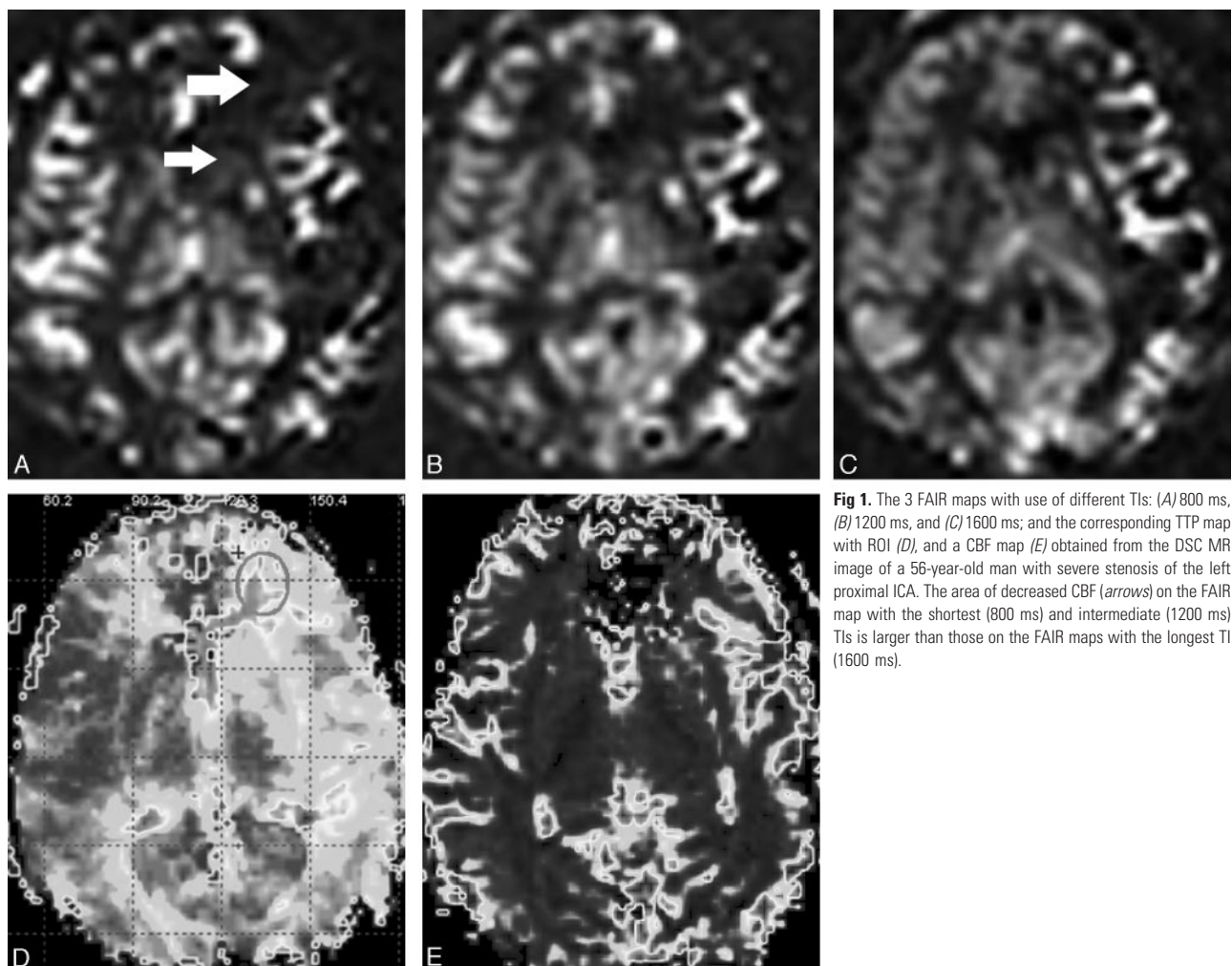
**Note:**—dTTP indicates TTP difference; FAIR 800, TI = 800 ms; FAIR 1200, TI = 1200 ms; FAIR 1600, TI = 1600 ms;  $r$ , correlation coefficient.

decreased CBF, the dTTP was more than 3.2 s in 17 areas and dTTP was less than 3.2 s in 25 areas.

The wCBFs obtained from each of the 2 FAIR images with TIs of 800 ms and 1200 ms were larger than that obtained from the corresponding FAIR image with a TI of 1600 ms in the 12 of 17 areas with a more prolonged TTP (dTTP ≥3.2 s) (Fig 1), and in the 3 of 25 areas with a less prolonged TTP (dTTP <3.2 s).

Correlations of the rCBF values obtained from each of the 3 FAIR images were stronger in the areas with a less prolonged TTP (dTTP <3.2 s) than in the areas with a more prolonged TTP (dTTP ≥3.2 s) (Table 2).

In the areas where the TTP was less prolonged (dTTP <3.2 s), the mean rCBF values obtained from the FAIR image with a TI of 800 ms were significantly lower than those obtained from each of the 2 FAIR images with a TIs of 1200 and 1600 ms ( $P < .01$ ). However, there were no significant differences be-



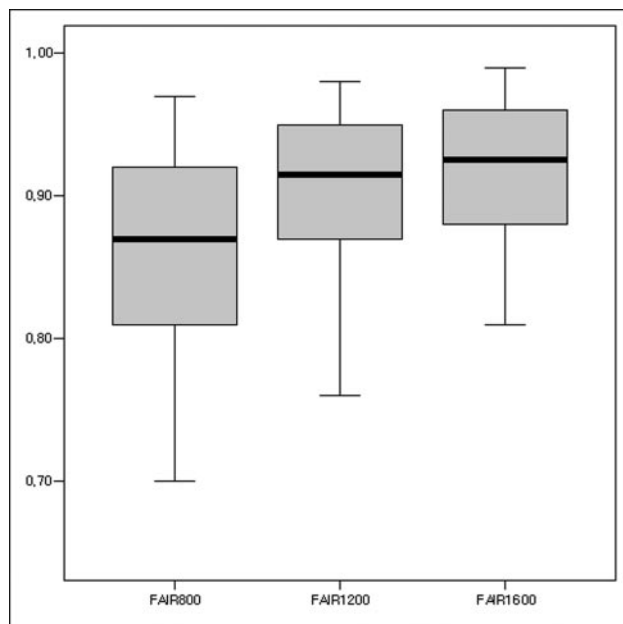
**Fig 1.** The 3 FAIR maps with use of different TIs: (A) 800 ms, (B) 1200 ms, and (C) 1600 ms; and the corresponding TTP map with ROI (D), and a CBF map (E) obtained from the DSC MR image of a 56-year-old man with severe stenosis of the left proximal ICA. The area of decreased CBF (arrows) on the FAIR map with the shortest (800 ms) and intermediate (1200 ms) TIs is larger than those on the FAIR maps with the longest TI (1600 ms).

**Table 3: Comparison of rCBF among the three FAIR images in the areas with less prolonged TTP (dTTP <3.2 s)\***

Comparison	MD	P Value	95% CI
FAIR 800 vs FAIR 1200	−0.031	<.05	−0.060−0.003
FAIR 800 vs FAIR 1600	−0.046	<.001	−0.075−0.017
FAIR 1200 vs FAIR 1600	−0.015	>.05	−0.043−0.014

**Note:**—MD indicates mean difference; CI, confidence interval; FAIR 800, TI = 800 ms; FAIR 1200, TI = 1200 ms; FAIR 1600, TI = 1600 ms.

\* Statistical analysis was performed with the repeated measures ANOVA and post hoc analysis with the Tukey-Kramer multiple comparisons test.



**Fig 2.** A stem-and-leaf plot of the rCBFs between the ipsilateral lesions and contralateral normal areas on the 3 FAIR images in the area with less prolonged TTP (dTTP <3.2 s) (FAIR, 800 ms; TI, 800 ms; FAIR, 1200 ms; TI, 1200 ms; FAIR, 1600 ms; TI, 1600 ms).

**Table 4: Comparison of rCBF among the three FAIR images in the area with more prolonged TTP (dTTP ≥3.2 s)\***

Comparison	MD	P Value	95% CI
FAIR 800 vs FAIR 1200	−0.026	<.05	−0.049−0.002
FAIR 800 vs FAIR 1600	−0.078	<.001	−0.101−0.054
FAIR 1200 vs FAIR 1600	−0.052	<.001	−0.075−0.029

**Note:**—MD indicates mean difference; CI, confidence interval; FAIR 800, TI = 800 ms; FAIR 1200, TI = 1200 ms; FAIR 1600, TI = 1600 ms.

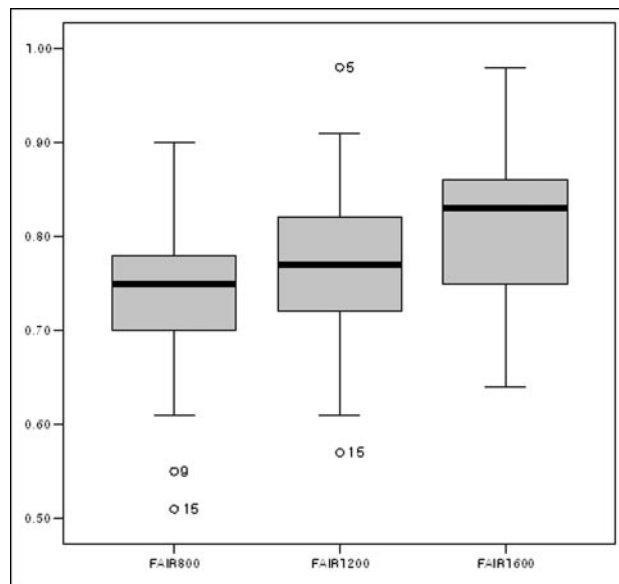
\* Statistical analysis was performed with the repeated measures ANOVA and post hoc analysis with the Tukey-Kramer multiple comparisons test.

tween the mean rCBF value obtained from the FAIR image with the intermediate TI (1200 ms) and that obtained from the FAIR image with the longest TI (1600 ms) (Table 3; Fig 2).

Repeated measures ANOVA revealed that the mean rCBF values obtained from the 3 FAIR images were significantly different in the areas where the TTP was more prolonged (dTTP ≥3.2 s). A post hoc analysis revealed that the mean rCBF values obtained from the 2 FAIR images with TIs of 800 and 1200 ms were significantly lower than that obtained from the FAIR images with a TI of 1600 ms (Table 4; Fig 3).

## Discussion

The PASL MR image has been developed recently and allows the CBF to be measured noninvasively without the use of exogenous contrast agents. This MR perfusion technique has been validated in several experimental studies<sup>17–19</sup> and has



**Fig 3.** A stem-and-leaf plot of the rCBFs between the ipsilateral lesions and contralateral normal areas on the 3 FAIR images in the area with more prolonged TTP (dTTP ≥3.2 s) (FAIR, 800 ms; TI, 800 ms; FAIR, 1200 ms; TI, 1200 ms; FAIR, 1600 ms; TI, 1600 ms).

been used to examine patients with ischemic cerebrovascular disease.<sup>20–21</sup> Compared with continuous ASL (CASL), which uses relatively long width radio-frequency (RF) pulses, PASL techniques use nearly instant pulses with comparatively low levels of RF deposition for spin labeling and are particularly advantageous in circumstances in which the specific absorption rate (SAR) imposes a limitation, such as a high magnetic field and pediatric imaging.<sup>22</sup> However, the short half-life of spin-labeled arterial water can complicate the quantification of perfusion on PASL. Labeling must be followed by a delay period (the TI) before PASL MR images are acquired. The loss of contrast as a result of T1 relaxation during transit delay from the labeling site to the tissue of interest can result in an underestimation of CBF unless this delay is taken into account; such underestimation of CBF is more pronounced for brain regions in which perfusion is significantly delayed.<sup>6,7</sup>

An ideal inversion time for PASL yields high tissue signal intensity and minimal intravascular signal intensity. By varying the TI in our patients with unilateral carotid stenosis, we noticed that the perfusion signal intensity was very dependent on the chosen TI, with a decreasing area of perfusion defect at higher values of TI. In the normal hemisphere, the perfusion signal intensity ratio peaks when TI is approximately 1200 ms; however, in the affected hemisphere ipsilateral to the carotid stenosis, the maximum perfusion signal intensity ratio occurs when TI reaches 1600 ms.

The transit delay is related to the fundamental problem that the time required for tagged arterial blood to travel from the tagging region to the capillary is similar to the T1 of blood. This makes it necessary to acquire the image while many dynamic processes are taking place (delivery, exchange, clearance by T1 and flow). If images are acquired too early after application of the tag, then CBF can be underestimated because of the presence of the transit delay.<sup>9</sup> Quantitative imaging of perfusion with a single subtraction-second version (QUIPSS II)<sup>23</sup> is a modification of the basic PASL technique



that can be made insensitive to these sources of error in a dynamic measurement. For applications in pathologic conditions such as stroke or the presence of brain tumors, it is particularly important to use techniques that are insensitive to large variations in transit delay. Wong et al<sup>9</sup> have determined experimentally that transit delay ranges from about 500 to 1500 ms for a physical gap of 1 to 3 cm between the tag region and the imaging section.

In our study, the 3 FAIR images revealed differences in perfusion according to the values of dTTP. The values of rCBF obtained from the 2 FAIR images with a TI of 800 and 1200 ms were significantly lower than those obtained from the corresponding FAIR images with a TI of 1600 ms in the area with more prolonged TTP (dTTP  $\geq$  3.2 s). According to our results of the FAIR imaging study, long TIs should be used to evaluate slow CBF in patients with carotid stenosis. Although this recommendation seems to be reasonable, it must be made with some caution because there are limitations of the current comparison with DSC MR imaging, and no reliable standard reference is used.

Arbab et al<sup>21</sup> reported a correlation between the single-section FAIR perfusion images and contrast-enhanced dynamic perfusion MR images and found a good correlation between FAIR and relative CBF. In our study, we used the TTP method to quantify the blood flow transit delay and to assess errors in CBF measurement from PASL imaging. TTP is a simple measure of perfusion that calculates the time it takes for the bolus of contrast to reach its maximum concentration in a given region of the brain.<sup>24,25</sup> This technique was shown to be highly vulnerable to steno-occlusive disease and can be concluded to be less reliable in the presence of steno-occlusive vascular disease. However, this simple parameter is straightforward to compute and thus has become widely popular in clinical practice. Moreover, some of the methods of deconvolution were also vulnerable to the presence of steno-occlusive disease, which may have been caused by the misrepresentation of the selected arterial input function (AIF) for the flow at the affected area of the brain.

Although it is ideal to analyze each pixel with the AIF of its own feeding artery, this is not clinically feasible because a large number of AIFs will be required. Thus, an AIF is typically chosen from a single location, such as the ICA or MCA contralateral to the side of the infarct.<sup>26,27</sup> However, in the evaluation of a patient with steno-occlusive disease, the AIF chosen from the contralateral vessel may not represent the AIF of the ipsilateral hemisphere, where there may be significant distortion of the curve. The resultant mean transit time (MTT) images will tend to overestimate the region of abnormal flow, resulting in lower specificity. Conversely, when the AIF is chosen from the peri-infarct arteries, higher specificity to the local flow disturbances is obtained, because the AIF corrects for the contrast delay and dispersion that occur distal to the vascular stenosis.

In our study, the reproducibility for selection of the AIF from the artery from the affected side, including the peri-infarct artery, between the 2 observers was not high. Therefore, we finally decided to use the TTP map as a comparative transit time parameter, and the use of the TTP method as an indicator of transit delay was a limitation of our study. However, we did not consider the TTP map as the criterion standard for transit

time but simply compared the PASL with the TTP commonly used perfusion parameter of a DSC MR image. Only a few of our patients had a severe degree (>70%) of stenosis, which could affect the determination of the TTP by a delay and dispersion.<sup>28</sup> Second, we used multisection FAIR images in our study. In a multisection application, increased transit delays to the more distal sections is more prevalent than in a single-section ASL because the transit delay between the tagging region and the more distal sections can be long. Another complication that accompanies multisection ASL is the consistency of the static tissue signal intensity between the tag and control states. Because the perfusion signal intensity is small (<1%), it is critical that the subtraction of static tissue signal intensity between the tag and control states be accurate. In both CASL and PASL, only 1 section location receives exactly the same radio-frequency radiation in the tag and control states. Third, the relatively low signal-to-noise ratio of FAIR images means that there is high variability among different observers with respect to their analysis of ROI. In our study, we reduced this variability by acquiring the 3 FAIR images at the same locations where the DSC MR image was acquired and by using the same size ROI in each image. Finally, the relatively small sample size may have reduced the probability of detecting a statistically significant relationship between the values of rCBF obtained by using the 3 different FAIR images with different TIs.

Attempting to use the same TI in both the healthy control and carotid stenosis groups was not ideal. Inversion timings in PASL must be optimized to receive maximum perfusion-weighted tissue signal intensity, and these times may differ between the healthy controls and patients with carotid stenosis.

## Conclusion

A FAIR with an intermediate or short TI underestimates the perfusion in the area of significant TTP delay (dTTP  $\geq$  3.2 s). Therefore, TI optimization of a FAIR protocol should be considered for perfusion studies in patients with carotid stenosis.

## References

1. Van Osch MJ, Vonken EJ, Bakker CJ, et al. Correcting partial volume artifacts of the arterial input function in quantitative cerebral perfusion MRI. *Magn Reson Med* 2001;45:477–85
2. Belliveau JW, Kennedy DN Jr, McKinstry RC, et al. Functional mapping of the human visual cortex by magnetic resonance imaging. *Science* 1991;254:716–19
3. Detre JA, Leigh JS, Williams DS, et al. Perfusion imaging. *Magn Reson Med* 1992;23:37–45
4. Kwong KK, Belliveau JW, Chesler DA, et al. Dynamic magnetic resonance imaging of human brain activity during primary sensory stimulation. *Proc Natl Acad Sci U S A* 1992;89:5675–79
5. Kim SG. Quantification of relative cerebral blood flow change by flow-sensitive alternating inversion recovery (FAIR) technique: application to functional mapping. *Magn Reson Med* 1995;34:293–301
6. Siewert B, Schlaug G, Edelman RR, et al. Comparison of EPSTAR and T2\*-weighted gadolinium-enhanced perfusion imaging in patients with acute cerebral ischemia. *Neurology* 1997;48:673–79
7. Chalela JA, Alsop DC, Gonzalez-Atavales JB, et al. Magnetic resonance perfusion imaging in acute ischemic stroke using continuous arterial spin labeling. *Stroke* 2000;31:680–87
8. Hendrikse J, van Osch MJ, Rutgers DR, et al. Internal carotid artery occlusion assessed at pulsed arterial spin-labeling perfusion MR imaging at multiple delay times. *Radiology* 2004;233:899–904
9. Wong EC, Buxton RB, Frank LR. Implementation of quantitative perfusion imaging techniques for functional brain mapping using pulsed arterial spin labeling. *NMR Biomed* 1997;10:237–49

10. Wong EC, Luh WM, Liu TT. **Turbo ASL: arterial spin labeling with higher SNR and temporal resolution.** *Magn Reson Med* 2000;44:511–15
11. Detre JA, Samuels OB, Alsop DC, et al. **Noninvasive magnetic resonance imaging evaluation of cerebral blood flow with acetazolamide challenge in patients with cerebrovascular stenosis.** *J Magn Reson Imaging* 1999;10:870–75
12. Arbab AS, Aoki S, Toyama K, et al. **Quantitative measurement of regional cerebral blood flow with flow-sensitive alternating inversion recovery imaging: comparison with [iodine 123]-iodoamphetamine single photon emission CT.** *AJNR Am J Neuroradiol* 2002;23:381–88
13. Arbab AS, Aoki S, Toyama K, et al. **Optimal inversion time for acquiring flow-sensitive alternating inversion recovery images to quantify regional cerebral blood flow.** *Eur Radiol* 2002;12:2950–56
14. **North American Symptomatic Carotid Endarterectomy Trial. Methods, patient characteristics, and progress.** *Stroke* 1991;22:711–20
15. Bamford JM, Sandercock PA, Warlow CP, et al. **Interobserver agreement for the assessment of handicap in stroke patients.** *Stroke* 1989;20:828
16. Buxton RB, Frank LR, Wong EC, et al. **A general kinetic model for quantitative perfusion imaging with arterial spin labeling.** *Magn Reson Med* 1998;40:383–96
17. Hilger T, Niessen F, Diedenhofen M, et al. **Magnetic resonance angiography of thromboembolic stroke in rats: indicator of recanalization probability and tissue survival after recombinant tissue plasminogen activator treatment.** *J Cereb Blood Flow Metab* 2002;22:652–62
18. Hofmeijer J, Schepers J, Veldhuis WB, et al. **Delayed decompressive surgery increases apparent diffusion coefficient and improves peri-infarct perfusion in rats with space-occupying cerebral infarction.** *Stroke* 2004;35:1476–81
19. Schepers J, Veldhuis WB, Pauw RJ, et al. **Comparison of FAIR perfusion kinetics with DSC-MRI and functional histology in a model of transient ischemia.** *Magn Reson Med* 2004;51:312–20
20. Tsuchiya K, Katase S, Hachiya J, et al. **Cerebral perfusion MRI with arterial spin labeling technique at 0.5 Tesla.** *J Comput Assist Tomogr* 2000;24:124–27
21. Arbab AS, Aoki S, Toyama K, et al. **Brain perfusion measured by flow-sensitive alternating inversion recovery (FAIR) and dynamic susceptibility contrast-enhanced magnetic resonance imaging: comparison with nuclear medicine technique.** *Eur Radiol* 2001;11:635–41
22. Wong EC, Buxton RB, Frank LR. **A theoretical and experimental comparison of continuous and pulsed arterial spin labeling techniques for quantitative perfusion imaging.** *Magn Reson Med* 1998;40:348–55
23. Wong EC, Buxton RB, Frank LR. **Quantitative imaging of perfusion using a single subtraction (QUIPSS and QUIPSS II).** *Magn Reson Med* 1998;39:702–08
24. Tsuchiya K, Inaoka S, Mizutani Y, et al. **Echo-planar perfusion MR of Moyamoya disease.** *AJNR Am J Neuroradiol* 1998;19:211–16
25. Sunshine JL, Tarr RW, Lanzieri CF, et al. **Hyperacute stroke: ultrafast MR imaging to triage patients prior to therapy.** *Radiology* 1999;212:325–32
26. Yamada K, Wu O, Gonzalez RG, et al. **Magnetic resonance perfusion-weighted imaging of acute cerebral infarction: effect of the calculation methods and underlying vasculopathy.** *Stroke* 2002;33:87–94
27. Østergaard L, Weisskoff RM, Chesler DA, et al. **High resolution measurement of cerebral blood flow using tracer bolus passages. Part I: Mathematical approach and statistical analysis.** *Magn Reson Med* 1996;36:715–25
28. Neumann-Haefelin T, Wittsack HJ, Fink GR, et al. **Diffusion- and perfusion-weighted MRI: influence of severe carotid artery stenosis on the DWI/PWI mismatch in acute stroke.** *Stroke* 2000;31:1311–17