



Discover Generics

Cost-Effective CT & MRI Contrast Agents



FRESENIUS
KABI

WATCH VIDEO

AJNR

Intracranial Aspergillosis Involving the Internal Auditory Canal and Inner Ear in an Immunocompetent Patient

Y.-S. Cho, D.K. Lee, S.D. Hong and W.S. Oh

AJNR Am J Neuroradiol 2007, 28 (1) 138-140

<http://www.ajnr.org/content/28/1/138>

This information is current as of June 20, 2025.

CASE REPORT

Y.-S. Cho
D.K. Lee
S.D. Hong
W.S. Oh

Intracranial Aspergillosis Involving the Internal Auditory Canal and Inner Ear in an Immunocompetent Patient

SUMMARY: We report the MR imaging findings in a case of intracranial aspergillosis involving the internal auditory canal (IAC) and inner ear in an immunocompetent patient. The presence of rim enhancement of the vestibulocochlear nerve, abnormal signal intensity involving the labyrinth, and adjacent meningeal enhancement might help clinicians to make a correct diagnosis in patients with a mass in the IAC and previous history of ear surgery.

Aspergillosis of the central nervous system (CNS) is a rare condition that usually involves the CNS in immunocompromised hosts, but intracranial aspergillosis has been also reported in immunocompetent patients.¹ Although there have been some cases with successful treatment with amphotericin B,² the reported response rate of CNS aspergillosis to amphotericin B is only 33% in patients with normal immunity.³ In immunocompromised patients, the mortality rate is much higher, nearly 99%.³ Early detection and proper diagnosis are crucial in the treatment of CNS aspergillosis. We present a case of aspergillosis involving the inner ear and the internal auditory canal (IAC) following ear surgery.

Case Report

A 61-year-old man visited our department for evaluation of left facial palsy and progressive hearing loss. He had undergone intact canal wall mastoidectomy and tympanoplasty for control of left chronic otitis media at another hospital about 9 months before the visit to our department. Left facial nerve palsy was detected 6 months after the surgery. Headache, left-sided hearing loss, and facial nerve palsy gradually progressed despite steroid therapy. He was referred to our institution for further evaluation 3 months after development of facial nerve palsy.

Physical examination of the patient revealed marked left facial weakness, even in the resting state, which was consistent with complete facial paralysis. Otoscopic examination showed a postoperative tympanic membrane without any evidence of active inflammation. Vital signs were normal, and comprehensive laboratory data, including blood sampling and chest radiographic findings, were unremarkable. Pure-tone audiometry showed profound sensorineural hearing loss involving the left ear.

We reviewed the MR images from the other hospital, which had been obtained immediately after the development of facial paralysis. T2-weighted MR images revealed some areas of low signal intensity involving the left cochlea and vestibule, replacing the normal high signal intensity of CSF (Fig 1). The left IAC was also filled with abnormal hypointense signal intensity suggesting a mass lesion. Enhanced T1-weighted images showed diffuse enhancement of the lesion in the IAC.

Follow-up MR imaging at our institution was performed. An en-

hanced T1-weighted image revealed abnormal enhancement of the IAC lesion with a nonenhancing region centrally (Fig 2). The spread of the enhancement along the cranial nerve to the brain stem was also noted. Marked meningeal thickening and enhancement were found adjacent to the IAC.

To rule out the possibility of malignancy, we performed positron-emission tomography superimposed on CT (PET/CT). However, PET/CT did not reveal any abnormal fluorodeoxyglucose (FDG) uptake in the left inner ear or IAC. Neither microorganisms nor malignant cells were identified in the CSF analysis, which was performed 15 days after follow-up MR imaging.

On the basis of medical history, physical examination, CSF study, and various imaging studies, the possible differential diagnoses of this lesion included chronic nonbacterial infection, low-grade malignancy, and pseudotumor. The patient underwent open biopsy via translabyrinthine approach. A frozen biopsy specimen from the supralabyrinthine air cells and the IAC showed multiple fungal hyphae in the necrotic neural tissue debris. Meticulous debridement of the lesion in the IAC and the inner ear was performed. The biopsy specimen revealed characteristic branching septate hyphae (Fig 3), and the final pathologic diagnosis was aspergillosis involving the IAC and the inner ear. Intravenous amphotericin B was promptly administered postoperatively. However, the patient had a spiking fever since the second postoperative day. We changed amphotericin B to voriconazole in the fourth postoperative week because of its ability to penetrate the blood-brain barrier and the reported better clinical results in cases of CNS aspergillosis.⁴ Despite intensive postoperative care, fungal vasculitis developed, and the patient died of intraventricular and subarachnoid hemorrhage on the 45th postoperative day.

Discussion

Intracranial involvement by *Aspergillus* species occurs via hematogenous dissemination from the lungs, direct extension from the paranasal sinuses and orbits, or direct introduction at the time of surgery.⁵ Although hematogenous dissemination from a pulmonary focus is frequently seen in immunocompromised patients, extension of disease from the paranasal sinus is more common in immunocompetent people.⁶ In our case, neither the physical examination nor the imaging findings showed any evidence of paranasal sinusitis. Instead, the patient had a history of tympanomastoid surgery approximately 6 months before manifestation of his neurologic symptoms, and the disease occurred on the side of the previous operation. During open biopsy by the translabyrinthine approach, inflammatory tissues containing fungal hyphae were also found in the supralabyrinthine air cells of the temporal

Received August 29, 2005; accepted after revision December 22.

From the Department of Otorhinolaryngology-Head and Neck Surgery (Y.-S.C., D.K.L., S.D.H.) and the Division of Infectious Diseases (W.S.O), Samsung Medical Center, Sungkyunkwan University School of Medicine, Seoul 135-710, Korea.

Please address correspondence to Yang-Sun Cho, MD, Associate Professor, Department of Otorhinolaryngology-Head and Neck Surgery, Samsung Medical Center, Sungkyunkwan University School of Medicine, 50, Ilwon-dong, Kangnam-gu, Seoul, Korea; e-mail: yscho@smc.samsung.co.kr

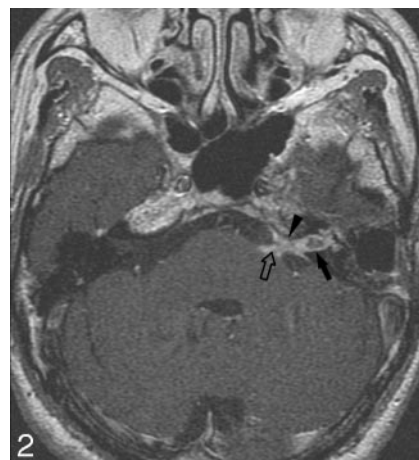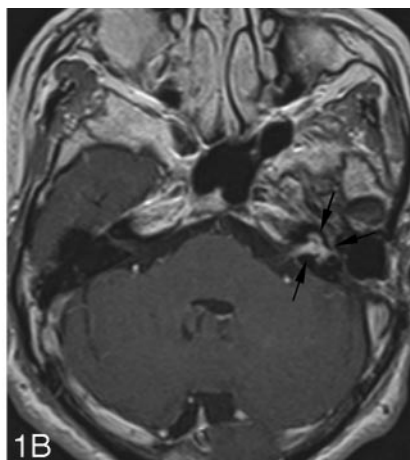
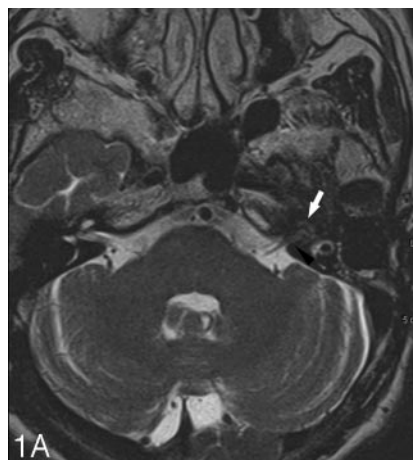


Fig 1. MR images of a patient diagnosed as having aspergillosis involving the left inner ear and IAC. These images were obtained in November 2004.

A, Axial T2-weighted MR image shows an area of low signal intensity replacing normal high signal intensity in the cochlea (white arrow). A soft-tissue masslike lesion filling the left IAC is also seen (arrowhead).

B, Enhanced T1-weighted axial image shows the intense enhancement of the left inner ear and IAC (arrows).

Fig 2. Follow-up MR image obtained in January 2005. Enhanced T1-weighted image shows abnormal enhancement of the IAC with a nonenhancing region centrally (arrow). Markedly thickened dural enhancement is also noted adjacent to the left IAC (arrowhead). The progression of an enhancing lesion toward the brain stem is noted (empty arrow).

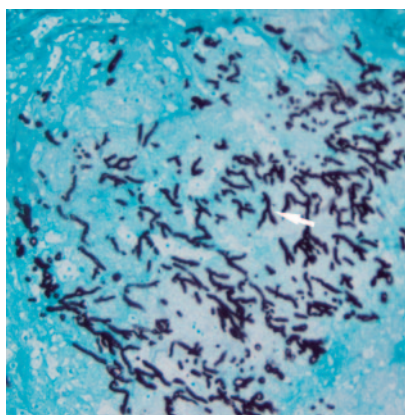


Fig 3. Photomicrograph obtained from histologic examination of the necrotic neural tissue debris from the IAC shows the characteristic branching septate hyphae of *Aspergillus* organisms (white arrow) (Grocott's methenamine silver, original magnification $\times 200$).

bone. Therefore, the mastoid air cells may be a portal of entry for the fungus to the CNS, and we speculate that direct intraoperative inoculation might have been the route of infection in this case. Fungal infection involving the IAC and the inner ear has rarely been reported in cases of invasive systemic fungal dissemination.⁷

PET/CT in our patient failed to show increased FDG uptake of the lesion. In general, inflammatory reactions are shown as areas of increased FDG uptake on PET/CT. However, Hanson et al⁸ showed that metabolism of FDG can be normal in some areas of *Aspergillus* encephalitis. The necrotic nature of the disease might also contribute to the absence of hot uptake in PET/CT. Even in case of malignancy, mainly cystic or necrotic lesions may not show increased FDG uptake on PET/CT.⁹

Reported MR imaging features of intracranial aspergillosis include single or multifocal hemorrhagic lesions involving the cerebral hemispheres, cerebral cortical or subcortical infarcts, multiple ring- or nodular-enhancing abscesses, and dural enhancement adjacent to the paranasal sinuses secondary to direct invasion by sinonasal disease.^{6,10,11} Our patient showed necrotic changes of the involved nerves on MR imaging and in

the surgical findings as well. Considering the angiotrophic nature of *Aspergillus* species regardless of the host's immunity,^{12,13} we believe that such a finding might be explained by the infarction of the vasa nervorum that supplies the nerves in the IAC. Hemorrhage can appear as a hypointense ring on T2-weighted MR images, which was not seen in this patient.¹⁴ The patient died of subarachnoid hemorrhage, which was thought to result from fungal vasculitis.

In terms of host immunity, infectious intracranial lesions show more frequent and prominent ring or nodular enhancement in healthy or mildly immunocompromised patients.^{14,15} In our patient, the initial MR imaging (Fig 1) showed that the cerebral hemispheres were free from disease, and the extent of the disease was localized to the left inner ear and the ipsilateral cranial nerves VII and VIII. When the serial MR imaging studies were reviewed, the progression of the disease seemed rather slow (Fig 2). Furthermore, as one can see on Fig 1, the main lesion in the left IAC revealed marked enhancement on gadolinium-enhanced images. We think that such findings are consistent with the normal immunity of this patient. Diffuse enhancement of the IAC with areas of low signal intensity in immunocompetent hosts was reported to imply the isolation or encapsulation of the offending organism as a form of abscess or granuloma, resulting from the host's defense mechanisms.^{14,15}

Safdar et al¹⁶ reported perineural extension of intracranial aspergillosis from invasive sphenoid sinusitis in an immunocompromised host. In our patient, progression of disease in the MR images can be explained as an initial infection of the labyrinth with subsequent retrograde extension of infection along the vestibulocochlear nerve and the adjacent dura. In the case of Safdar et al, it took several weeks for the disease to extend from the sphenoid sinus to multiple cranial nerves. Our patient showed an even longer interval of 6 months between the ear operation and development of neurologic symptoms. Thus, in immunocompetent patients, the clinical course of the intracranial perineural extension of aspergillosis seems to be rather indolent.

Based on the MR imaging findings, the possible differential diagnosis of intracranial aspergillosis involving the IAC may include metastasis, schwannoma, viral labyrinthitis, and neurosarcooidosis. The presence of meningeal enhancement, abnormal MR imaging signal intensity involving the labyrinth, medical history of a previous ear operation, and the indolent nature of the disease may help remind clinicians of the possibility of intracranial aspergillosis in the immunocompetent host.

References

1. Kim DG, Hong SC, Kim HJ, et al. **Cerebral aspergillosis in immunologically competent patients.** *Surg Neurol* 1993;40:326–31
2. Shuper A, Levitsky HI, Cornblath DR. **Early invasive CNS aspergillosis: an easily missed diagnosis.** *Neuroradiology* 1991;33:183–85
3. Denning DW. **Therapeutic outcome in invasive aspergillosis.** *Clin Infect Dis* 1996;23:608–15
4. Schwarz P, Dromer F, Lortholary O, et al. **In vitro interaction of flucytosine with conventional and new antifungals against *Cryptococcus neoformans* clinical isolates.** *Antimicrob Agents Chemother* 2003;47:3361–64
5. Visudhiphan P, Bunyaratavej S, Khantanaphar S. **Cerebral aspergillosis: report of three cases.** *J Neurosurg* 1973;38:472–76
6. Yamada K, Shrier DA, Rubio A, et al. **Imaging findings in intracranial aspergillosis.** *Acad Radiol* 2002;9:163–71
7. McGill TJ. **Mycotic infection of the temporal bone.** *Arch Otolaryngol* 1978;104:140–44
8. Hanson MW, Glantz MJ, Hoffman JM, et al. **FDG-PET in the selection of brain lesions for biopsy.** *J Comput Assist Tomogr* 1991;15:796–801
9. Ferris RL, Branstetter BF, Nayak JV. **Diagnostic utility of positron emission tomography-computed tomography for predicting malignancy in cystic neck masses in adults.** *Laryngoscope* 2005;115:1979–82
10. Phuttharak W, Hesselink JR, Wixom C. **MR features of cerebral aspergillosis in an immunocompetent patient: correlation with histology and elemental analysis.** *AJNR Am J Neuroradiol* 2005;26:835–38
11. Ashdown BC, Tien RD, Felsberg GJ. **Aspergillosis of the brain and paranasal sinuses in immunocompromised patients: CT and MR imaging findings.** *AJR Am J Roentgenol* 1994;162:155–59
12. Cox J, Murtagh FR, Wilfong A, et al. **Cerebral aspergillosis: MR imaging and histopathologic correlation.** *AJNR Am J Neuroradiol* 1992;13:1489–92
13. Roberts M, Carmichael A, Martin P. **Cerebral vasculitis caused by *Aspergillus* species in an immunocompetent adult.** *Infection* 2004;32:360–63
14. Yamada K, Zoarski GH, Rothman MI, et al. **An intracranial aspergilloma with low signal on T2-weighted images corresponding to iron accumulation.** *Neuroradiology* 2001;43:559–61
15. Okafuji T, Yabuuchi H, Nagatoshi Y, et al. **CT and MR findings of brain aspergillosis.** *Comput Med Imaging Graph* 2003;27:489–92
16. Safdar A, Dommers MP Jr, Talwani R, et al. **Intracranial perineural extension of invasive mycosis: a novel mechanism of disease propagation by *Aspergillus fumigatus*.** *Clin Infect Dis* 2002;35:e50–53