



Discover Generics

Cost-Effective CT & MRI Contrast Agents



FRESENIUS
KABI

WATCH VIDEO

AJNR

Age and Gender Effects on Normal Regional Cerebral Blood Flow

Anne-Sophie Pirson, Thierry Vander Borght and Koen Van Laere

AJNR Am J Neuroradiol 2006, 27 (6) 1161-1163

<http://www.ajnr.org/content/27/6/1161.1>

This information is current as
of June 21, 2025.

Cervical Arterial Collateral Network

Purkayastha et al¹ reported 3 cases of proatlantal intersegmental arteries of external carotid artery origin associated with Galen's vein malformation; however, because of their configuration, I believe that the 3 cases do not demonstrate this rare arterial variation, but rather show collateral blood flow from the occipital artery (OA) to the vertebral artery (VA). In patients with a vein of Galen malformation, the intra-arterial blood pressure in the VA is lower than that in the OA because of blood steal phenomenon at the malformation. It is well known that there is a cervical arterial collateral network between OA, VA, and the deep cervical artery arising from the subclavian artery.² If one of these arteries is occluded, the remaining arteries and their branches are dilated and supply the distal segment of the occluded artery. The 3 cases reported by Purkayastha et al have a similar condition to proximal VA occlusion and therefore should not be considered proatlantal arteries.

References

1. Purkayastha S, Gupta AK, Varma R, et al. **Proatlantal intersegmental arteries of external carotid artery origin associated with Galen's vein malformation.** *AJNR Am J Neuroradiol* 2005;26:2378–83
2. Bosniak MA. **Cervical arterial pathways associated with brachiocephalic occlusive disease.** *AJR Am J Roentgenol* 1964;91:1232–44

A. Uchino

Department of Radiology

Saga Medical School

Saga, Japan

Reply:

The proatlantal artery of external carotid artery origin ascends lateral to the transverse processes of the first cervical vertebra in the neck up to the medial aspect of the mastoid process to join the vertebral artery as seen in the anteroposterior view. In the lateral view, it ascends obliquely posterosuperiorly and passes at the level of the foramen transversarium of the atlas. The type II proatlantal artery arising from the external carotid artery was also described as the first cervical intersegmental artery, which joins the vertebral artery before entering the foramen magnum. Proatlantal arteries also give rise to the occipital arteries. The proatlantal arteries of external carotid artery origin have a similar course to that of the occipital artery. It is doubtful whether the proatlantal artery of external carotid artery origin is merely a hypertrophied collateral occipital artery. This happens when the vertebral artery is hypoplastic. In our patients, however, in the presence of normal bilateral vertebral arteries it is the proatlantal arteries that gave rise to the occipital arteries on both sides. These occipital arteries are smaller in caliber than the proatlantal arteries. This finding also supports the view suggested by Lasjaunias et al¹ that the distal part of the occipital artery might be derived from the proatlantal artery.

S. Purkayastha

Radiology Sree Chitra Tirunal Institute
of Medical Sciences and Technology

Kerala, India

Reference

1. Lasjaunias P, Theron J, Moret J. **The occipital artery.** *Neuroradiology* 1978;15:31–37

Age and Gender Effects on Normal Regional Cerebral Blood Flow

We read with great interest the article of Takahashi et al.¹ The article points out the use of 3D stereotactic surface projections (3D-SSP) to study the age-effect on regional cerebral blood flow (rCBF). The greatest rCBF reduction observed was in the bilateral anterior cingulate. Although we generally agree with the conclusions, we would like to emphasize some methodologic issues that may have had an impact on the obtained results.

In the study, 31 healthy volunteers between 50 and 79 years were classified in 3 different age classes (50–59, 60–69, and 70–79 years). Statistical analysis was performed 2 by 2 by using unpaired Student *t* test. Rather than considering age as a discrete variable, the analysis would have been strengthened by performing a multivariate analysis based on the general linear model with regions as intrasubject factor and sex as inter-subject factor. The sex should also have been considered as a covariate, because rCBF has been shown to be sex dependent in a second order.

In 2004, we presented a similar analysis by using 3D-SSP² of a previously published normal data base constituted of 89 healthy volunteers (46 women and 43 men; age range, 21–81 years) acquired on a triple-head camera.³ By using the previously described multivariate analysis, both age and sex had significant interaction with rCBF. Like Takahashi et al, we found a significant age-related decline ($P < .001$) in the anterior cingulate gyrus and left frontal association cortex, as well as in the left insula and peri-insular cortex. Moreover, we found also a significant relative increased perfusion in the bilateral occipital association and left primary visual cortex. Concerning the sex effect, women showed higher uptake in parietal ($P = .001$) and right sensorimotor cortex ($P = .002$) and a lower uptake in the left temporal associative cortex ($P = .002$). An age-by-sex interaction ($P < .01$) was found only in the left medial frontal cortex, in line with a known higher vulnerability of the left frontal lobe in men compared with women.

Of major importance, although 3D-SSP seems to be better for the analysis of atrophied brain than other analysis methods, it cannot be stated that the partial volume effect can be totally excluded. It is known that the anterior cingulate shows a marked age-related regional atrophy (eg, based on voxel-based morphometry studies).⁴ In the latter study, it was shown that in the anterior cingulate and other regions the changes of perfusion with aging fully paralleled underlying atrophy effects. Therefore, in our opinion, it should be acknowledged that atrophy is not fully taken into account by 3D-SSP and that a direct comparison between partial-volume corrected and uncorrected data should be made to assess to what extent the effect of atrophy on a 3D-SSP analysis is less than other voxel-based techniques such as statistical parametric mapping.

Anne-Sophie Pirson and Thierry Vander Borght

Nuclear Medicine Division

Mont-Godinne Medical Center

Université Catholique de Louvain

Yvoir, Belgium

Koen Van Laere

Nuclear Medicine Division

University Hospital Leuven

Leuven, Belgium

References

1. Takahashi K, Yamaguchi S, Kobayashi S, et al. **Effects of aging on regional cerebral blood flow assessed by using technetium Tc 99m hexamethylpropyleneamine oxime single-photon emission tomography with 3D stereotactic surface projection analysis.** *AJNR Am J Neuroradiol* 2005;26:2005–09
2. Pirson AS, Van Laere K, George J, et al. **A comparative study of age and gender**

effects in an ECD-SPET normal database using fully automated voxel based statistical analysis techniques. *Eur J Nucl Med Mol Imag* 2004;31: S255–56

3. Van Laere K, Versijpt J, Audenaert K, et al. 99mTc-ECD brain perfusion SPET: variability, asymmetry and effects of age and gender in healthy adults. *Eur J Nucl Med Mol Imag* 2001;28:873–87
4. Van Laere KJ, Dierckx RA. Brain perfusion SPECT: age- and sex-related effects correlated with voxel-based morphometric findings in healthy adults. *Radiology* 2001;221:810–17

Reply:

We thank Pirson et al for their interest in our recent article in which we demonstrated a reduction of the regional cerebral blood

flow (rCBF) in the bilateral anterior cingulate gyrus with aging.¹ They made 2 important points. One concerns the effect of sex on rCBF with aging. The other is the effect of brain atrophy with aging on rCBF, especially in the anterior cingulate gyri. To address these concerns, we analyzed our data and examined the effect of aging on rCBF in each sex, by using 3D stereotactic surface projection analysis (3D-SSP). There was reduced rCBF in the bilateral anterior cingulate, right inferior frontal, left superior temporal gyrus, and left posterior cingulate gyrus in women in their 70s compared with those in their 50s (Fig 1A), whereas rCBF was reduced in bilateral anterior cingulate, left precentral lobule, and left uncus in men in their 70s compared with those in their 50s (Fig 1B). Thus, although

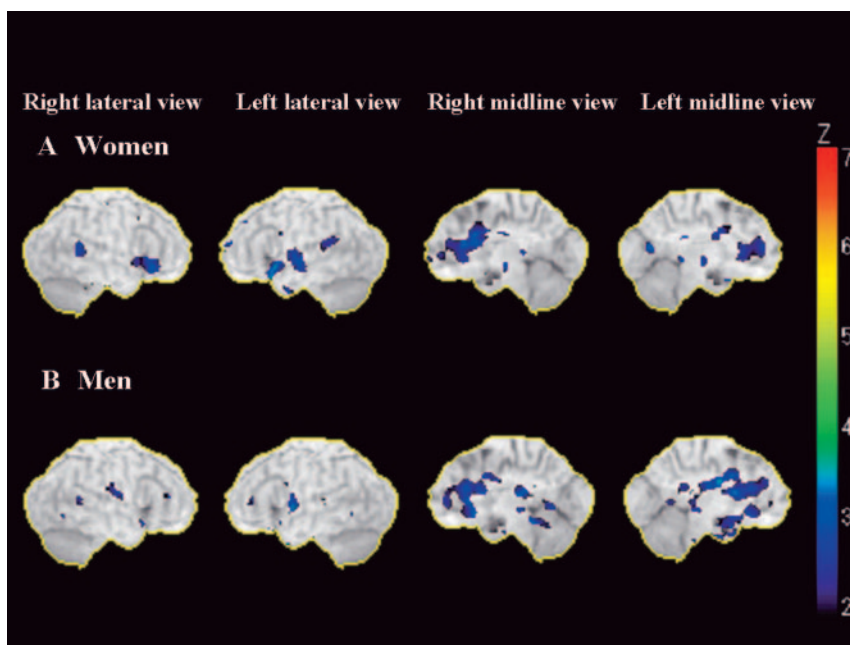


Fig 1. Statistical maps analyzed by using 3D-SSP. The color of the outer contour corresponds to a Z score of 7. The relative decrease in rCBF (Z score of ≤ 2) in subjects 70–79 years of age compared with that in subjects 50–59 years of age (A, women; B, men). A marked reduction of rCBF was observed in the bilateral anterior cingulate gyri in each sex.

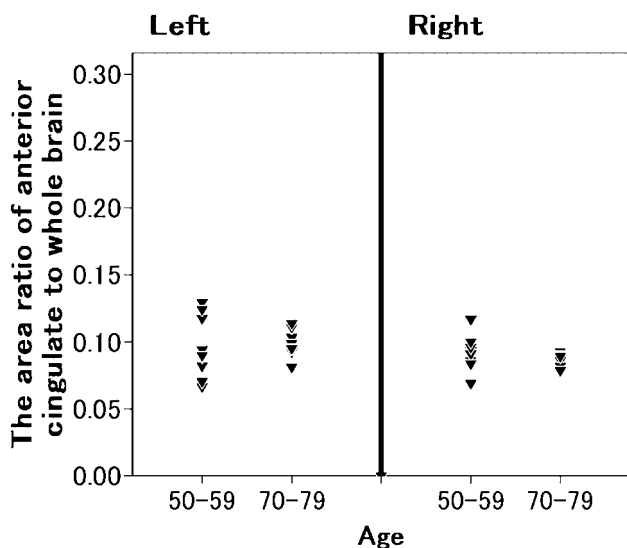


Fig 2. The ratio of the area of the right and left anterior cingulate gyri to that of the entire brain.

there was no sex difference in the reduction of rCBF in bilateral anterior cingulate gyri with aging, we found differential sex effects on age-related rCBF reduction. We conclude, however, that our dataset was too small to reach a firm conclusion about the sex effect.

Next, we investigated the effect of brain atrophy. As Pirson et al stated, the anterior cingulate gyrus tends to atrophy with aging. Therefore, we measured the area of the anterior cingulate gyrus in MR images for each subject, by using National Institutes of Health Image (a software for analysis of medical images, free download page: <http://rsb.info.nih.gov/nih-image/>). Tracing the right and left anterior cingulate gyri and the entire brain of each subject in the sagittal view, we calculated the ratio of the area of the anterior cingulate gyri to that of the entire brain. This measurement yielded no significant difference in the ratio between subjects aged 50–59 years and those aged 70–79 years (Fig 2).

In general, we should always pay attention to the influence of brain atrophy when interpreting 3D-SSP images as suggested by Pirson et al.

Reference

1. Takahashi K, Yamaguchi S, Kobayashi S, et al. Effects of aging on regional cerebral blood flow assessed by using technetium Tc 99m hexamethylpropyleneamine oxime single-photon emission tomography with 3D stereotactic surface projection analysis. *AJNR Am J Neuroradiol* 2005;26:2005–2009

K. Takahashi and S. Yamaguchi

*Departments of Neurology, Hematology, and Rheumatology
Shimane University School of Medicine
Shimane, Japan*

Thyroid Nodules and Other Incidentalomas: We Must Search for Evidence and Clarify Our Ethical Priorities

A thyroid nodule will be incidentally discovered in 10%–60% of adults imaged for other reasons. The overwhelming majority of these lesions will be of no pertinence to the well-being of the patient.¹ This unfortunate discovery may, however, initiate a sequence of events that includes additional imaging studies and biopsies. These investigations are in turn not totally reliable and, short of surgical resection, cannot fully eradicate the implicit concern for the presence of a malignancy. Thyroid cancers are by comparison much less common, with an incidence of 1–10/100,000.² They are usually associated with an indolent course and a good prognosis—life expectancy is little affected in most cases—and, to the best of our knowledge, no one has shown that early diagnosis and treatment in asymptomatic patients imaged for other clinical complaints is beneficial. Thus, the radiologist reporting every nodule he or she encounters may unnecessarily impose on society an excessive financial burden as well as psychological impact on the patients and innumerable surgical resections of questionable justification. Nevertheless, this is just what has been proposed in a recent editorial.³ Had consequences been benign, we could leave such practice run its course, destined to extinction by its own contradictions, but the problems generated are not trivial and deserve a vigorous response.

Our claim is that, through the search for evidence and the clarification of ethical priorities, we can avoid such contradictions and lay foundations of the practice of radiology on firmer ground.

We have long been in an era of scientific medicine. Although we understand the discomfort associated with the suggestion of pretending to be selectively blind to incidental findings, no one has shown the benefits of purposefully screening patients for them. Until evidence is available, the claim that such screening is a responsibility is scientifically false. If an “absolute responsibility” exists, it is to sort out pertinent facts and findings from irrelevant anecdotes in a global, comprehensive assessment of the situation in an effort to come up with the relevant diagnosis and the appropriate treatment of the clinical complaint at hand.

This discussion could be duplicated with other incidental findings, whether they are discovered in the pituitary or adrenal glands or in almost any organ with which nature has provided human beings. Incidentalomas are a persistent problem that increases in frequency with the availability and quality of imaging. To emphasize a duty to screen for incidental findings in an aging population could divert medical care and expenses toward futilities while the risk of favoring iatrogenia on an exponential scale is real.

It may be surprising that one would mandate to search for these false alerts diligently, “no matter what the intended purpose of the study,” without even a mention of some concern regarding the patient’s consent. As far as we know, radiologists have no special waiver to intrude into one’s personal physical and psychological integrity, unless one assumes that any patient who agrees to have his or her carotid evaluated for a potential stenosis is automatically consenting

to be flagged at by the discovery of anomalies, even those that have no proven relevance and about which no one knows for sure what to do. The editorial imposes on us an “absolute responsibility” to do prevention in these cases, but requirements for preventive actions are that the risks of iatrogenia will be low and potential benefits will be proved by a valid trial. Although medicine only has an obligation of means, prevention has an obligation of results. Can we reasonably assume that any rational patient, had he or she been informed of the poor accuracy of imaging in the diagnosis of a malignancy, would have submitted to a screening test he or she had not asked for, to later be stuck against his or her will with a difficult decisional dilemma? This assumption is probably false.

The justification for this “absolute responsibility” to search for thyroid nodules, the editorial argues, is “our priority for reading films over other practitioners and, therefore, the claim for primary reimbursement for that interpretive service.”

First, being paid for doing something as a justification for doing it is not appropriate for physicians. Second, common sense could tell us that “services” that are erroneous in most of the 15%–60% of patients who are flagged are unlikely to be welcomed. Not only is reimbursement a fallacious justification of screening for thyroid nodules, but it is also a type of practice that may justify questioning the judgment of radiologists and the utility of their services.

How is such an ethical and scientific drift possible? The editorial repeatedly demonstrates confusion regarding the objects of the radiologist’s loyalty, mingling “justification for reimbursement” and “responsibility to the patient,” or blending “protection of the patient and physician interests.” In this era of fast-evolving practices, reserving time to reflect about the ethical priorities we are willing to espouse may solve apparent dilemmas of modern imaging. To clarify our opinions regarding the points raised by the editorial, rigid loyalty to the image, no matter what the consequences for the subject, is appropriate for technicians; a practice focused on medical legal concerns is bad medicine; a defense of irrelevant interpretive services can be perceived as corporatism and collaboration with “needy doctors” as quackery. There is no question in our minds that we must offer first and foremost our loyalty to our patients. Then we should practice a scientific medicine. If we stick to these simple principles, we believe our financial compensation will be appropriate and in accordance to our dedication. Our “professional status” would be better supported, and retribution perhaps better assured, by promoting the search for scientific evidence that our services are valuable.

The “inescapable responsibility” of physicians is to ensure that their actions entail more good than harm. Advocates of imaging as screening tests for thyroid malignancy should (1) design the trial that would show the clinical benefit of flagging nodules, aiming at early diagnosis and treatment of asymptomatic cancers present in a very small proportion of these; (2) apply for ethical approval of their institution; (3) obtain informed consent from each subject; and (4) deliver positive clinical results that outweigh complications of this practice before recommending with any authority screening or follow-up imaging plans. For now, at the time of diagnostic studies performed for other indications, unless they present malignant characteristics in a clinical context that is relevant, we feel it is safe for radiologists and clinicians morally concerned about the consequences of their actions, and best for patients, to ignore these misleading thyroid nodules.

References

1. Hegedus L. Clinical practice: the thyroid nodule. *N Engl J Med* 2004;351:1764–71