



Providing Choice & Value

Generic CT and MRI Contrast Agents



**FRESENIUS
KABI**

CONTACT REP

AJNR

**Ellipsoid Approximation versus 3D
Rotational Angiography in the Volumetric
Assessment of Intracranial Aneurysms**

M. Pötin, B. Dagbman, C. Mounayer, L. Spelle and J. Moret

AJNR Am J Neuroradiol 2006, 27 (4) 839-842

<http://www.ajnr.org/content/27/4/839>

This information is current as
of July 29, 2025.

ORIGINAL
RESEARCH

M. Piotin
B. Daghan
C. Mounayer
L. Spelle
J. Moret

Ellipsoid Approximation versus 3D Rotational Angiography in the Volumetric Assessment of Intracranial Aneurysms

BACKGROUND AND PURPOSE: The purpose of this study was to compare the volumetric results of intracranial aneurysms obtained by calculation of the volume of an ellipsoid with those obtained with 3D rotational angiography (3D-RA).

METHODS: First, the precision of 3D-RA in the assessment of volumetric measurement of intracranial aneurysm had to be established. The 3D-RA gave an overestimation of 4% to 5.5% of the actual volume of a spherical object. Then, 484 consecutive human intracranial aneurysms were studied with 3D-RA, allowing the determination of their volume. In the meantime, aneurysm dimensions (height and width) were measured on the 3D pictures generated by the 3D-RA. The aneurysm volumes were calculated (V_{calc}) by considering the aneurysm shape to be ellipsoidal.

RESULTS: The calculated aneurysm volume (V_{calc}) overestimated by $15 \pm 38\%$ the volume given by 3D-RA. Taking into account a 10% margin of error, 227 (47%) aneurysms were overestimated by $44 \pm 34\%$, whereas 113 (23%) aneurysms were underestimated by $25 \pm 12\%$. Only 144 (30%) aneurysms had calculated and 3D-RA results within the limits of 10% of discrepancy. Concordance was good for pericallosal and basilar tip aneurysms (mean overestimation of $6 \pm 22\%$ and $8 \pm 27\%$, respectively). Conversely, there was a high discrepancy between calculated and 3D-RA results for posterior communicating artery aneurysms (mean overestimation of $22 \pm 44\%$).

CONCLUSION: The calculation of the volume based on aneurysm dimensions is relatively accurate for pericallosal and basilar tip aneurysms, probably owing to their spherical or elliptic shape. Conversely, this formula is not adequate for irregularly shaped lesions, such as posterior communicating aneurysms.

The last decade has seen the endovascular treatment of aneurysms gain increasing acceptance within the neurosurgical community, and, in many centers, coiling has become the first-line treatment option for both ruptured and unruptured aneurysms. To assess the degree of aneurysm packing with coils, it has become imperative to determine preoperatively the volume of the aneurysm to be embolized. In many centers, digital subtraction angiography with 3D reconstruction rotational angiography (3D-RA) is now available to serve as a tool to plan the strategy for either surgical or endovascular treatment. This technology gives the capability, by using 3D-RA volumetric measurement, to obtain precise volumetric measurements.^{1,2} Conversely, this capability is not always available, and aneurysm volume calculation is performed under the assumption of the aneurysm as an ellipsoidal geometric form. Previous studies referred to aneurysm volume to assess aneurysm coil packing based on the ellipsoid approximation.³⁻⁵ Many aneurysms are irregularly shaped; so far, there is no definitive evidence of the accuracy of this method of aneurysm volume calculation. To determine whether the aneurysmal volume calculation by using ellipsoid approximation is a valid method, we compared the results obtained with 3D-RA and those obtained with ellipsoid approximation.

Methods

To begin, we had to establish whether our 3D-RA system was precise enough to be able to provide us with accurate volume measurements. As a start, our system was tested with 2 iron balls of 5 and 50 mm in diameter (Fig 1), which were imaged by using the same acquisition parameters routinely used in the clinical setting (Integris 3D-RA; Philips, Best, the Netherlands). The 3D-RA technique overestimated the volume of the 50-mm ball by 4% and that of the 5-mm ball by 5.5% (Fig 2). This small discrepancy between the actual volumes and those obtained with the 3D-RA system software therefore raised concerns and called into question the validity of the latter method. Nevertheless, we accepted the 4% to 5.5% discrepancy as acceptable and decided to use the volume values calculated with the latter methods as the correct values. Then, based upon 498 aneurysms that were consecutively treated selectively with coils in our department from January 2002 to March 2004, 484 had a 3D-RA, which enabled the aneurysm volume measurement before endovascular treatment. This means that, in 14 (3%) aneurysms, the quality of the 3D pictures was insufficient (poor aneurysm filling with contrast material, image blurring) to allow volume determination. Injection protocol was as follows: injection rate of 4 mL/s for a total of iodinated contrast material of 21 mL through a 5F catheter inserted in the proximal internal carotid artery or in the proximal dominant vertebral artery, with a 1-s delay between the beginning of the injection and the beginning of the rotational scan. The aneurysm volume was measured as follows: before the coiling procedure, a rotational angiography with a 17-cm image intensifier was performed. Physical limitations due to blood flow and injection characteristics led to a collection of images that exhibited variable contrast across a single rotational dataset. Each resulting projection image, how-

Received April 25, 2005; accepted after revision August 21.

From the Department of Interventional and Functional Neuroradiology, Fondation Rothschild, Paris, France.

Address correspondence and reprint requests Jacques Moret, MD, Service de Neuroradiologie Interventionnelle et Fonctionnelle, Hôpital de la Fondation Rothschild, 25-29 rue Manin 75940 Paris Cedex 19, France.

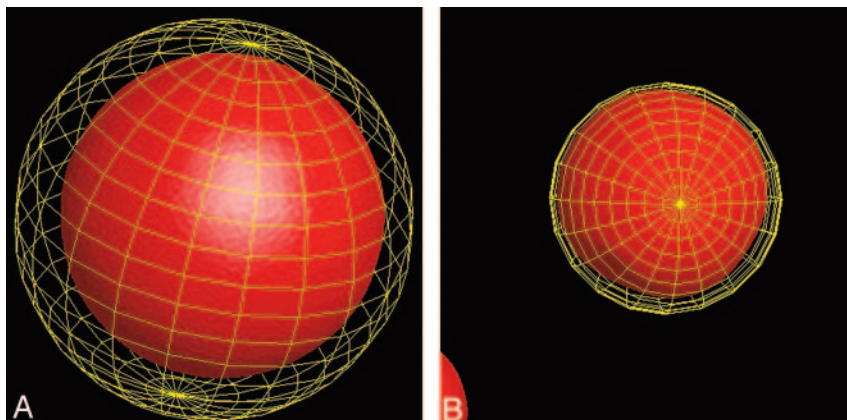


Fig 1. A, Radiograph of the 50-mm-diameter iron ball that served for the calibration of the 3D rotational angiography (3D-RA) system.

B, Radiograph of the 5-mm-diameter iron ball that also served for the calibration of the 3D-RA system.




Fig 2. A, Volume determination with the 3D-RA software of the 50-mm-diameter iron ball displayed with surface-shaded display. The software is giving a volume of 67.875 mm³, whereas the ellipsoid calculation is giving 65.45 mm³.

B, Volume determination with the 3D-RA software of the 5-mm-diameter iron ball displayed with surface shaded display. The software is giving a volume of 69 mm³, whereas the ellipsoid calculation is giving 65.5 mm³.

ever, was then automatically postprocessed with global histogram so that the equalization of each projection image appeared similar in every image of the rotational dataset. A magnification of 33% of the initial 3D dataset was reconstructed in a matrix of 256³. In this magnified 3D reconstruction, the aneurysm was manually segmented from the parent artery, and volume was calculated by using the 3D-RA volumetric measurement of the system software (Fig 3). The manual outlining and segmentation of the aneurysm from the parent artery was performed by the same neuroradiologist (M.P.) for all aneurysms on a prospective basis. The volume of the aneurysm model was automatically given by the built-in software by multiplying the total number of voxels belonging to the segmented aneurysm by the corresponding elementary voxel of the aneurysm volume. In the meantime, the volume (V_{calc}) of each aneurysm was calculated according to the following equation corresponding to the calculation of the volume of an ellipsoid:

$$V_{calc} = \frac{4}{3}\pi\left(\frac{a}{2}\right)\left(\frac{b}{2}\right)\left(\frac{a+b}{4}\right)$$

where a denoted the largest horizontal diameter and b the largest vertical diameter as measured on the 3D-RA images, with a and b being oriented perpendicularly. The locations of the 484 aneurysms were middle cerebral artery ($n = 125$), anterior communicating artery ($n = 116$), posterior communicating artery ($n = 55$), ophthalmic artery ($n = 42$), basilar tip ($n = 35$), supraclinoid (other than posterior communicating and ophthalmic arteries) internal carotid artery ($n = 33$), cavernous sinus ($n = 25$), carotid bifurcation ($n = 23$), pericallosal artery ($n = 11$), laterobasal ($n = 5$), posterior inferior cerebellar artery ($n = 2$), superior cerebellar artery ($n = 5$), vertebral junction ($n = 4$), and posterior cerebral artery ($n = 3$). Of these 484

aneurysms, 385 were <10 mm in maximum size, whereas 99 had a maximum diameter ≥ 10 mm. Mean volume misestimations according to aneurysm location were calculated and compared. Differences in misestimations due to aneurysm location were statistically analyzed by using the Kruskal-Wallis test (nonparametric test of analysis of variance). Differences in misestimation according to aneurysm sizes were statistically analyzed by using the Mann-Whitney test (nonparametric test for continuous variables, which are not normally distributed). P values <.05 were considered significant.

Results

The 484 aneurysms had maximum diameters ranging from 2 to 29 mm (mean, 8 ± 4 mm) with a volume as measured on 3D-RA varying from 4 to 4264 mm³ (mean, 223 ± 436 mm³). Taking into account a maximum discrepancy of 10% between the calculated aneurysm volume (V_{calc}) and the 3D-RA volume, 227 (47%) aneurysms were overestimated by $44 \pm 34\%$, whereas 113 (23%) aneurysms were underestimated by $25 \pm 12\%$. Only 144 (30%) aneurysms had calculation and 3D-RA volumetric measurement results within the limits of 10% of discrepancy (with $0.25\% \pm 6\%$ of accuracy). Concordance was good for basilar tip aneurysms (mean overestimation of $8 \pm 27\%$). Conversely, there was a high discrepancy between mathematical and 3D-RA results for posterior communicating artery aneurysms (mean overestimation of $22 \pm 44\%$). The results according to various aneurysm locations are summarized in the Table. Overall, the V_{calc} overestimated by $15 \pm 38\%$ the volume given by 3D-RA. Although there was no statistically significant difference in aneurysm volume misestimating between the various anatomical locations, the sole variable that statistically correlated with an increased misestimating was an aneurysm size ≥ 10 mm.

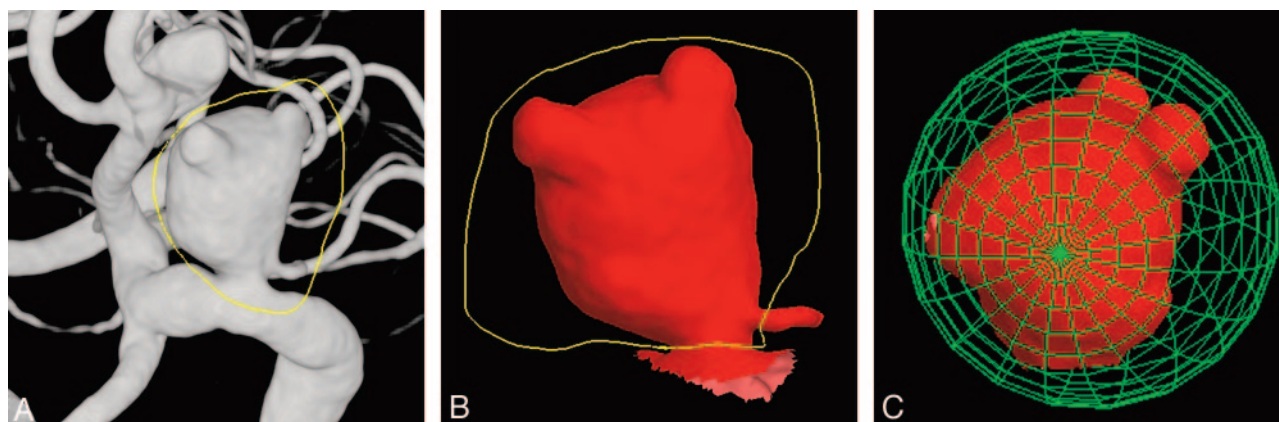


Fig 3. Manual segmentation of a 12-mm large carotid ophthalmic artery aneurysm with the 3D rotational angiography (3D-RA) volumetric measurement software.

A, Volume-rendering display of a 3D-RA representation of the aneurysm obtained after rotational angiography of the right ICA. The gross contour of the aneurysm is first extracted with the cutting graphical tool of the software (yellow line).

B, Cutting of the aneurysm is refined to extract only the contour of the aneurysm (yellow line).

C, Finally, the volume is given by placing the segmented aneurysm inside the sphere giving a volume of 591 mm³, which corresponds to a 34% overestimation provided by the ellipsoid approximation.

Volume misestimating of ellipsoid calculation regarding volume provided by 3D measurements			
	Number	Mean Greater Dimension (mm)	Mean Volume Misestimating (%)
Locations			
MCA	125	7 ± 3	+ 13 ± 41
AcomA	116	7 ± 3	+ 14 ± 37
PcomA	55	7 ± 4	+ 22 ± 44
ICA oph	42	9 ± 5	+ 16 ± 32
Basilar tip	35	8 ± 4	+ 8 ± 27
ICA supra	33	9 ± 5	+ 17 ± 30
Cavernous sinus	25	8 ± 4	+ 19 ± 46
ICA bifurcation	23	7 ± 4	+ 13 ± 33
Pericallosal	11	5 ± 2	+ 6 ± 22
Laterobasilar	5	7 ± 4	+ 24 ± 52
Superior cerebellar	5	4 ± 2	− 11 ± 27
Vertebral	4	13 ± 3	+ 23 ± 18
PCA	3	7 ± 3	+ 43 ± 59
PICA	2	5 ± 0	+ 10 ± 13
Kruskal-Wallis test			
<i>P</i> = .6508			
Sizes			
<10 mm	385	6 ± 2	+ 10 ± 35
≥10 mm	99	13 ± 4	+ 32 ± 44
Mann-Whitney test			
<i>P</i> < .0001			
All sizes and locations	484	8 ± 4	+ 15 ± 38

Note:—MCA indicates cerebral artery; AcomA, anterior communicating artery; PcomA, posterior communicating artery; ICA oph, carotid ophthalmic; ICA supra, supraclinoid internal carotid artery (other than ICA oph and PcomA); PCA, posterior cerebral artery; PICA, posterior-inferior cerebellar artery.

Discussion

Coil packing attenuation has been shown to be a critical factor for the long-term circulatory exclusion of aneurysms.³⁻⁷ Therefore, such endovascular techniques in which implants are used to treat the aneurysmal sac might benefit from the exact quantification of the aneurysm volume to guide the intervention. Moreover, the emergent use of liquid embolic polymers as a potential alternative to coiling in some circumstances might also substantially benefit from the volumetric assessment of the aneurysm cavity.^{8,9} 3D-RA, which consists of the 3D reconstruction of a rotational angiographic dataset,

combines the anatomic resolution of RA with 3D-rendering techniques previously available with only CT or MR angiography. It consists of the computation of 3D voxels from pixels derived from projection images,¹⁰ and, consequently, the precision and accuracy of the 3D reconstruction relies on the realistic and constant representation of the object of interest on the projection images throughout the entire rotational cycle.¹¹ In recent years, 3D-RA has shown to be very effective in the treatment planning, either endovascular or surgical, of aneurysms.¹²⁻¹⁸ It is also superior in the performance of sophisticated tasks, such as measuring the volume of in vitro aneurysms.^{1,2}

Potential Pitfalls of 3D-RA

First, 2 iron balls with diameters of 5 and 50 mm were used to calibrate the system. For this shape, the approximation by an ellipsoid should give the correct volume. The small discrepancy between the real volumes and those given by the 3D-RA software were 4% and 5.5%, respectively. Nevertheless, these small discrepancies should therefore raise concerns and actually question the validity of the latter method. Moreover, the differences between iron and the contrast agent used in interventional procedures might have some influence on the calibration method. We decided, however, to use the volume values calculated with the latter methods as the correct values. The precision of 3D-RA gave a slight overestimation of 4% and 5.5%, but this assertion was based on a single measurement of the 2 iron balls. Thus, the accuracy of the 3D-RA was perhaps overrated. It is also important to notice that 3D-RA volume measurement might have some variability based on display choices made by the operator; however, this variability was probably small, because the same operator performed the volume measurements. To standardize the display of the 3D pictures of the aneurysms, window settings were adjusted to suppress background noise and give sharp delineation of the aneurysm margins. Although the aneurysmal volume calculation was not an accurate method by which to approach the actual volume of the aneurysm, it is important to mention that some clinically relevant issues might reduce the quality of aneurysm filling and subsequently hamper the aneurysm volume

determination obtained in vivo with the 3D-RA.¹⁹ 3D-RA reconstructions may suffer from technical and physiologic limitations that lead to the collection of images with variable contrast across a single rotational dataset.¹¹ Possible distortions of the acquisition system due to equipment vibration, along with the dilution of contrast material during blood flow and the degradation of data due to pulsation and inhomogeneity of the surrounding tissues may hinder image quality. Such degradation generally produces a blurring of the data, which results in more difficult segmentation of the structure of interest, such as an aneurysm. This happened in nearly 3% of aneurysms of our series, where 3D-RA image quality did not allow aneurysm volume determination.

To maximize the filling of the aneurysmal sac with contrast material during the entire rotational cycle, it has been demonstrated that the quality of the bolus contrast material injection (quantity, flow rate) improved visualization of the aneurysms on the 3D reconstructions compared with continuous-flow technique. The quantity and flow rate we used were in accordance with these recommendations.¹⁹ The visualization of saccular aneurysms with 3D-RA relies on the intra-aneurysmal hemodynamics, which depend on the geometric relationship between the aneurysm and the parent artery.^{20–25} In bifurcation and terminal aneurysms, Strother et al²¹ reported a rapid intra-aneurysmal circulation without vortex formation or stasis, whereas in lateral aneurysms, they described a regular flow pattern with inflow at the distal extent of the ostium, slow vortical flow in the center, and outflow along the aneurysm walls. Whereas aneurysms with a bifurcation geometry (such as those found in most lesions in the middle cerebral artery, anterior communicating artery, pericallosal, internal carotid artery bifurcation, basilar tip locations) can be depicted with high accuracy, the visualization of lateral aneurysms (internal carotid artery in the cavernous sinus, ophthalmic, and other supraclinoid aneurysms) with a small neck may suffer sometimes from incomplete contrast filling. This possible restriction may be the source of error in volume measurement, which depends on the homogeneity of contrast in the voxels of the reconstruction volume.

Conclusion

The standard equation of an ellipsoid that is used for the volume calculation of intracranial aneurysm is not valid in most aneurysms that are irregularly shaped. The spread of 3D-RA facilities will help in the exact determination of aneurysm dimensions and volume and will consequently provide more precise results concerning the rate of aneurysm packing whether with coils or other implants.

References

- Piotin M, Gailloud P, Bidaut L, et al. CT angiography, MR angiography and rotational digital subtraction angiography for volumetric assessment of intracranial aneurysms: an experimental study. *Neuroradiology* 2003;45:404–09
- Slob MJ, van Rooij WJ, Sluzewski M. Coil thickness and packing of cerebral aneurysms: a comparative study of two types of coils. *AJNR Am J Neuroradiol* 2005;26:901–03
- Kawanabe Y, Sadato A, Taki W, et al. Endovascular occlusion of intracranial aneurysms with Guglielmi detachable coils: correlation between coil packing density and coil compaction. *Acta Neurochir (Wien)* 2001;143:451–55
- Tamatani S, Ito Y, Abe H, et al. Evaluation of the stability of aneurysms after embolization using detachable coils: correlation between stability of aneurysms and embolized volume of aneurysms. *AJNR Am J Neuroradiol* 2002;23:762–67
- Kai Y, Hamada J, Morioka M, et al. Evaluation of the stability of small ruptured aneurysms with a small neck after embolization with Guglielmi detachable coils: correlation between coil packing ratio and coil compaction. *Neurosurgery* 2005;56:785–92
- Byrne JV, Hubbard N, Morris JH. Endovascular coil occlusion of experimental aneurysms: partial treatment does not prevent subsequent rupture. *Neurol Res* 1994;16:425–27
- Sluzewski M, van Rooij WJ, Slob MJ, et al. Relation between aneurysm volume, packing, and compaction in 145 cerebral aneurysms treated with coils. *Radiology* 2004;231:653–58
- Lubicz B, Piotin M, Mounayer C, et al. Selective endovascular treatment of intracranial aneurysms with a liquid embolic: a single-center experience in 39 patients with 41 aneurysms. *AJNR Am J Neuroradiol* 2005;26:885–93
- Molyneux AJ, Cekirge S, Saatci I, Gal G. Cerebral Aneurysm Multicenter European Onyx (CAMEO) trial: results of a prospective observational study in 20 European centers. *AJNR Am J Neuroradiol* 2004;25:39–51
- Fahrig R, Fox AJ, Lownie S, et al. Use of a C-arm system to generate true three dimensional computed rotational angiograms: preliminary in vitro and in vivo results. *AJNR Am J Neuroradiol* 1997;18:1507–14
- Bidaut LM, Laurent C, Piotin M, et al. Second-generation three-dimensional reconstruction for rotational three-dimensional angiography. *Acad Radiol* 1998;5:836–49
- Hoff DJ, Wallace MC, terBrugge KG, et al. Rotational angiography assessment of cerebral aneurysms. *AJNR Am J Neuroradiol* 1994;15:1945–48
- Anxionnat R, Bracard S, Ducrocq X, et al. Intracranial aneurysms: clinical value of 3D digital subtraction angiography in the therapeutic decision and endovascular treatment. *Radiology* 2001;218:799–808
- Abe T, Hirohata M, Tanaka N, et al. Clinical benefits of rotational 3D angiography in endovascular treatment of ruptured cerebral aneurysm. *AJNR Am J Neuroradiol* 2002;23:686–88
- Hirai T, Korogi Y, Suginozono K, et al. Clinical usefulness of unsubtracted 3D digital angiography compared with rotational digital angiography in the pretreatment evaluation of intracranial aneurysms. *AJNR Am J Neuroradiol* 2003;24:1067–74
- Sugahara T, Korogi Y, Nakashima K, et al. Comparison of 2D and 3D digital subtraction angiography in evaluation of intracranial aneurysms. *AJNR Am J Neuroradiol* 2002;23:1545–52
- Gailloud P, Oishi S, Carpenter J, et al. Three-dimensional digital angiography: new tool for simultaneous three-dimensional rendering of vascular and osseous information during rotational angiography. *AJNR Am J Neuroradiol* 2004;25:571–73
- Ishihara S, Ross J, Piotin M, et al. 3D Rotational angiography: recent experience in the evaluation of cerebral aneurysms for treatment. *Intervent Neuro-radiol* 2000;6:85–94
- Ernemann UU, Gronewaller E, Duffner FB, et al. Influence of geometric and hemodynamic parameters on aneurysm visualization during three-dimensional rotational angiography: an in vitro study. *AJNR Am J Neuroradiol* 2003;24:597–603
- Steiger HJ, Reulen HJ. Low frequency flow fluctuations in saccular aneurysms. *Acta Neurochir (Wien)* 1986;83:131–37
- Strother CM, Graves VB, Rappe A. Aneurysm hemodynamics: an experimental study. *AJNR Am J Neuroradiol* 1992;13:1089–95
- Hashimoto T. Dynamic measurement of pressure and flow velocities in glass and silastic model berry aneurysms. *Neurol Res* 1984;6:22–28
- Graves VB, Strother CM, Partington CR, et al. Flow dynamics of lateral carotid artery aneurysms and their effects on coils and balloons: an experimental study in dogs. *AJNR Am J Neuroradiol* 1992;13:189–96
- Perktold K, Gruber K, Kenner T, et al. Calculation of pulsatile flow and particle paths in an aneurysm-model. *Basic Res Cardiol* 1984;79:253–61
- Gonzalez CF, Cho YI, Ortega HV, et al. Intracranial aneurysms: flow analysis of their origin and progression. *AJNR Am J Neuroradiol* 1992;13:181–88