



Providing Choice & Value
Generic CT and MRI Contrast Agents



CONTACT REP

AJNR

Presumed Bilateral Lateral Geniculate Nuclei Ischemia

Richard K. Imes and Jerome Barakos

AJNR Am J Neuroradiol 2006, 27 (1) 9-11

<http://www.ajnr.org/content/27/1/9>

This information is current as
of July 15, 2025.

"Epidural" Vertebral Venous Plexus

I read with interest the recent case report by Burtis et al regarding findings of MR imaging in craniospinal hypotension.¹ The authors described an enlarged intrathecal spinal vein connecting with engorged "epidural" venous plexus through the intervertebral vein. In addition, the engorged venous system in the intraspinal extrathecal space, prominent in the ventral aspect, has been interpreted to be the "epidural" vein in the previous reports of this disease.²⁻⁴ The veins posterior to the theca, the posterior internal vertebral venous plexus, are exactly situated in the epidural space proper, though the veins anterior to the theca, the anterior internal vertebral venous plexus (AIVVP), are not in the space. The AIVVP consists of 2 longitudinal venous spaces between 2 thin layers of the posterior longitudinal ligament, the superficial (dorsal) and deep (ventral) layers⁵⁻⁷ (Fig 1). The walls of the AIVVP have all 3 layers of a vein: intima, media, and adventitia. Each AIVVP locates in the lateral part of the spinal canal symmetrically, and joins at the midline by retrocorporeal anastomoses. Although existing MR imaging cannot depict the layer relationships, anatomically correct expression of the venous system is desirable.

References

1. Burtis MT, Ulmer JL, Miller GA, et al. Intradural spinal vein enlargement in craniospinal hypotension. *AJNR Am J Neuroradiol* 2005;26:34-38
2. Renowden SA, Gregory R, Hyman N, et al. Spontaneous intracranial hypotension. *J Neurol Neurosurg Psychiatry* 1995;59:511-15
3. Brightbill TC, Goodwin RS, Ford RG. Magnetic resonance imaging of intracranial hypotension syndrome with pathophysiological correlation. *Headache* 2000;40:292-99
4. Clarot F, Callonnec F, Douvrin F, et al. Giant cervical epidural veins after lumbar puncture in a case of intracranial hypotension. *AJNR Am J Neuroradiol* 2000;21:787-89
5. Hayashi K, Yabuki T, Kurokawa T, et al. The anterior and the posterior longitudinal ligaments of the lower cervical spine. *J Anat* 1985;124:633-36
6. Kubo Y, Waga S, Kojima T, et al. Microsurgical anatomy of the lower cervical spine and cord. *Neurosurgery* 1994;34:895-902

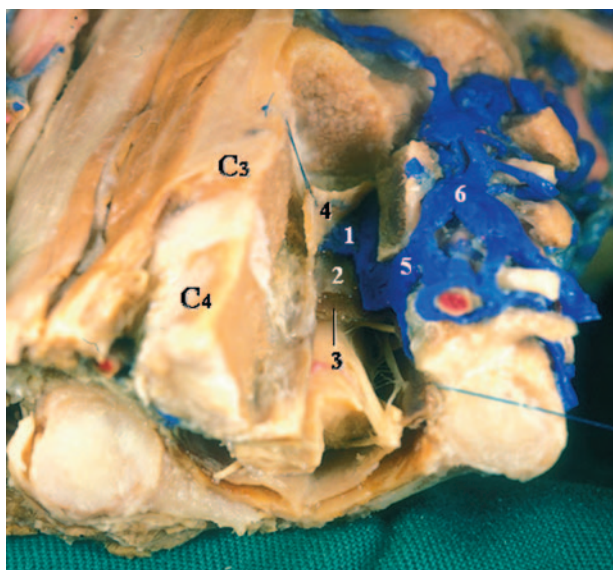


FIG 1. Anterocaudal view of a cadaver specimen after left vertebrectomy shows layer relationships between the AIVVP and surrounding structures. The AIVVP (1) is formed by 2 layers of the posterior longitudinal ligament, the superficial layer (2) just anterior to the dural theca, (3) and deep layer (4). The intervertebral vein (5) and vertebral vein (6) are also shown.

7. Chaynes P, Verdie JC, Moscovici J, et al. Microsurgical anatomy of the internal vertebral venous plexuses. *Surg Radiol Anat* 1998;20:47-51

Satoru Shimizu

Kitasato University School of Medicine
Sagamihara, Kanagawa, Japan

Reply:

After thorough review of Dr. Shimizu's image references and written response to our case report on intracranial hypotension, we are in complete concurrence with his assertion that the anterior internal vertebral venous plexus (AIVVP) is not situated within the epidural space proper. Rather, the AIVVP is within the layers of the posterior longitudinal ligament.

We are grateful for his comprehensive review of the pertinent anatomy in this case and for his letter regarding the error.

Michael Todd Burtis, MD
Tripler Army Medical Center
Honolulu, Ha

Dose Delivery Accuracy from ³²P-Oligodeoxynucleotide-Coated Coils and Associated Risks for Usage in Humans

I read with interest the article by Levesque et al¹ in the June/July issue of the *AJNR* reporting on recanalization of animal model arteries after embolization with ³²P-oligodeoxynucleotide-coated Guglielmi coils. In their report, the authors claim to have developed a method to bind tightly a ³²P 15 mer oligonucleotide to Guglielmi platinum coils that has some advantages compared with ion-implanted coils proposed by an independent group of investigators.² The technique they describe consists of simply "dipping" the platinum coils in a ³²P-oligonucleotide solution with the coil surface adsorption coefficient varying with the solution's temperature. Variability in the total activity attained by this technique as a function of the solution's temperature and the coil length are illustrated in Figures 1 and 2 of their report and indicate a SEM of about $\pm 10\%$, which appears reasonable. Thus, it is tempting to conclude that their new technique for the production of ³²P-coated coils offers ease of production, good accuracy, and reproducibility. Nevertheless, using the SEM instead of the SD in presenting the data can be misleading. This is because the SEM gives an idea of the accuracy of the mean value of a population, whereas the SD gives you an idea of the variability of single observations. The 2 are related by $SEM = SD/(\text{square root of sample size})$. Moreover, a 95% confidence interval in the measured quantities is represented by 2 SD. Using this latter value yields a variability of single observations of greater than $\pm 45\%$ (95% confidence interval) assuming the mean is averaged ≥ 5 experiments. This more meaningful quantity contrasts significantly with the approximately 10% error bar reported in Fig 2 of Levesque et al's report.¹

Human experiments by using ³²P-ion-implanted coils have been reported recently. In these experiments, the coils were ion-implanted, a technique that physically binds the ³²P atoms to the metallic surface with negligible leaching. Ion implantation yields coils with activities that can be measured accurately within $\pm 5\%$ (SD) by using standard counting techniques. Also, because there is no leaching of the ³²P, the dose can be predicted accurately (usually within $\pm 10\%$ SD) because the radioactive decay from the coil surface is due entirely to the physical decay with a half-life of 14.3 days for ³²P. This level of accuracy is within the typical standards usually found in intravascular brachytherapy (IVB), and is critical for the safety and potential success of the ³²P coil treatment in humans.²

In contrast, a ^{32}P -“dipped” coil is comparable to a local drug delivery device where the coated drug is slowly eluted from the device in a less predictable manner, resulting in large uncertainties in the coil activity, distribution, and residence time of the ^{32}P at the target site. This results in large uncertainties in predicting the radiation dose that is actually delivered to the tissues. The reasons for this have been expressed in detail in a recent publication about the dosimetry of ^{32}P -oligonucleotide-“dipped” stents for the treatment of restenosis.³ In brief, a conventional IVB source (eg, ^{32}P -ion-implanted stents or coils without any leaching) is characterized by physical factors that can be measured accurately (eg, activity, geometry), which yield accurate dose calculations. In contrast, for a drug-eluting device (stent or coil), the amount of radioactivity deposited in the tissues is strongly dependent on biologic factors (drug uptake, washout rate, residence time, diffusion) that can fluctuate significantly from patient to patient. This makes it virtually impossible to predict accurately the dose that is delivered to the tissue during the experiment (not even within $\pm 50\%$), falling short of the standards of quality of conventional brachytherapy. Drug leaching from dipped coils will also result in a small but unnecessary dose to healthy organs. On the basis of these arguments, we conclude that ^{32}P -oligonucleotide-dipped coils are not a valid alternative to ion-implanted coils. Their usage in humans is risky, because it is unlikely that the prescribed radiation dose can be delivered accurately and effectively because of the low predictability and reproducibility of the drug-elution parameters.

References

1. Levesque L, Gauthier F, Raymond J, et al. ^{32}P -oligodeoxynucleotide-coated coils to prevent arterial recanalization after embolization. *AJNR Am J Neuroradiol* 2004;25:1062–66
2. Raymond J, Roy D, Leblanc D, et al. Endovascular treatment of intracranial aneurysms with radioactive coils: initial clinical experience. *Stroke* 2003;34:2801–806
3. Janicki C, Hwang C-W, Edelman ER. Dose model for stent-based delivery of a radioactive compound for the treatment of restenosis in coronary arteries. *Med Phys* 2003;30:2622–26

Christian Janicki, PhD
McGill University Health Center

Reply:

We are grateful to Dr. Janicki for showing in interest in our recent article in the *AJNR*.¹ Ion implantation does provide a means to better fix the isotope onto the coils, though some in vitro and in vivo leaching is still possible.² We doubt that leaching of a fraction of activities of ^{32}P prescribed to prevent recanalization, with subsequent biodistribution, represents a definite health hazard, but a policy of minimizing such unnecessary exposure is certainly prudent. Perhaps more important, one can rely on ion-implanted coils to deliver and keep activities at the target site with more accuracy and better assure the efficacy of the strategy. In light of the steep nature of the dose/distance curve obtained with beta radiation, the uncertainties regarding the anatomy of the target tissues and the impossibility of determining a priori the exact position of the coils before their in vivo deployment, any in situ beta radiation strategy will always involve difficulties in dose calculations. Nevertheless, approximations are possible—no matter their exact disposition, most coils will be confined to the aneurismal sac—and perhaps sufficient to prescribe activities according to a “therapeutic window.”^{3,4} Whether the risks involved with such approximations are worth taking depends on the expected benefits of the strategy and the comparative efficacy and risks of clinical alternatives.

The article describes a method to circumvent the problem of the half-life of ^{32}P (2 weeks) entailing conceptual difficulties in the management of coil inventories. The challenge is to deliver active coils promptly in centers throughout the world. Other methods to do so while conserving the advantages of ion implantation may exist, but they involve other difficulties.⁴ No matter how effective a new treatment may be in the laboratory, it cannot have any clinical impact if it does not reach the patient for whom it was designed. It is an unfortunate but uncontrollable fact that new devices will not be put into clinical use unless they entail profits to an organization. Nevertheless, we have failed thus far to convince the industry that ion implantation of endovascular coils could be a profitable enterprise. There are many drawbacks to the method described, but it did provide coils that were effective in preventing recanalization in experimental arterial occlusion models, a feat that remains unchallenged by coils available on the market.

References

1. Levesque L, Gauthier F, Raymond J, Leclerc G. ^{32}P -oligodeoxynucleotide-coated coils to prevent arterial recanalization after embolization. *AJNR Am J Neuroradiol* 2004;25:1062–66
2. Leblanc P, Raymond J, Roorda S. Production and characterization of ^{32}P -radioactive platinum coils by ion-implantation for endovascular treatment of intracranial aneurysms. *Nuclear Instruments and Methods in Physics Research. Section B: Beam Interactions with Materials and Atoms*. 2005;242:173–78
3. Raymond J, Leblanc P, Morel F, et al. Beta radiation and inhibition of recanalization after coil embolization of canine arteries and experimental aneurysms: how should radiation be delivered? *Stroke* 2003;34:1262–68
4. Mounayer C, Pötin M, Moret J, et al. Radioactive coil embolization of intracranial aneurysms: minimal inventory to reach target activities in a virtual series of 154 patients. *AJNR Am J Neuroradiol* 2004;25:1377–80

Jean Raymond
Philippe Leblanc
Luc Levesque
Guy Leclerc
CHUM Notre-Dame Hospital
Montreal, Canada

Platelet Receptors

I read with great interest Aviv et al’s “Abciximab in Patients with Ruptured Intracranial Aneurysms.”¹ I would like to point out that the mechanism of action of abciximab on platelets has been worked out in detail and there are multiple receptors on platelets which work in concert to seal a ruptured vessel. The authors suggest that abciximab may disrupt the newly formed thrombus sealing a ruptured aneurysm. Although abciximab can lyse an aggregate of platelets by disrupting platelet to platelet adhesion, the platelet-to-endothelium adhesion occurs via a receptor not affected by abciximab. It is the GP IIb/IIIa complex. This complex allows a platelet monolayer to form and obtain hemostasis at a site of disrupted endothelium without platelet aggregation.²

In addition, the authors suggest that the use of a short-acting GP IIb/IIIa inhibitor (eptifibatide) is favorable to a longer-acting IIb/IIIa inhibitor (abciximab). It has been shown that eptifibatide has a longer plasma half-life than abciximab, a shorter receptor blockade, and a lower affinity for the IIb/IIIa complex. This results in a longer platelet-bound half-life for abciximab, but a shorter plasma half-life. The unattached abciximab is rapidly cleared, as compared with eptifibatide, which is cleared by the kidneys and affected by creatinine clearance. The decreased affinity of eptifibatide for the IIb/IIIa receptor results in rapid binding to the platelet and then rapid dissociation. This leads to the prolonged plasma half-life and also negates any attempts at reversal. Because of abciximab’s high affinity for the IIb/IIIa receptor,

abciximab is reversible with platelet transfusion. On the basis of these findings, it may be suggested that complications may be reduced by the use of abciximab as opposed to the suggested eptifibatide.

References

1. Aviv R, et al. **Abciximab in patients with ruptured intracranial aneurysms.** *AJNR Am J Neuroradiol* 2005;26:1744–50
2. Shlansky-Goldberg S. **Platelet aggregation inhibitors for use in peripheral vascular interventions: what can we learn from the experience in the coronary arteries?** *J Vasc Interv Radiol* 2002;13:229–46
3. Connors JJ. **Pharmacologic agents in stroke prevention, acute stroke therapy, and interventional procedures.** *J Vasc Interv Radiol* 2004;15:S87–101

Paul Blom
Michael Korona
Lee Haikal
*Radiology Incorporated
Huntington, WV*

Reply:

We thank Dr. Blom for his interest in our article and pertinent comments. We should, however, clarify that the etiology of thrombus at the time of aneurysm coil treatment depends on not only endothelial platelet interactions mediated through GP Ib/IX, but also platelet-platelet interaction resulting from subsequent platelet activation and a conformational change in the GP IIb/IIIa site.¹ Altered intravascular and intra-aneurysmal hemodynamics, presence of foreign material, and possibly electrothrombosis contribute further to platelet interaction and thrombosis. In these circumstances the acute clot formed is platelet rich and highly susceptible to the GP IIb/IIIa inhibitors. We demonstrated the reappearance of an aneurysm neck in case 2 after abciximab administration, which we interpreted as facilitated platelet dysaggregation in a freshly thrombosed portion of the aneurysm.

Dr. Blom correctly highlights the difference in binding characteristics between abciximab and eptifibatide. Clearly, their use is predicated by several clinical factors. A higher affinity binding agent (abciximab) is desirable for prevention of platelet aggregation, but in the context of platelet disaggregation a low-affinity compound (eptifibatide) is able to dissociate a greater number of platelets in a given time.² Despite a longer plasma half-life, the competitively binding, smaller-molecular-weight inhibitors have a shorter receptor blockade and therefore require greater and longer infusions to maintain adequate blockage.³ As a result, emergent and elective surgery may be performed immediately or following a 2–4-hour duration for eptifibatide and 12-hour or 1–2-day delay for abciximab. The smaller-size compounds may allow superior penetration through fibrin-fibrinogen networks, potentially contributing to superior potency² and both short-acting inhibitors are less expensive than abciximab.⁴

Thrombocytopenia occurs more frequently in patients with abciximab (1%–5%) than the other inhibitors.⁵ Furthermore, antibody production against abciximab is described as raising theoretical concerns for autoimmune response following exposure, though repeat administration appears to be safe⁶

In clinical practice (in the absence of renal failure), these differences do not seem to affect drug preference, and the GP IIb/IIIa inhibitors remain an effective treatment of intraprocedural thrombotic complications.

References

1. Shlansky-Goldberg R. **Platelet aggregation inhibitors for use in peripheral vascular interventions: what can we learn from the experience in the coronary arteries?** *J Vasc Interv Radiol* 2002;13:229–46

2. Moser M, Bertram U, Peter K, et al. **Abciximab, eptifibatide, and tirofiban exhibit dose-dependent potencies to dissolve platelet aggregates.** *J Cardiovasc Pharmacol* 2003;41:586–92
3. Connors JJ 3rd. **Pharmacologic agents in stroke prevention, acute stroke therapy, and interventional procedures.** *J Vasc Interv Radiol* 2004;15:S87–101
4. Hillegass WB, Newman AR, Raco DL. **Economic issues in glycoprotein IIb/IIIa receptor therapy.** *Am Heart J* 1999;138:S24–32
5. Dasgupta H, Blankenship JC, Wood GC, et al. **Thrombocytopenia complicating treatment with intravenous glycoprotein IIb/IIIa receptor inhibitors: a pooled analysis.** *Am Heart J* 2000;140:206–11
6. Madan M, Kereiakes DJ, Hermiller JB, et al. **Efficacy of abciximab readministration in coronary intervention.** *Am J Cardiol* 2000;15:85:435–40

Richard Aviv
*Sunnybrook & Women's College
Health Sciences Centre
Toronto, Canada*

Presumed Bilateral Lateral Geniculate Nuclei Ischemia

We read with interest the report by Lefebvre et al,¹ of a case of severe bilateral visual loss after anaphylactic shock associated with isolated, symmetric, bilateral lateral geniculate nucleus (LGN) lesions on MR imaging studies. They concluded their patient's visual loss was caused by isolated ischemia of the LGN from shock-induced hypotension. They stated the LGN can be considered part of the watershed region of the brain because of its proximity to this vascular border zone, even though ischemic damage to the LGN from prolonged hypoxia had never been reported.

We believe isolated extrapontine myelinolysis, or osmotic demyelination, is a more plausible explanation for their patient's symmetric bilateral LGN lesions and visual loss. Central and extrapontine myelinolysis has been reported after resuscitation for anaphylactic shock.²

In 1987, Gocht and Colmant³ reported their findings in 58 autopsied cases of central and extrapontine myelinolysis, and found the LGN was the second-most-common extrapontine site of myelinolysis, occurring in 14 of 47 nuclei they examined. They reported that extrapontine lesions could occur in the absence of central pontine lesions.

In his review of the osmotic demyelinating disorders, Brown⁴ noted that central and extrapontine myelinolysis occurs in at-risk patients who are given intravenous fluids for treatment of an underlying disease. Osmotic demyelination can occur even when serum sodium levels are normal.

One of us (R.K.I.) reported a patient with presumed intrageniculate myelinolysis after near-fatal uterine hemorrhage and hysterectomy⁵ whose MR imaging appearance and visual field findings were strikingly similar to the patient reported by Lefebvre et al.¹ Even though that patient's serum sodium levels remained within normal limits, rapid shifts in calculated serum osmolality were demonstrated.

The acute demyelinating lesions seen on MR imaging studies in patients with osmotic demyelination are symmetric, hypointense on T1-weighted images, hyperintense on T2-weighted images (T2WI) and on fluid-attenuated inversion recovery images, and enhance with gadolinium. We believe the small hypointense areas seen on the coronal gradient echo T2WI in the patient reported by Lefebvre et al¹ are consistent with acute necrosis but do not indicate cause.

Originally a neuropathologic diagnosis, central and extrapontine myelinolysis have increasingly become neuroradiologic diagnoses, because most patients survive and some even recover completely. Without neuropathologic confirmation, we can only speculate about

the cause of these patients' spectacular LGN lesions and visual loss. We believe, however, that the evidence favors extrapontine myelinolysis, not ischemia.

References

1. Lefebvre PR, Cordonnier M, Baleriaux D, et al. **An unusual cause of visual loss: involvement of bilateral lateral geniculate bodies.** *AJNR Am J Neuroradiol* 2004;25:1544–48
2. Stanescu I, Zahar JR, Brugières P, et al. **Paucisymptomatic and reversible myelinolysis after an anaphylactic shock.** *Rev Neurol (Paris)* 2002;158:1118–20
3. Gocht A, Colmant HJ. **Central pontine and extrapontine myelinolysis: a report of 58 cases.** *Clin Neuropathol* 1987;6:262–70
4. Brown WD. **Osmotic demyelination disorders: central pontine and extrapontine myelinolysis.** *Curr Opin Neurol* 2000;13:691–97
5. Imes RK, Kutzscher E, Gardner R. **Binasal hemianopias from presumed intrageniculate myelinolysis: report of a case with MR images of bilateral lateral geniculate involvement after emergency cesarean section and hysterectomy.** *Neuroophthalmology* 2002;28:45–50

Richard K. Imes
Jerome Barakos
California Pacific Medical Center
San Francisco, Calif

Reply:

We read with interest the letter by Imes and Barakos. The case Imes reports¹ is indeed strikingly similar to ours; however, although we can only speculate about it, we conclude that ischemia caused the lateral geniculate nuclei (LGN) lesions in our case.

Visual impairment has indeed been noticed within the first 24 hours after shock. Onset of symptoms during central pontine myelinolysis (CPM) is typically delayed from 2 to 7 days.¹ Our patient was in otherwise good health and did not have underlying conditions^{2–4} such as alcoholism, malnutrition, liver or kidney deficiency, neurologic disease, or malignancy, which are commonly seen in case of CPM or extrapontine myelinolysis (EPM). She developed no neurologic symptom pointing to a pons lesion, and neurologic examination was unremarkable. Serum sodium level remained within the normal range, at the emergency department (143 mEq/L) and at days 1 and 5 after shock (140 and 138 mEq/L, respectively). Shock resolved promptly with intravenous adrenaline and methylprednisolone. No massive intravenous fluid was administered. MR imaging demonstrated lesions located exclusively within both LGN. The similarity between our case and that of Imes et al¹ is the hyperintense aspect on T2-weighted images (T2WIs), but the major difference is the evolutionary aspect on T1-weighted images (T1WIs). This latter aspect on T1WIs, but also on T2WIs, points toward an ischemic origin with a hemorrhagic component.^{5,6} Moreover, lesions enhanced after gadolinium (Gd) injection on the images obtained at day 6, which is again a normal finding in case of ischemia.^{5,6} In viewing the T1WI at first (day 1), no abnormalities were seen. In contrast, on day 16 lesions were hyperintense on T1WI and hypointense on gradient echo T2WIs and, thus, strongly suggest the hemorrhagic nature of the lesions in our patient. On day 51, lesions were still hyperintense on T1WIs, and

hypointensity remained on gradient echo T2WIs, which is still in accordance with the findings reported in cases of hemorrhagic ischemia.^{5,6} Twelve months later, T1WIs returned to normal, as well as T2WIs and fluid attenuated inversion recovery images, but hemosiderin deposits were still perceptible thanks to gradient echo T2WI. The evolutionary aspect of our lesions, as seen on MR images, are in complete concordance with what is reported on MR imaging in cases of hemorrhagic infarct.^{5,6} To the best of our knowledge, this hemorrhagic aspect has never been described in myelinolysis.⁴ The clinical features and the typical aspect on MR imaging leads us to conclude still that the possible origin in the case we reported is ischemia rather than myelinolysis. In contrast, hypointense areas are seen on T1WIs in cases of acute myelinolysis, but nonhemorrhagic ischemic lesions behave the same way.^{5,6} Table 1 states the evolutionary aspects of the MR images in our case.

Moreover, the hypothesis of ischemia is supported by an experimental study on rats by Bauman et al⁷ They demonstrated that fluid percussion injury cause neuronal death in several thalamic nuclei, which are located within watershed areas, and that additional hypoxemia worsens cell loss in the dorsal LGN. The dorsal part of LGN seems to be more vulnerable to hypoperfusion because blood vessels enter the ventral surface and then run vertically through the LGN to end.⁸

To the best of our knowledge, there is no report on CPM affecting exclusively the LGN, except the case of Imes et al. Stanescu et al³ describe hyperintense lesions on T2WIs within the brain stem, the thalami, and the cerebellum after an anaphylactic shock. They do not mention the aspect on T1WIs, and lesions are not located within the LGN. Gocht and Colmant⁴ examined 58 brains with CPM. LGN myelinolysis was present in only 4/58 (7%), and their report does not mention whether these lesions were isolated or associated with EPM elsewhere. The authors they refer to never faced isolated LGN myelinolysis.

The article by Imes et al¹ is particularly interesting to us because of the striking similarities with ours in terms of vascular collapse, visual field defects, and isolated lesions within both LGN. Their case, however, seems to differ from ours in terms of delay for symptoms and recovery, massive intravenous fluids given, and the evolutionary aspects of the lesion on MR imaging. Ischemia in our case seems the most appropriate causative agent having led to LGN dysfunction.

References

1. Imes R, Kutzscher E, Gardner R. **Binasal hemianopias from presumed intrageniculate myelinolysis: report of a case with MR images of bilateral lateral geniculate involvement after emergency cesarean section and hysterectomy.** *Neuroophthalmology* 2002;28:45–50
2. Goldman J, Horoupian D. **Demyelination of the lateral geniculate nucleus in central pontine myelinolysis.** *Ann Neurol* 1981;9:185–89
3. Stanescu I, Zahar J, Brugières P, et al. **Myélinolyse paucisymptomatique et réversible après un choc anaphylactique.** *Rev Neurol (Paris)* 2002;158:1118–20

Evolution of the signal intensity within the LGN on MR images

	T1	Gadolinium Enhanced	T2	FLAIR	Gradient Echo T2	Diffusion
Day 1	Normal	Normal	Hyperintense	Hyperintense	ND	ND
Day 6	Normal	Hyperintense	Hyperintense	Hyperintense	ND	ND
Day 16	Hyperintense	Hyperintense	ND	Hyperintense	Hypointense	Normal
Day 51	Hyperintense	Hyperintense	Normal	Normal	Hypointense	ND
12 Months	Normal	Normal	Normal	Normal	Hypointense	ND

Note:—LGN indicates Lateral geniculate nuclei; ND, not done.

4. Gocht A, Colmant H. **Central pontine and extrapontine myelinolysis: a report of 58 cases.** *Clin Neuropathol* 1987;6:262–70
5. Zimmerman RA, Gibby WA, Carmody RF. *Neuro-imaging: clinical and physical principles.* New York: Springer-Verlag;2000:791–96
6. Grossman RI, Yousem DM. *Neuroradiology: The requisites.* St Louis: Mosby; 2003:183–96, 217
7. Bauman R, Widholm J, Petras J, et al. **Secondary hypoxemia exacerbates the reduction of visual discrimination accuracy and neuronal cell density in the dorsal lateral geniculate nucleus resulting from fluid percussion injury.** *J Neurotrauma* 2000;17:679–93
8. Fujino T. **The intrastitial blood supply of the lateral geniculate body.** *Arch Ophthalmol* 1965;74:815–21

Pierre R. Lefèbvre
Monique Cordonnier
Danielle Balériaux
Brussels, Belgium

Endovascular Carotid Stenting in Patients Scheduled for Cardiac Surgery: If Yes, Which First?

While the debate about the effectiveness of staged or combined surgery for carotid and cardiac disease requiring cardiac surgery with extracorporeal circulation continues, there is another issue to consider: can carotid stenting replace carotid endarterectomy in patients scheduled for cardiac surgery? In the past, despite an extensive literature on the subject, there has been a failure to identify the correct management of carotid and coronary or cardiac valve disease. Some authors have suggested that stroke at coronary surgery is due to multiple risk factors, one of which is high-grade carotid stenosis, though embolism rather than flow limitation could be the primary mechanism.¹ No significant difference in the overall stroke and mortality risk between the various strategies was found, but subgroup analysis suggested that, when carefully selected, patients with less severe cardiac disease do better when surgery is staged, whereas patients with more severe cardiac disease should be treated with combined surgery.² The increased popularity of carotid artery stenting (CAS) with its the excellent results, especially in high-risk patients, raises the question about the effectiveness of CAS in reducing the stroke risk in patients scheduled for cardiac surgery.

Recently some authors have proposed CAS before cardiac surgery, especially in asymptomatic patients.³ Unfortunately, this strategy involves the problem of antiplatelet drug therapy that increases the risk of bleeding after cardiac surgery.⁴ In my experience, an answer to this problem is an approach to carotid and cardiac disease on the basis of neurologic symptoms and severity of the cardiac disease (Table). Although this strategy has not yet proved to be the most effective in managing combined carotid and cardiac disease, we have not observed any increase in bleeding and have noted a slight decrease in minor and major strokes after surgery in a small preliminary series of patients.

References

1. Das SK, Brow TD, Pepper J. **Continuing controversy in the management of concomitant coronary and carotid disease: an overview.** *Int J Cardiol* 2000;74: 47–65

2. Naylor AR, Cuffe RL, Rothwell PM, et al. **A systematic review of outcomes following staged and synchronous carotid endarterectomy and coronary artery bypass.** *Eur J Vasc Endovasc Surg* 2003;25:380–89
3. Kihara S, Shimakura T, Tanaka SA, et al. **Staged coronary artery bypass grafting after percutaneous angioplasty for intracranial vascular stenosis.** *J Thorac Cardiovasc Surg* 2001;122:608–10
4. Englberger L, Faeh B, Berdat PA, et al. **Impact of clopidogrel in coronary artery bypass grafting.** *Eur J Cardiothorac Surg* 2004;26:96–101

Gianluca Rigatelli
EndoCardioVascular Therapy Research
Legnago, Verona, Italy

Reply:

There are few subjects as singularly controversial as the treatment of carotid atherosclerotic stenosis. Conversely, treatment of coronary artery stenosis has an established history, though recent data indicate that this therapy is more useful for prevention of angina than of sudden cardiac death. Carotid artery stenosis associated with coronary atherosclerotic disease is increasing in frequency with the aging of the general population, and clinicians are faced with how best to manage this coexistent problem. Carotid stenting offers a therapeutic option for just such patients: those with associated carotid and coronary atherosclerosis. Despite a large volume of data present in the literature, specific treatment indications relating to surgical and/or endovascular options for both, or either, remain unclear and/or controversial.

In Canada, a recent countrywide evaluation found that 0.51% of CABG procedures were combined with carotid endarterectomy (CEA). The adjusted stroke and death rate was 2.67-fold greater in the combined CEA-CABG group compared to CABG alone,¹ a rate that would seem difficult to justify. There is no doubt that treatment of symptomatic carotid stenosis is necessary and is, moreover, required very soon after the signal event.^{2,3} Treatment by any method for asymptomatic carotid stenosis is only statistically beneficial in the long term (ie, several years).⁴ Treatment of coronary artery stenosis by bypass grafting is rarely “event” dependent; rather, it is “severity” dependent. Currently, with the lack of definitive benefit for treatment of asymptomatic carotid stenosis by means of carotid artery stenting (CAS), early indication from CREST that CAS is harmful for patients >80 years of age, and proof that CEA for asymptomatic carotid stenosis is not beneficial for anyone >75 years of age,⁵ recommending CAS for asymptomatic patients prior to CABG with the indication being “pre-CABG” would be questionable. It would seem most appropriate to treat the symptomatic territory first (coronary or carotid) and reserve “combined” procedures for patients with critical stenosis associated with symptoms in both territories. Further study is required before definitive therapeutic recommendations should be made for the clinical situation of concurrent carotid and coronary atherosclerotic stenosis.

John J. Connors, III
Miami Cardiac and Vascular Institute
Baptist Hospital of Miami
Miami, Fla

Treatment of carotid and cardiac disease in the author proposal

Symptomatic Patients		Asymptomatic Patients	
Urgent Cardiac Surgery	Elective Cardiac Surgery	Urgent Cardiac Surgery	Elective Cardiac Surgery
CAS before CS	CAS Before CS	CS before CAS	CAS before CS
Aspirin 100 mg/day	Aspirin 100 mg/day		Aspirin 100 mg/day
LMW-H 100 IU/kg/12 hours	Clopidogrel 75 mg/day		Clopidogrel 75 mg/day

Note:—Symptomatic and asymptomatic refer to carotid artery disease. CAS indicates carotid artery stenting; CS, cardiac surgery; LMW-H, low-molecular-weight heparin.

References

1. Hill MD, Shrive FM, Kennedy J, et al. **Simultaneous carotid endarterectomy and coronary artery bypass surgery in Canada.** *Neurology* 2005;64:1435–37
2. Rothwell PM, Warlow CP. **Timing of TIAs preceding stroke: time window for prevention is very short.** *Neurology* 2005;64:817–20
3. Rothwell PM, Eliasziw M, Gutnikov SA, et al. **Sex difference in the effect of time from symptoms to surgery on benefit from carotid endarterectomy for transient ischemic attack and nondisabling stroke.** *Stroke* 2004;35:2855–61
4. Rothwell PM, Goldstein LB. **Carotid endarterectomy for asymptomatic carotid stenosis: asymptomatic carotid surgery trial.** *Stroke* 2004;35:2425–27
5. MRC Asymptomatic Carotid Surgery Trial (ACST) Collaborative Group. **Prevention of disabling and fatal strokes by successful carotid endarterectomy in patients without recent neurological symptoms: randomised controlled trial.** *Lancet* 2004;363:1491–502