



Providing Choice & Value

Generic CT and MRI Contrast Agents



**FRESENIUS
KABI**

CONTACT REP

AJNR

**Neuroimaging Clinics of North America:
Genetics and Neuroimaging. Vol. 14, no. 2,
February 2004**

AJNR Am J Neuroradiol 2005, 26 (4) 983-984
<http://www.ajnr.org/content/26/4/983>

This information is current as
of July 12, 2025.

Neuroimaging Clinics of North America: Genetics and Neuroimaging. Vol. 14, no. 2, February 2004
Tina Young Poussaint, guest editor. Philadelphia: Elsevier Saunders; 2004. 208 pages.

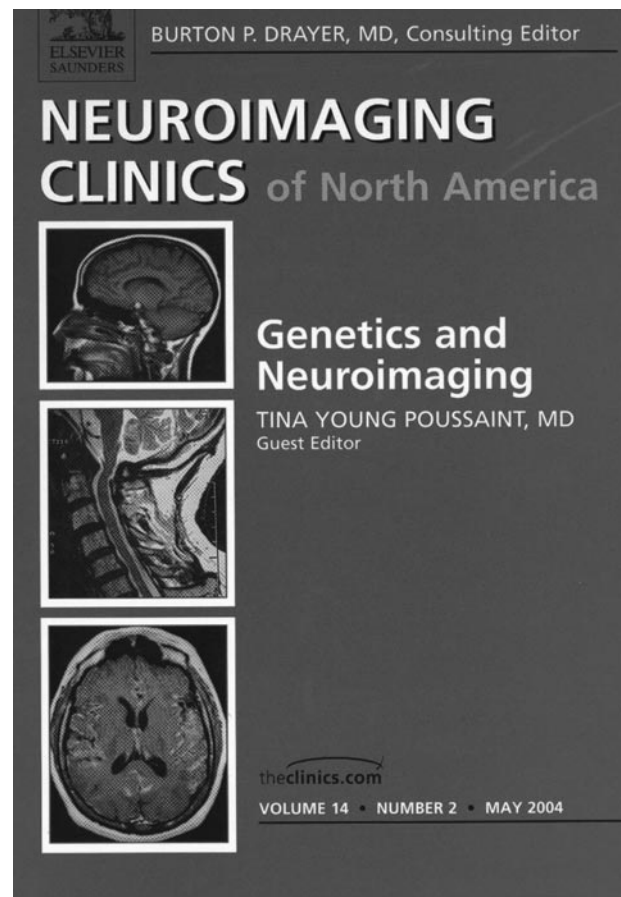
This issue of *Neuroimaging Clinics of North America* is prefaced as focusing on “the role of neuroimaging in a select number of diseases in which genetics plays a key role.” For the most part, this is successfully accomplished, although several chapters place a strong emphasis on disorders and conditions that are not genetic, including acquired insults. The goal of each individual issue should be taken in the greater context of the goal of the *Neuroimaging Clinics of North America* to provide “articles reviewing the state of the art in patient care.”

The first four chapters are dedicated to the phakomatoses, a heterogeneous group of inherited neurologic disorders. The first is a comprehensive overview of the genetics and clinical manifestations of the most common phakomatoses, followed by well-written chapters dedicated to their neuroimaging features. The format results in some inevitable repetition, but this is generally kept to a minimum.

Chapter 4—the rare phakomatoses—provides an overview of disorders so uncommon as to be encountered infrequently, even in a busy academic practice. This thorough review contains numerous clinical images. Although costly, color reproduction would have greatly enhanced lesion conspicuity and the value of these figures. Because these are rare conditions, the somewhat dated radiologic images should be forgiven. More difficult to overlook, however, are the excessive number of references (328) contributing to making this chapter the longest, albeit the least relevant, to the practicing radiologist.

Chapters 5 and 6 focus on cortical development, with complementary discussions of the clinical, genetic, and imaging features. The latter is preceded by a helpful review of imaging techniques for those less familiar. These are among the strongest chapters in the text, nicely reviewing each of the major disorders and the classification into which they fall, including malformations secondary to abnormal proliferation or apoptosis, abnormal neuronal migration, and abnormal late migration and organization. The figures appear somewhat older, and additional arrows would help the inexperienced reader with the more subtle findings. Along these lines, advanced imaging techniques, including diffusion tensor imaging, would make this a much more cutting-edge discussion.

Several chapters on fetal imaging follow, which are the least “on theme.” Certainly many genetic conditions can be diagnosed prenatally; however, the authors’ emphasis is more on *all* prenatally detectable conditions, including intracranial ischemia, hemorrhage, and neck masses. Allowing for this thematic tangent, the fetal imaging chapters are generally well written. It should also be noted that all of the authors of the fetal imaging chapters are from the same in-



stitution. Because many institutions have different approaches to integrated fetal imaging and care, a broader perspective might also have strengthened this section.

The chapter titled “Sonography of the Fetal CNS” provides a brief overview of current techniques, complete with sonographic images, from a normal fetus demonstrating the appropriate technique, views to be obtained, and structures to be assessed. A review of pulse-wave and color Doppler sonography with clinical indications is helpful for those who are not familiar with these techniques. Numerous figures with generally well-depicted conditions compose the bulk of the chapter. The text is limited to technical descriptions and comparison of sonography and fetal MR imaging. The authors appear to have a bias toward sonography, with a long list of anomalies for which they believe sonography superiorly depicts the CNS. These beliefs are not universally held.

The chapter on fetal head and neck MR imaging makes the best attempt to correlate the imaging with genetics. It begins with interesting and thorough discussions of the cleft lip/palate and facial clefts, their

imaging features, and genetic implications. Along with other facial anomalies and syndromes that include facial dysmorphism, ocular and orbital anomalies and craniosynostosis syndromes are nicely covered. Overall, the fetal MR images are high quality and well annotated. Head and neck masses (including vascular lesions) are also included, although many have less of a well-recognized genetic association.

Although the final fetal imaging chapter focuses on MR imaging of the fetal CNS, the imaging is much less pleasing than in the previous chapters, and little attention is paid to those disorders in which genetics plays a key role. Imaging of vascular, ischemic, hemorrhagic, and inflammatory processes are reviewed, including a color Doppler image of a vein of Galen malformation that was lacking from the sonography chapter. A brief discussion of metabolic disorders presents no imaging, and the reference to which the reader is directed for an example of *in utero* MR spectroscopy is, in fact, from a postnatal scan.

A much more comprehensive review of the neuroimaging approach to inborn errors of metabolism is provided by the penultimate chapter. High-quality imaging is complemented by the detailed text, which contains a good balance of emphasis on the clinical and the imaging. The inclusion of more MR spectroscopy (shown only in the setting of Canavan disease)

and more-advanced imaging techniques would have made this a truly spectacular chapter.

Finally, the monographic concludes with an all-too-short chapter on the molecular imaging of cell-based therapies. An introduction to the technique precedes a complex discussion of current *in vivo* laboratory experiments with an emphasis on genetically modified cells for the purposes of cell tracking. The images are exquisite. Many of these techniques utilize nuclear or optical imaging, fields with which most practicing neuroradiologists are not intimately familiar. MR imaging is a less well-developed technique currently, and learning about these alternative modalities is valuable for all with an interest in this field. The potential of these techniques to impact on genetic and acquired conditions (such as their exciting new work on stem-cell therapy for intracranial ischemia) is high and the future of molecular imaging holds great possibilities.

The stronger sections of this monograph can serve as an excellent review for a practicing neuroradiologist or as an in-depth introduction to pediatric neuroimaging for a trainee. Only a few chapters achieved the basic goal of the Neuroimaging Clinics of North America, but overall the material is instructive and helpful to the practicing neuroradiologist.