

Generic Contrast Agents

Our portfolio is growing to serve you better. Now you have a *choice*.



[VIEW CATALOG](#)

AJNR

This information is current as of May 31, 2025.

***De Novo* Basilar Top Aneurysm in an Elderly Patient Treated with Guglielmi Detachable Coils**

Kenta Fujimoto, Ryota Kimura, Jun-ichi Iida, Shoichiro Kawaguchi, Toshisuke Sakaki, Hiroyuki Nakagawa, Kimihiko Kichikawa and Toyohisa Fujita

AJNR Am J Neuroradiol 2005, 26 (4) 915-916
<http://www.ajnr.org/content/26/4/915>

De Novo Basilar Top Aneurysm in an Elderly Patient Treated with Guglielmi Detachable Coils

Kenta Fujimoto, Ryota Kimura, Jun-ichi Iida, Shoichiro Kawaguchi, Toshisuke Sakaki, Hiroyuki Nakagawa, Kimihiko Kichikawa, and Toyohisa Fujita

Summary: Ruptured *de novo* aneurysms, compared with the usual subarachnoid hemorrhage, commonly occur in younger patients and are extremely rare in elderly patients. We discuss their etiology and report the case of a ruptured *de novo* aneurysm in a 77-year-old woman.

The *de novo* formation of an aneurysm is the occurrence of new aneurysms in a location previously observed to be normal by an angiography or direct surgical exploration. Although the etiology of *de novo* aneurysms is unclear, carotid ligation, female sex, a history of subarachnoid hemorrhage, smoking, hypertension, and youth are considered to be risk factors, and cases in elderly patients are extremely rare (1–4). In this report, we describe a case of a ruptured *de novo* basilar top aneurysm in an elderly patient and discuss their etiology.

Case Report

A 77-year-old woman presented with an acute headache followed by nausea and vomiting. At the age of 72, she underwent clipping of the incidental right middle cerebral artery aneurysm, left internal carotid-posterior communicating artery aneurysm and left carotid cave aneurysm (Fig 1A, B). She was nonsmoker, and hypertension was controlled with a calcium antagonist. Neurologic examination yielded normal findings. CT imaging showed an intraventricular hemorrhage (Fig 2), and cerebral angiography revealed a basilar top aneurysm (Fig 3C) that had not been observed in a previous angiography (Fig 1C). No regrowth of the previously treated aneurysms was observed (Fig 3A, B). She underwent successful embolization of the new aneurysm with Guglielmi detachable coils (Fig 3D). Her postoperative course was uneventful, and she was discharged 3 weeks after treatment.

Received May 25, 2004; accepted after revision July 11.

From the Departments of Neurosurgery (K.F., R.K., J.-i.I., S.K., T.S.) and Radiology (H.N., K.K.), Nara Medical University, Kashihara; and the Department of Neurosurgery (T.F.), Saiseikai Chuwa Hospital, Sakurai, Nara, Japan.

Address correspondence to Kenta Fujimoto, MD, Department of Neurosurgery, Nara Medical University, Shijo-cho 840 Kashihara, Nara 634-8522 Japan. E-mail: kentaf@naramed-u.ac.jp

© American Society of Neuroradiology

Discussion

De novo formation of aneurysms is the result of the interplay between hemodynamic factors and structural weakness. Several authors have described the clinical characteristics of *de novo* aneurysms (1–4). The risk factors are considered to be carotid ligation, youth, female sex, a history of subarachnoid hemorrhage, smoking, and hypertension (3, 4). Tonn et al (4) reviewed 50 published cases and reported that the mean age of susceptibility to *de novo* aneurysms was 43.3 (range, 17–69 years). Patients in whom *de novo* aneurysms occur are commonly younger than those with the usual subarachnoid hemorrhage (1–4). The occurrence of *de novo* aneurysms in an elderly patient is extremely rare, and to the best of our knowledge, our patient is the oldest of all reported cases.

In addition, another unusual characteristic of our case lies in the multiplicity of the aneurysms. David et al (5) reported that five of their series of six *de novo* aneurysms had a history of multiple aneurysms. From reviews of the other previous reports, however, we were unable to uncover a relationship between the multiplicity of aneurysms at the time of the initial episode and formation of the *de novo* aneurysms. The etiology itself is obscure, but we speculate the possibility that multiple parts of the arterial wall may be “pathologic” in patients with multiple intracranial aneurysms. We maintain that strict follow-up is necessary for patients with known risk factors or multisegmental aneurysms, even if the patient is old, because *de novo* aneurysms may arise at any time, place, and age.

References

1. Briganti F, Cirillo S, Caranci F, et al. Development of “*de novo*” aneurysms following endovascular procedures. *Neuroradiology* 2002;44:604–609
2. Rinne JK, Hernesniemi JA. *De novo* aneurysms: special multiple intracranial aneurysms. *Neurosurgery* 1993;33:981–985
3. Sakaki T, Tominaga M, Miyamoto K, et al. Clinical studies of *de novo* aneurysms. *Neurosurgery* 1993;32:512–517
4. Tonn JC, Hoffmann O, Hoffmann E, et al. “*De novo*” formation of intracranial aneurysms: who is at risk? *Neuroradiology* 1999;41: 674–679
5. David CA, Vishteh AG, Spetzler RF, et al. Late angiographic follow-up review of surgically treated aneurysms. *J Neurosurg* 1999;91:396–401

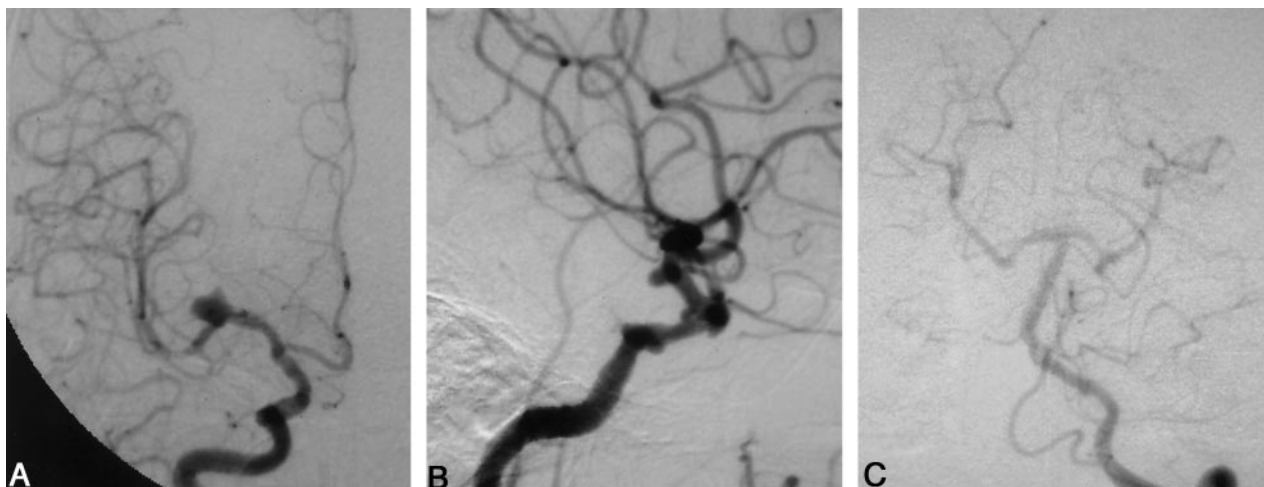


FIG 1. Initial cerebral angiograms. Anteroposterior (AP) view of the right carotid angiogram displayed a middle cerebral artery aneurysm (A). The lateral view of the left carotid angiogram displayed an internal carotid-posterior communicating artery aneurysm and a carotid cave aneurysm (B). The vertebral angiogram showed no abnormal findings. (C)

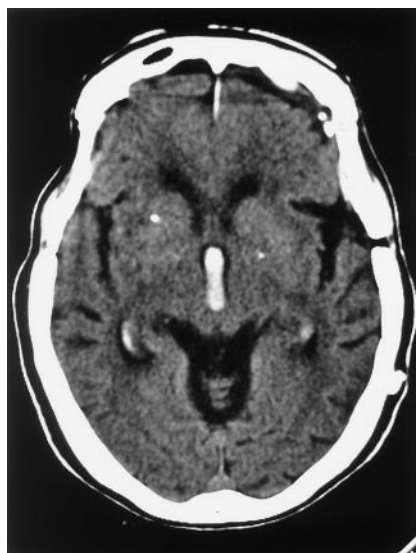

FIG 2. CT scan showing an intraventricular hemorrhage.

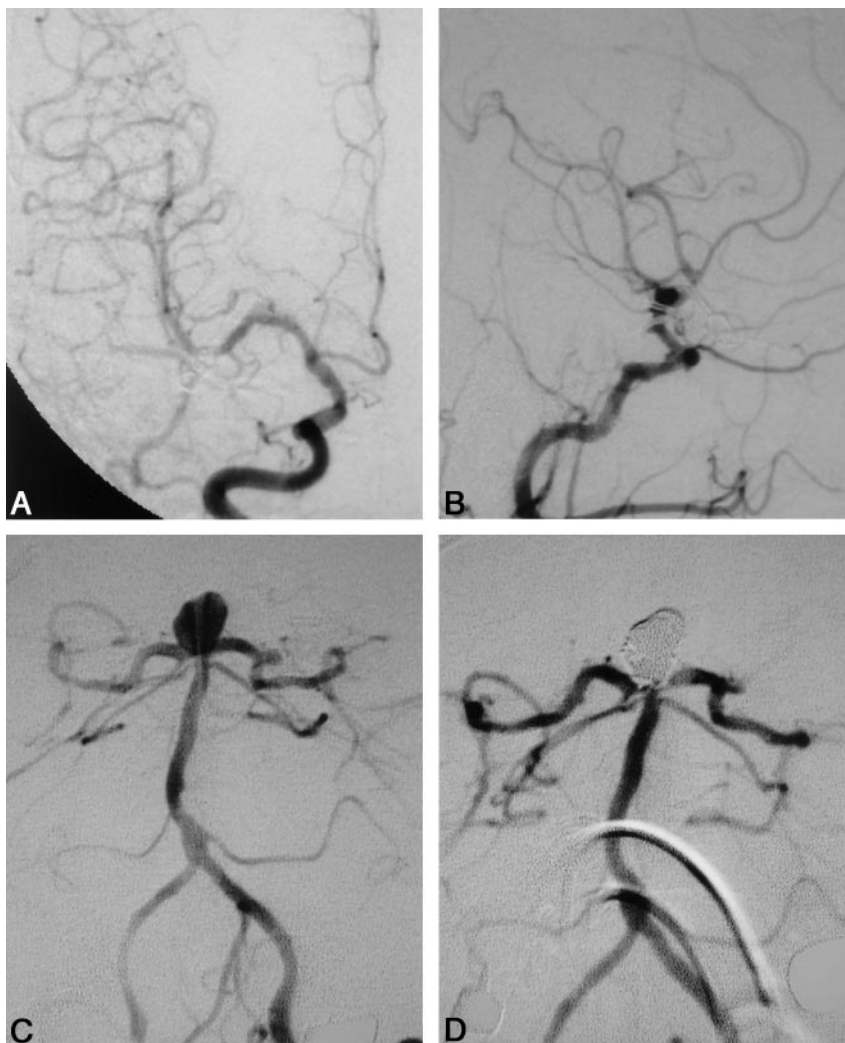


FIG 3. Cerebral angiograms on admission. No regrowth of previously clipped aneurysms was observed. A, AP view of the right carotid angiogram. B, Lateral view of the left carotid angiogram. Vertebral angiography demonstrated a *de novo* aneurysm at the top of the basilar artery. C, Straight AP view of left vertebral angiogram. D, Successful coil embolization of the aneurysm.