



Discover Generics

Cost-Effective CT & MRI Contrast Agents



WATCH VIDEO

AJNR

Neuroimaging Clinics of North America: Imaging of the Mandible, Maxilla, and Pharynx. Vol. 13, no. 3, August 2003

AJNR Am J Neuroradiol 2005, 26 (3) 683
<http://www.ajnr.org/content/26/3/683>

This information is current as
of June 9, 2025.

Neuroimaging Clinics of North America: Imaging of the Mandible, Maxilla, and Pharynx. Vol. 13, no. 3, August 2003

Alfred L. Weber, gen. ed. W.B. Saunders Company; 2003. 651 pages, 520 illustrations. \$84.

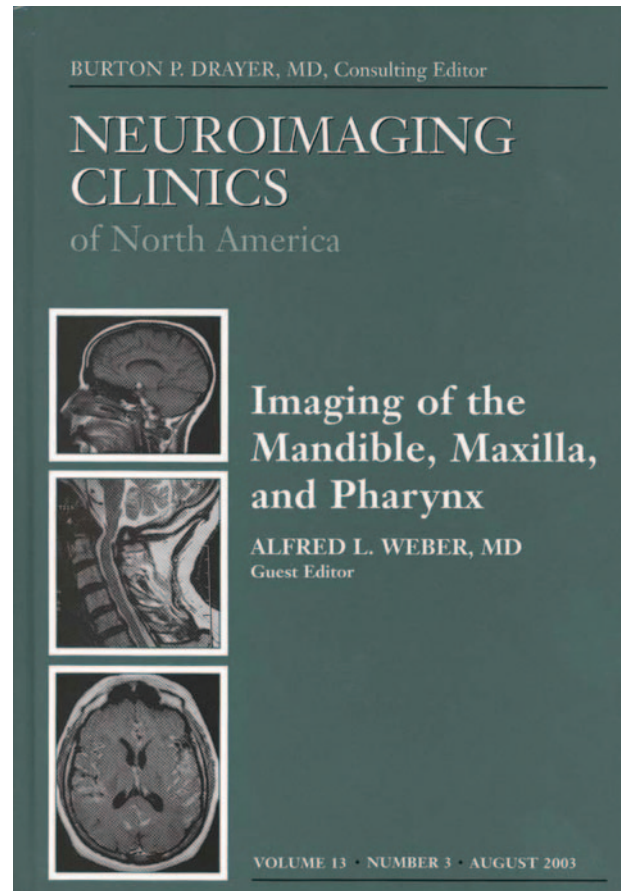
This book is a useful text that offers a clinicopathologic and radiologic review of various commonly encountered maxillofacial and pharyngeal disease processes. The intended audience includes not only the radiologists and neuroradiologists, but also otolaryngologists, head and neck and oromaxillofacial surgeons, and other physicians who may encounter these clinical conditions on a daily practice. The multiauthored volume was edited by Dr. Weber, who also contributed many of the chapters. The notable authors have provided excellent material.

Because of its overall organization, this work is very readable. Individual chapters are not only comprehensive, but are also well referenced for further reading.

The book begins with a chapter on lymphoma. It includes a detailed discussion of the staging, pathology, clinical presentation, disease spectrum, and radiologic patterns of lymphoma with excellent case illustrations and high-quality images. The rest of the chapters cover inflammatory, neoplastic, and congenital lesions of the oral cavity, oropharynx, nasopharynx, maxilla, and mandible. Complementing these chapters are sections on temporomandibular imaging and a final chapter that provides an update on interventional procedures in the head and neck.

The chapter on infections of the oral cavity and oropharynx is concise and offers practical information of particular importance for the clinician. It provides excellent descriptions of the routes of potential spread and addresses issues that may have very important implications both for diagnosis and surgical planning. Tumors of the oropharynx and nasopharynx are extensively covered. The chapters are a combination of an overview of pathology, clinical presentation, radiologic techniques, and imaging findings that play an important role in surgical management and treatment planning. Illustrations are ample and generally of high quality. Both chapters are extremely well researched. The chapter on lesions of the oral cavity and pharynx in children is well written, organized and combines a detailed discussion of abnormalities from a clinical, imaging, and treatment standpoint. Most of the illustrations—primarily MR images—are adequate, although one notable drawback is the lack of corresponding CT images.

Sections dealing with maxillofacial cysts and benign tumors are thorough and provide detailed radiologic-pathologic correlation. Basic radiographic techniques used for imaging are discussed at length. Of great value are the excellent quality images of plain film correlation with CT and MR of the cysts and odontogenic tumors. The chapters on fibroosseous lesions and malignancies are informative, but the overall quality of some CT images in particular is disappointing. Incorporation of a few more MR images, especially of the malignant lesions, would have been preferable. The chapter on imaging of craniofacial malformations is well researched and provides a good overview of the topic. It focuses on technical considerations, in addition to embryology, genetics, clinical, and imaging features of various craniofacial malformations. Particularly useful are the superb illustrative examples and reformatted CT images. Chapters related to the temporomandibular joint are valuable in helping the reader understand the potential usefulness of CT



and state-of-the-art MR over previous conventional imaging modalities in the diagnosis of and treatment of temporomandibular joint disorders.

Finally, the last chapter includes the various interventional procedures used for treatment of various pathologies of the head and neck. Indications and techniques of image-guided biopsies, endovascular interventional procedures such as vessel occlusion and embolization, and pharmacotherapy are described in detail. Common vascular disorders and their treatment are well discussed and relevant for this comprehensive issue.

Overall, the authors have fulfilled the goal of this book, to provide a clinicopathologic approach to various disease processes of the maxillofacial region and pharynx. The book is a useful reference that focuses on basic sciences, clinical information, diagnostic evaluation, and treatment modalities for residents, practicing radiologists, and clinicians. It gives a comprehensive review of the various pathologic states involving the head and neck and provides more pertinent information than many textbooks on this subject.