



Providing Choice & Value

Generic CT and MRI Contrast Agents



**FRESENIUS
KABI**

CONTACT REP

AJNR

**Cranial Neuroimaging and Clinical
Neuroanatomy: Atlas of MR Imaging and
Computed Tomography**

AJNR Am J Neuroradiol 2005, 26 (1) 190
<http://www.ajnr.org/content/26/1/190>

This information is current as
of July 21, 2025.

Cranial Neuroimaging and Clinical Neuroanatomy: Atlas of MR Imaging and Computed Tomography.

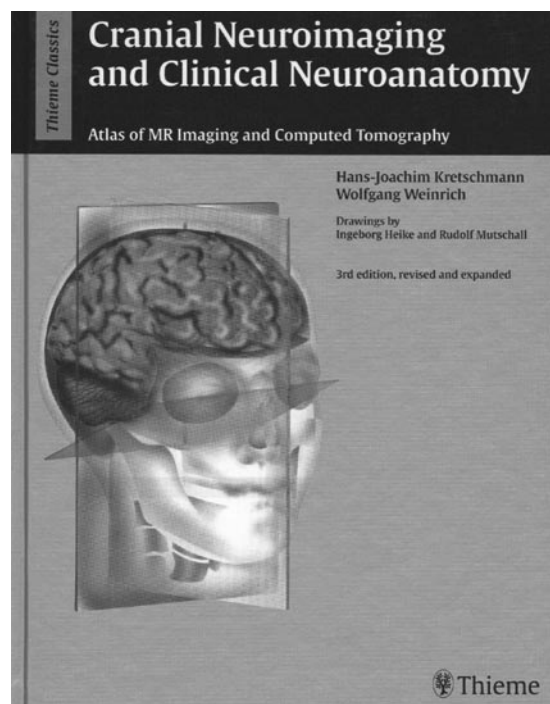
Hans-Joachim Kretschmann, Wolfgang Weinrich. Drawings by Igeborg Heike and Rudolf Mutschall. 3rd ed., revised and expanded. New York: Thieme; 2003. 460 pages, 5 tables, 664 illustrations. \$199.00.

When they say this book is revised and expanded, they aren't kidding. This book is *really* expanded and *really* revised for the new millennium, taking advantage of updated MR images and incorporating newer sections that address functional MR imaging. It is an extremely helpful and user-friendly format. Too many superlatives for you? Here are some more: this first-rate, handsomely printed, textbook features 664 phenomenal illustrations that demonstrate every point completely and clearly; it must have taken many years to complete. There are 451 pages in this edition; the previous edition contained only 373.

Dr. Kretschmann is the neuroanatomist, and Dr. Weinrich is both a practicing neurologist and a card-carrying neuroradiologist; between the two of them they have pulled together the information needed to make the correct neurodiagnosis for any conceivable condition. A preface written by Ruth Ramsey, who herself is the author of a helpful neuroradiology book, heaps deserved praise upon this fine atlas. An expanded introduction has an extensive discussion of the neuroimaging techniques currently available, including MR imaging, CT, and positron-emission tomography, with recommendations on where and when to make the best use of them. This section in particular should be useful for all residents-in-training in all of the clinical neuroscience subspecialties.

This edition includes new and well-illustrated sections on vascular anatomy and functional neuroanatomy of the brain. The latter are particularly useful because they detail currently available paradigms and techniques for their usage during echo-planar acquisitions in functional MR imaging sequences. By using these examples, neuroradiologists can plan imaging strategies to make the most out of functional MR imaging, whether it is to be used for localization of the motor strip and dominant speech areas before surgery, or whether it will be used for psychologic evaluations in research projects. There is a good discussion of association areas of the brain that are activated along with primary sites of activity, including examples and discussion of phenomena such as the contralateral crossed cerebellar diaschisis, which occurs with unilateral primary motor strip activation during motor paradigms.

Color-coded diagrams of vascular territories above and below the tentorium overlaid upon sequential axial, coronal, and sagittal brain sections help make diagnosis of arterial and venous vascular infarcts more precise. Different specific vessel territories are



color-coded, so these regions can be followed and identified over the course of well-illustrated sequential multiplanar image sections.

As for the “meat-and-potatoes” multisectonal neuroanatomy sections and diagrams, it should be noted that it has the best-quality drawings that this reviewer has ever seen. Many are in color and there are large-format images corresponding exactly to the multiplanar anatomic specimens. The pictures correspond to an additional parallel set of matched line drawings. The illustrations throughout all sections of the book are numerous, clear, professionally produced and reproduced, and are exhaustively (and correctly) labeled. One picture in these pages may well be worth more than the usual “thousand words.”

Although the book is expensive, there is no question that it is worth it. There probably won't be a need to buy another one for at least another decade, pending major invention of another imaging technique (Heaven forbid!) in that time frame. A CD-ROM would be a nice adjunctive publication that the publishers might consider, but for neuroradiologists who still favor the hard copy book format for learning and reference, this volume is highly recommended.