



Providing Choice & Value
Generic CT and MRI Contrast Agents



CONTACT REP

AJNR

MR Imaging of the Spine and Spinal Cord

AJNR Am J Neuroradiol 2004, 25 (8) 1452
<http://www.ajnr.org/content/25/8/1452>

This information is current as
of July 19, 2025.

MR Imaging of the Spine and Spinal Cord

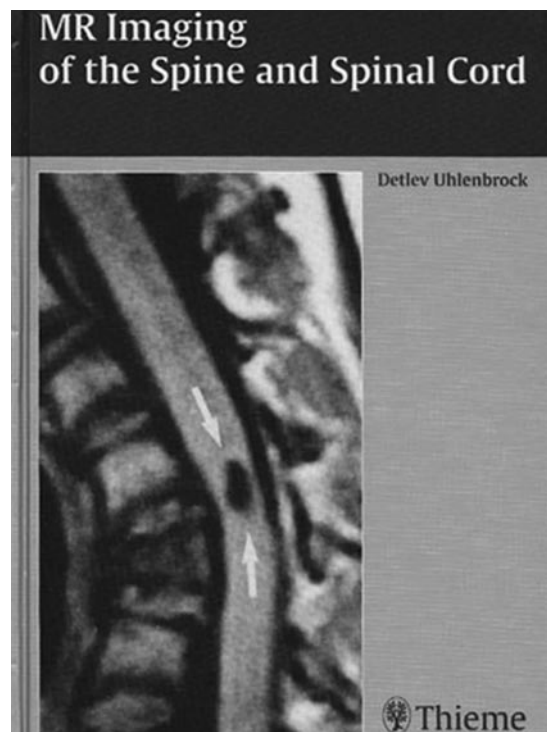
Detlev Uhlenbrock, ed. Grahame Larkin, trans. Thieme: Stuttgart, NY; 2004. 518 pages, 1305 illustrations. \$149.

MR Imaging of the Spine and Spinal Cord is a translation of the German edition, published in 2001, edited by Detlev Uhlenbrock. Grahame Larkin has admirably translated this book, and only a few sentences are somewhat awkward. Measuring 7×9.5 inches, this 518-page work is concise and portable. The book is divided into nine chapters, with each containing helpful charts and tables, as well as a useful one-to-two page bulleted summary at the end. Within each chapter, each major diagnostic entity is presented similarly, with pathogenesis, epidemiological and clinical data presented first, followed by the diagnostic imaging findings. This form of presentation is logical and places the role of imaging in context, thus making it easier for the radiologist to understand what information the clinician requires.

The first chapter is titled "Physics and its Applications." The difficulty of summarizing MR physics in 27 pages is evident, although some practical information concerning useful pulse sequences in the spine, as well as artifacts, is provided. The second chapter, "MR Imaging and Spinal Surgery: Indications Based on the Spectrum of Surgical Therapeutic Options," discusses the neurosurgical approaches used for different disease entities. Many of the images in this chapter are conventional radiographs, as well as very nice anatomical models, because of artifacts that the surgical hardware creates on MR images. This chapter appears somewhat out of place, and dispersing the surgical information into later chapters may have been a more effective approach.

One problematic issue that becomes apparent in the following chapters is that the original book was from 2001 and is therefore not completely current, with only a few references after 2000. The next chapter, "Malformations," does an excellent job of discussing the pathogenesis of spinal malformations, with good drawings to illustrate the different diseases. The authors also include many postoperative images. One timely topic that is not included, however, is fetal MR imaging and its role in preoperative planning. The next chapter, "Degenerative Disorders of the Spine," also suffers from a lack of a review of current literature. For example, there is no mention of the Nomenclature and Classification of Lumbar Disk Pathology assembled jointly by the North American Spine Society, the American Society of Neuroradiology, and the American Society of Spine Radiology. In fact, the nomenclature presented for disk disease is somewhat confusing (ie, protrusion presented as the equivalent of disk bulge). A highlight of this chapter, however, is its presentation of postoperative findings, especially following disk surgery, which appears more extensive than other references.

The next four chapters are "Tumors of the Spine and Spinal Canal," "Inflammatory Disorders of the



Spine and Spinal Canal," "Use of MR Imaging in Acute Spinal Trauma," and "Vascular Disorders of Spinal Canal." The coverage of all entities is generally complete, and as with previous chapters, there is extensive review of pathogenesis and associated clinical issues. Occasionally, a disease is not where it may be expected. For example, hemangioblastomas are covered in the chapter, "Vascular Disorders," instead of in the chapter, "Tumors."

The final chapter is titled "Functional Analysis and Surgery of the Spine in an Open MR System." Topics include upright imaging, MR-guided biopsy, and minimally invasive surgery, such as percutaneous laser discectomy.

In general, the number of figures and examples are appropriate, although many of the figures are somewhat grainy. In addition, it would have been helpful if more were labeled with arrows, because some of the findings described in the figure legends were difficult to locate.

The intended audience is primarily radiologists; however, neurosurgeons and neurologists would also likely benefit from this book, which often discusses the advantages, as well as limitations, that MR imaging offers. Although this book does not provide a summary of cutting-edge research, it does an excellent job summarizing the pathogenesis and clinical role of MR imaging in most spinal disorders and provides ample illustrative images.

© American Society of Neuroradiology