



Providing Choice & Value

Generic CT and MRI Contrast Agents



**FRESENIUS
KABI**

CONTACT REP

AJNR

**Thrombosis of the Internal Cerebral Vein
Associated with Transient Unilateral
Thalamic Edema: A Case Report and Review
of the Literature**

Karin A. Herrmann, Bernd Sporer and Tarek A. Yousry

This information is current as
of July 8, 2025.

AJNR Am J Neuroradiol 2004, 25 (8) 1351-1355

<http://www.ajnr.org/content/25/8/1351>

Thrombosis of the Internal Cerebral Vein Associated with Transient Unilateral Thalamic Edema: A Case Report and Review of the Literature

Karin A. Herrmann, Bernd Sporer, and Tarek A. Yousry

Summary: Thrombosis of the deep venous system presenting with bilateral thalamic infarction or edema is a common finding, but unilateral venous thrombosis presenting with unilateral thalamic edema is extremely rare. We report a case of a patient with this unusual condition presenting with nonspecific clinical signs and symptoms. CT and MR imaging revealed a unilateral thalamostriate lesion. The imaging sign that was most helpful in establishing the diagnosis, however, was the MR finding of a thrombus in a single internal cerebral vein.

Deep venous infarction is a well-recognized entity that has been well described in the literature. Deep venous infarction is usually symmetrical, affecting the thalamus bilaterally, and possibly extending into the basal ganglia and the adjacent white matter bilaterally (1–4). By contrast, to the best of our knowledge, deep venous thrombosis that affects only a single thalamus is a rare entity that has been described only twice before in the literature (5, 6).

We report the clinical and imaging findings of a patient with unilateral deep internal cerebral vein thrombosis (DICVT) leading to a completely reversible unilateral thalamic edema and review the literature on this rare entity.

Case Report

Two weeks before admission, an otherwise healthy 47-year-old woman developed an acute headache, hemihypesthesia and hemiparesis of the right arm, and an episode of retrograde amnesia for this event and the 24 hours preceding it. Over several days the headache resolved, right-arm symptoms regressed but did not resolve, and the patient was admitted to our hospital.

On admission, the only focal neurologic or neuropsychological sign was slight reduction in right arm strength. Initial CT showed a circumscribed hypoattenuated area in the left thalamus (Fig 1A). MR imaging (axial and coronal T2-weighted spin-echo sequences and T1-weighted spin-echo sequences be-

fore and after administration of gadopentetate dimeglumine [Gd-DTPA]) and 2D time-of-flight MR angiography revealed a circumscribed hyperintense lesion (T2-weighted image; Fig 1B) in the mediodorsal portion of the left thalamus. A lack of flow void within the left internal cerebral vein (ICV) was observed (MR angiography), and the left ICV was slightly hyperintense on the T1-weighted image (Fig 1C). After administration of Gd-DTPA, the left ICV was heterogeneous as compared with the right ICV, a finding pathognomonic of the presence of a thrombus with associated edema (Fig 1E).

The results of lumbar puncture, extracranial and transcranial Doppler sonography, acoustically evoked potential monitoring, visually evoked potential monitoring, somatosensory evoked potential monitoring, electroencephalography, electrocardiography, and laboratory analyses of serum and CSF samples were all within normal ranges. Isolated ICV thrombosis was diagnosed, and the patient was treated for 2 weeks with heparin therapy to maintain the activated partial thromboplastin time between 2 and 3 times baseline (international normalized ratio).

Within 3 weeks after admission, the patient's right arm symptoms had resolved completely, and MR imaging showed marked regression of the thrombus and the edema and partial restitution of the flow void within the left ICV. The patient continued anticoagulant therapy with warfarin for 2 years. At the 2-year follow-up, the patient remained asymptomatic, and MR imaging of the left thalamus showed no substantial defects (Fig 1F and G).

Discussion

To the best of our knowledge, no one has previously reported on the CT and MR appearance of unilateral thrombosis of a single ICV leading to a reversible edema of the thalamus.

Clinical Course

In contrast to dural sinus thrombosis, DICVT more often leads to death or major long-term sequelae (2). Patients with DICVT tend to present with a short history of rapidly declining consciousness (2). The prognosis of this entity, however, is not necessarily poor (7).

Clinical manifestation of DICVT can be both complex and nonspecific. They can cover a wide range of symptoms from headache, nausea, and vomiting to focal neurologic deficits, hemiparesis, aphasia, seizures, coma, and death. Of the 24 patients reported in the literature (Table), 13 presented with mild symptoms, five with neurologic deficits or seizures, and five with decline of consciousness or coma. In one patient,

Received April 11, 2002; accepted after revision January 13, 2004.

From the Institute of Clinical Radiology (K.A.H.) and Departments of Neurology (B.S.) and Neuroradiology (T.A.Y.), Ludwig-Maximilians-University of Munich, Grosshadern, Germany.

Address correspondence to Professor T. A. Yousry, Institute of Neurology, Lysholm Department of Neuroradiology, Queen Square, London WC1N3BG United Kingdom.

© American Society of Neuroradiology

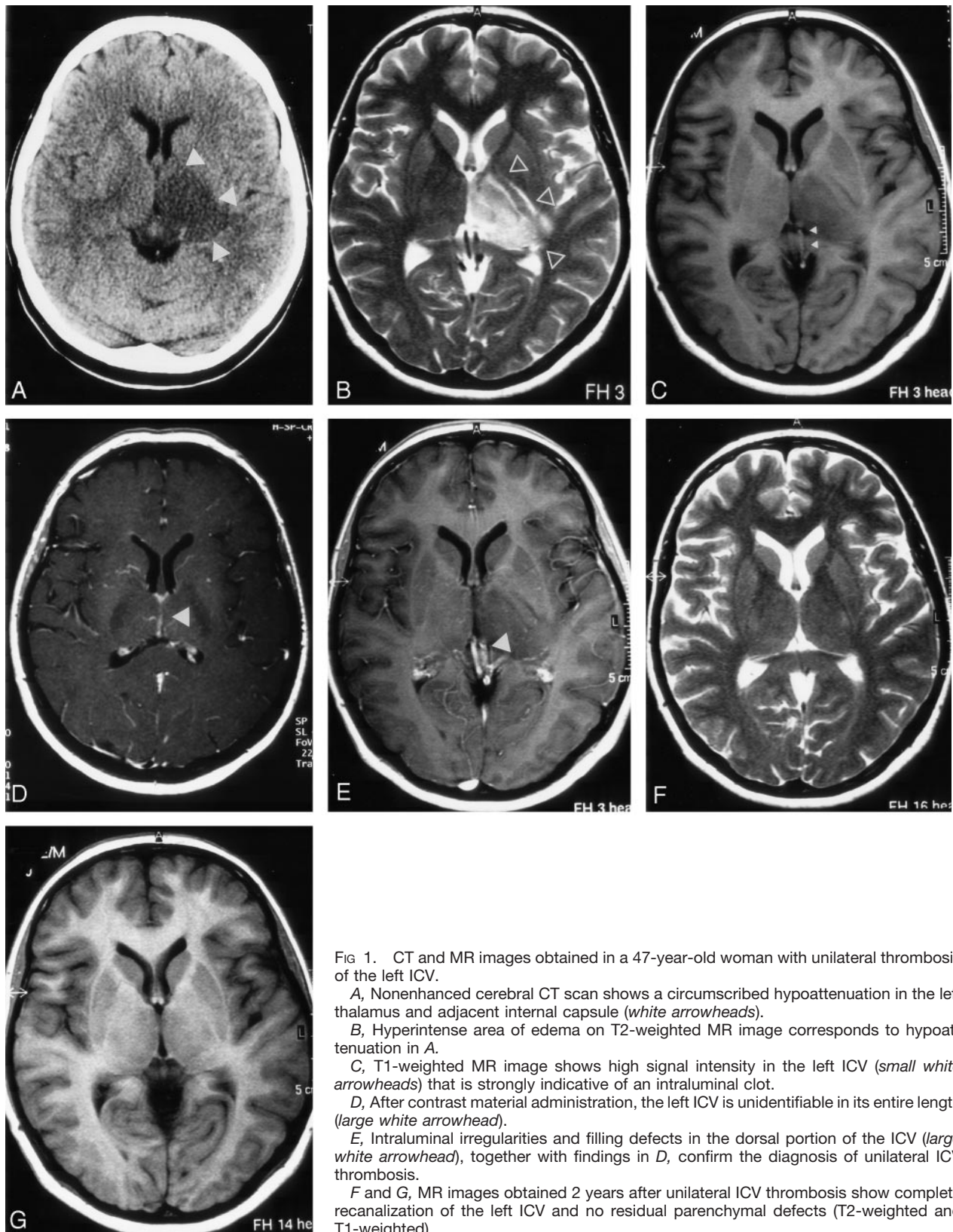


FIG 1. CT and MR images obtained in a 47-year-old woman with unilateral thrombosis of the left ICV.

A, Nonenhanced cerebral CT scan shows a circumscribed hypoattenuation in the left thalamus and adjacent internal capsule (*white arrowheads*).

B, Hyperintense area of edema on T2-weighted MR image corresponds to hypoattenuation in A.

C, T1-weighted MR image shows high signal intensity in the left ICV (*small white arrowheads*) that is strongly indicative of an intraluminal clot.

D, After contrast material administration, the left ICV is unidentifiable in its entire length (*large white arrowhead*).

E, Intraluminal irregularities and filling defects in the dorsal portion of the ICV (*large white arrowhead*), together with findings in D, confirm the diagnosis of unilateral ICV thrombosis.

F and G, MR images obtained 2 years after unilateral ICV thrombosis show complete recanalization of the left ICV and no residual parenchymal defects (T2-weighted and T1-weighted).

clinical symptoms were not communicated (8). Of the 13 patients with mild symptoms, four recovered completely, six had persistent deficits, and three died. In the five patients with focal neurologic symptoms,

three recovered almost completely, and one died. One patient was unreported (9). Finally, of the five patients with impairment of consciousness or coma, three died and one had persistent deficits. In the case

Review of the literature: presentation, diagnostic imaging, and outcome of internal cerebral venous thrombosis

Author	Patients (No.)	Signs and Symptoms	Thrombosed Veins	Diagnostic Imaging/Validation	Location of Lesions	Outcome
Johnsen et al 1973 (27)	2 infants	V, fever, diarrhea V, lethargy	ICV, SS, VG ICV, VG, SS	autopsia CA	TT, BG, HT hemorrhage -TT, hydroceph	Death Residual deficits n.a.
Yoshii et al 1978 (9)	1	-HA, fever, DC, coma	DCV, VG, SS	NECT, CA	-ventricular dilatation	Almost recovery
Forsting et al 1989 (6)	1	HA, BA, DM, HP	ICV, VG, SS, RTV	NECT, MRI	-unilateral, then TT	Mnestic deficits
Haley et al 1989 (10)	1	HA, NV, confusion DM, amnesia	ICV, VG, SS	NECT, CA	-TT	
Erbguth et al 1991 (8)	3	A, DC, HP A, DC, hemianopsia n.a.	ICV, SS ICV, VG, SS, SSS VG, SS	NECT, CA NECT, MRI	-TT, BG -TT, hemorrhage -LT hemorrhage	Residual deficit Recovery Recovery
Bell et al 1994 (1)	3	Confusion Confusion Coma, seizure	DCV, DS DCV, DS DCV	MRI, MRA MRI, MRA MRI, MRA, CA	-TT -TT, BG -TT, BG	Residual deficits Recovery Death
Crawford et al 1995 (2)	7	-HA, NV; -HA; NV, DC -HA; NV, DM -HA, fever, DM -HA, NV -Seizures -HA, NV, DM	-ICV, VG, SS -ICV, VG, SS, SSS -ICV, VG, SS, SSS -ICV, VG, SS, SSS, TS -ICV, VG, SS -ICV, VG, SS, SSS -ICV, VG, SS, SSS	NECT, MRI, CA NECT, autopsy autopsy NECT, MRI, CA MRI, MRA NECT, MRI, MRA MRI, CA	-TT, hydroceph n.a. n.a. -TT -TT, BG -TT -TT, BG, hemorrhage	Severe disability Death Death Severe disability Stable Seizures controlled Death n.a.
Wang et al 1995 (29)	1	Confusion, seizure, BA	SSS, DCV	MRI, CA	-TT	Recovery
Förderreuther et al 1997 (7)	1	Amnesia	DCV, VG, SS	NECT, MRI, CA	-TT	Discrete neurol deficit
Gerszten et al 1997 (12)	1	NV, HA, HP, BA	ICV, SS, RTS	NECT, MRI, MRA	-TT, BG, LT hemorrhage	Death
Magni et al 1998 (13)	2	HA, NV, HP HA, N, BA; DM	DCV, SS DCV, VG, SS, LS	NECT, MRI, CA NECT, MRI, MRA	-TT, BG mesencephalic -TT	Recovery Residual deficit in verbal recall
Rousseaux et al 1998 (5)	1	Amnesic syndrome, dystonia	SS, LICV	n.a.	LT, striatocapsular	

Note.—symptoms: HA, headache; N, nausea; V, vomiting; HP, hemiparesis; BA, behavioral anomalies; DM, decline in mental status; DC, decline in consciousness; A, aphasia. Veins: DCV, deep cerebral veins; ICV, internal cerebral vein; LICV, left internal cerebral vein; VG, vein of Galen; SS, straight sinus; LS, lateral sinus; (R)TS, (right) transverse sinus; SSS, superior sagittal sinus. Imaging: NECT, nonenhanced CT; CA, conventional angiography; MRI(A), MR imaging (angiography). Locations: LT, left thalamus; RT, right thalamus; TT, both thalami; BG, basal ganglia; HT, hypothalamus; hemorrh., hemorrhagic transformation; hydroc., hydrocephalus; n.a., data not available.

of one patient, there is no information of clinical outcome.

In contrast, the outcome seems to be much more favorable in unilateral DICVT. In the two cases reported in the literature, both patients had neuropsychological deficits, and one of them presented with hemiparesis. At follow-up, one patient recovered completely (6), and the second patient had a mild persistent deficit (5). Our patient with unilateral ICV thrombosis also presented with mild clinical symptoms (headache, short-term amnesia, and discrete hemiparesis) and recovered completely in 3 weeks.

Radiologic Findings

In most cases of DICVT, the thalamus is affected bilaterally (Table). Additional cerebral structures adjacent to the thalami such as the basal ganglia and the mesencephalon are affected in one-third of patients.

CT findings in deep venous thrombosis are bilateral hypoattenuation of the thalami (and, in some cases, the basal ganglia and adjacent white matter), whereas the venous structures, such as the thalamostriate vein, ICV, vein of Rosenthal, vein of Galen, straight sinus, and confluens sinuum are hyperattenuated (8, 10, 11). Hydrocephalus may occur as a consequence of edema and swelling of both thalami (2, 12). In cases of hemorrhagic transformation, scattered areas of hyperattenuation (usually unilateral) may be seen.

Ischemia and vasogenic edema due to thrombosis of the deep veins appear hyperintense on T2-weighted images and hypointense on T1-weighted images, although if hemorrhage has occurred, these areas appear hyperintense on T1-weighted images. The actual thrombus in a deep vein appears as an area of hyperintensity on T1-weighted images, and the area fails to enhance after administration of Gd-DTPA.

Phase-contrast MR angiography shows deep venous thrombosis as absent flow signal intensity in the deep venous system (1, 2, 6, 13). Time-of-flight MR angiography may be more difficult to interpret, because the high signal intensity of the thrombus can be mistaken as flow, although there is usually a difference in the degree of hyperintensity between flow signal intensity and thrombus.

The differential diagnoses of unilateral thalamic lesions include vascular lesions, mainly arterial thalamic infarctions (3), and tumors such as germinomas (14–17), gliomas (18), neurocytomas (19), and cavernous hemangiomas (20, 21). Particular imaging techniques and attention to specific features may be helpful in establishing the correct diagnosis. Arterial infarction can present with hyperintensity on T2-weighted images and hypointensity on T1-weighted images, similar to venous edema or venous infarction. Both entities can be differentiated by using diffusion-weighted imaging. Whereas arterial infarction with cytotoxic edema is characterized by restricted diffusion (22), venous edema with its vasogenic edema is characterized by increased diffusion (22). In venous infarction, cytotoxic edema adds to the existing

vasogenic edema leading to patchy areas of restricted and increased diffusion (22). Cavernomas are usually easily identified by a typical hypointense ring on T2- and T2*-weighted images (21). Tumors such as gliomas, neurocytomas, and germinomas have all been reported to occur in the thalamus (16, 17, 19, 23). These lesions can present as masses with compression of adjacent structures. Imaging changes found on MR and CT images, however, are not specific. Neurocytomas may contain areas of calcifications (19). Germinomas usually enhance (15) and can be characterized by elevated levels of human chorionic gonadotropin in serum and CSF (14, 15). Spectroscopy shows an increase in the choline peak in gliomas (24, 25). Perfusion imaging does not reveal significant changes in regional cerebral blood volume and mean transit time in low-grade gliomas but these decrease in the presence of high-grade gliomas (25, 26).

Arriving at the diagnosis of unilateral ICV thrombosis in our patient was not straightforward. The gradual onset of signs and symptoms in our patient made an infarction of arterial origin unlikely. A neoplastic lesion was therefore suspected at first; however, the finding on MR images and particularly the delineation of a thrombus in the ICV suggested the diagnosis of unilateral venous hypertension leading to a vasogenic edema, which could not be differentiated from an infarction. The entire resolution of all pathologic changes and the absence of subsequent defects on follow-up examinations suggest that the signal intensity changes represent pure vasogenic edema rather than definite infarction.

In contrast to this excellent outcome, patients with more extensive involvement of deep cerebral structures typically present with more severe clinical symptoms, especially when bilateral thalamic swelling induces occlusion of the third ventricle and internal hydrocephalus (27). In 12 of the 24 patients reported with DICVT (Table), signal intensity changes were limited to one thalamus ($n = 2$) or to both thalami ($n = 10$). Of those 12 patients, five recovered from all symptoms, and seven had residual neurologic deficits. When the changes extended beyond the thalami and included the basal ganglia ($n = 6$), only one patient recovered completely and two patients died. A further extension beyond these structures into the mesencephalon or pons was fatal ($n = 2$) (Table). In four patients, the clinical outcome and the location of the lesion were not specified. All patients with fatal outcome presented with either severe initial clinical symptoms or pathologic imaging findings extending beyond both thalami to adjacent structures.

The difficulty in diagnosing unilateral thrombosis of a deep cerebral vein is that bilateral deep vein thrombosis is so common and unilateral thrombosis is so rare. Remaining alert to the possibility of unilateral ICV thrombosis combined with visualization of a thrombus in the ICV on CT or MR images should establish the correct diagnosis.

Conclusion

Thrombosis of a deep cerebral vein can, very rarely, present unilaterally. In the three cases reported to date (including the one reported here), symptoms include mild neuropsychological deficits that resolve or greatly improve over time. The diagnosis rests on visualization of a unilateral thrombus in a cerebral vein on CT, MR, and MR angiography images.

References

- Bell DA, Wayne LD, Osborn AG, Harnsberger HR. **Bithalamic hyperintensity on T2-weighted MR: vascular causes and evaluation with MR angiography.** *AJNR Am J Neuroradiol* 1994;15:893–899
- Crawford SC, Digre KB, Palmer CA, et al. **Thrombosis of the deep venous drainage of the brain in adults.** *Arch Neurol* 1995;52:1101–1108
- Castaigne P, Lhermitte F, Buge A, et al. **Para-median thalamic and midbrain infarcts: clinical and neuro-pathological study.** *Ann Neurol* 1981;10:127–148
- Guberman A, Stuss D. **The syndrome of bilateral para-median thalamic infarction.** *Neurology* 1983;33:540–546
- Rousseaux M, Cabaret M, Bernati T, et al. **Residual deficit of verbal recall after a left internal cerebral vein infarct.** *Rev Neurol* 1998;154:401–407
- Forsting M, Krieger D, Seier U, Hacke W. **Reversible bilateral thalamic lesions caused by primary internal cerebral vein thrombosis: a case report.** *J Neurol* 1989;236:484–486
- Förderreuther S, Straube A, Yousry TA. **Amnestic episode caused by thrombosis of internal cerebral veins.** *Eur J Neurol* 1997;4:512–514
- Erbguth F, Brenner P, Schuierer G, et al. **Diagnosis and treatment of deep cerebral vein thrombosis.** *Neurosurg Rev* 1991;14:145–148
- Yoshii N, Seiki Y, Samejima H, et al. **Occlusion of deep cerebral veins.** *Neuroradiology* 1978;16:287–288
- Haley EC, Brashear HR, Barth JT, et al. **Deep cerebral vein thrombosis.** *Arch Neurol* 1989;46:337–340
- Eick JJ, Miller KD, Bell KA, Tutton RH. **Computed tomography of deep cerebral venous thrombosis in children.** *Radiology* 1981;140:399–402
- Gerszten PC, Welch WC, Spearman MP, et al. **Isolated deep cerebral venous thrombosis treated by direct endo-vascular thrombolysis.** *Surg Neurol* 1997;48:261–266
- Magni C, Mocaer J, Yapo P, et al. **Les thromboses veineuses cérébrales profondes.** *J Neuroradiol* 1998;25:116–122
- Kobayashi T, Kageyama N, Kida Y, et al. **Unilateral germinoma involving the basal ganglia and thalamus.** *J Neurosurg* 1981;55:56–62
- Wong GJ, Hung KL, Huang JS, Chen TY. **Unilateral thalamic tumor with atrophy of ipsilateral cortical cortex: report of a case.** *J Formos Med Assoc* 1991;90:609–611, 587
- Kim DI, Yoon PH, Ryu YH, et al. **MRI of germinomas arising from the basal ganglia and thalamus.** *Neuroradiology* 1998;40:507–511
- Moon WK, Chang KH, Kim IO, et al. **Germinomas of the basal ganglia and thalamus: MR findings and a comparison between MR and CT.** *AJR Am J Roentgenol* 1994;162:1413–1417
- Nishio S, Morioka T, Suzuki S, et al. **Thalamic gliomas: a clinicopathologic analysis of 20 cases with reference to patient age.** *Acta Neurochir* 1997;139:336–342
- Cheung YK. **Central neurocytoma occurring in the thalamus: CT and MRI findings.** *Australas Radiol* 1996;40:182–184
- Lazzarino LG, Nicolai A, Toppani D. **Unilateral cavernous angioma of the thalamus disclosed by transitional disorders in the upward gaze.** *Minerva Med* 1990;81:731–733
- Rapacki TF, Brantley MJ, Furlow TW Jr, et al. **Heterogeneity of cerebral cavernous hemangiomas diagnosed by MR imaging.** *J Comput Assist Tomogr* 1990;14:18–25
- Loeblad KO, Bassetti C, Ozdoba C, et al. **Diffusion-weighted MRI suggests the coexistence of cytotoxic and vasogenic oedema in a case of deep cerebral venous thrombosis.** *Neuroradiology* 2000;42:728–731
- Uchino M, Kitajima S, Miyazaki C, et al. **Bilateral thalamic glioma: case report.** *Neurol Med Chir* 2002;42:443–446
- Fulham MJ, Bizzi A, Dietz MJ, et al. **Mapping of brain tumor metabolites with proton MR spectroscopic imaging: clinical relevance.** *Radiology* 1992;185:675–686
- Yang D, Korogi Y, Sugahara T, et al. **Cerebral gliomas: prospective comparison of multivoxel 2D chemical-shift imaging proton MR spectroscopy, echoplanar perfusion and diffusion-weighted MRI.** *Neuroradiology* 2002;44:656–666
- Law M, Cha S, Knopp EA, et al. **High-grade gliomas and solitary metastases: differentiation by using perfusion and proton spectroscopic MR imaging.** *Radiology* 2002;222:715–721
- Johnsen S, Greenwood R, Fishman MA. **Internal cerebral vein thrombosis.** *Arch Neurol* 1973;28:205–207
- Goldenberg G, Wimmer A, Maly J. **Amnestic syndrome with a unilateral thalamic lesion: a case report.** *J Neurol* 1983;229:79–86
- Wang PY, Shen WC. **MRI in internal cerebral vein thrombosis: case note.** *Neuroradiology* 1995;37:447–448