



Discover Generics

Cost-Effective CT & MRI Contrast Agents



WATCH VIDEO

AJNR

Neurophysiologic Monitoring and Pharmacologic Provocative Testing for Embolization of Spinal Cord Arteriovenous Malformations

Yasunari Niimi, Francesco Sala, Vedran Deletis, Avi Setton, Adauri Bueno de Camargo and Alex Berenstein

This information is current as of June 3, 2025.

AJNR Am J Neuroradiol 2004, 25 (7) 1131-1138
<http://www.ajnr.org/content/25/7/1131>

Neurophysiologic Monitoring and Pharmacologic Provocative Testing for Embolization of Spinal Cord Arteriovenous Malformations

Yasunari Niimi, Francesco Sala, Vedran Deletis, Avi Setton,
Adauri Bueno de Camargo, and Alex Berenstein

BACKGROUND AND PURPOSE: Embolization of a spinal cord arteriovenous malformation (SCAVM) is still considered risky. We evaluated the efficacy and reliability of pharmacologic provocative testing with neurophysiologic monitoring in the embolization of SCAVMs.

METHODS: We retrospectively analyzed results of 60 provocative tests during 84 angiographic procedures (in 52 patients) with intended endovascular embolization. Tests included 47 sodium amytal and 56 lidocaine injections. All procedures were performed with general anesthesia and monitoring of cortical somatosensory evoked potentials (SEPs) and transcranial motor evoked potentials (MEPs). For provocative testing, 50 mg of amytal and 40 mg of lidocaine were consecutively injected through a microcatheter placed at the position of intended embolization. If SEPs and MEPs did not change, embolization was performed with N-butyl-cyanoacrylate (NBCA). If SEPs or MEPs changed, NBCA embolization was not performed from that catheter position.

RESULTS: One false-negative result occurred, with an increase in spasticity after embolization. Nineteen positive results occurred: four after amytal injection and 15 after lidocaine injections. Seven injections in a posterior spinal artery feeder resulted in loss of SEPs or MEPs. Eleven injections in the anterior spinal artery feeder and one in the posterior inferior cerebellar artery feeder resulted in loss of MEPs.

CONCLUSION: Provocative testing with amytal and lidocaine combined with neurophysiologic monitoring had a high negative predictive value and was a useful adjunct for SCAVM embolization. Both amytal and lidocaine should be used as provocative agents, and both SEPs and MEPs should be monitored.

Although embolization is now accepted as a useful treatment option for spinal cord arteriovenous malformations (SCAVMs), it is still considered a high-risk procedure because of the potential for spinal cord ischemia. To avoid neurologic complications, the blood supply to the normal spinal cord should be preserved during embolization. For this purpose, it is essential to superselectively catheterize the nidus of the malformation and to carefully analyze the vascular anatomy. Because of small and overlapping nor-

mal and pathologic vessels, the vascular supply of the spinal cord can be difficult to identify in cases of SCAVM, despite the use of magnification or additional lateral and oblique angiograms. Furthermore, because of the hemodynamic changes caused by the SCAVM, the normal spinal cord supply might not be predictable with angiographic findings alone.

In addition to careful angiographic analysis, pharmacologic provocative testing is used to identify the functional eloquence of the territory of a catheterized vessel. This testing is usually performed by clinically assessing the patient's neurologic status after the injection of a short-acting anesthetic via a microcatheter placed in a feeding artery before embolization (1). This method requires the patient to be awake. However, for spinal cord embolization procedures, we prefer to use general anesthesia to control the patient's breathing to obtain high-resolution images. This helps us to identify the small spinal cord vessels and enhances the patient's comfort during this potentially long procedure. To assess the patient's neurologic status while he or she is under general

Received July 7, 2003; accepted after revision January 5, 2004.

From the Center for Endovascular Surgery (Y.N., A.S., A.B.) and Division of Intraoperative Neurophysiology (V.D., A.B.d.C.), Hyman Newman Institute for Neurology and Neurosurgery, Beth Israel Medical Center Singer Division, New York, NY, and the Section of Neurosurgery, Department of Neurological Sciences and Vision, Verona University, Italy (F.S.).

Address reprint requests to Yasunari Niimi, MD, Center for Endovascular Surgery, Hyman Newman Institute for Neurology and Neurosurgery, Beth Israel Medical Center Singer Division, 170 East End Avenue at 87th Street, New York, NY 10128.

anesthesia, we have used neurophysiologic monitoring during pharmacologic provocative testing.

We initially started by monitoring only cortical somatosensory evoked potentials (SEPs) (2), but their reliability in assessing the corticospinal tract was not ideal (3). Therefore, we added motor evoked potentials (MEPs) to the SEPs. One of major problems of previous MEP-monitoring techniques was its invasiveness, with the need to place recording electrodes through a burr hole to elicit MEPs and to use epidurally inserted electrodes to record them (4). One of the present authors (V.D.) has established a protocol for a noninvasive technique of transcranial cortical stimulation, along with recording from peripheral muscles (5–8). Our preliminary data for this technique were published (9). Since then, our experience and understanding of neurophysiologic monitoring has increased substantially. We retrospectively reviewed our data and changed our interpretation of provocative test results from positive to negative in one case. (In this case, SEPs were thought to be lost after an injection of lidocaine into the anterior spinal artery [ASA] feeder, but this result was a fluctuation of the electrical response most likely related to the depth of anesthesia.) The purpose of this study was to update our experience with SCAVM embolization by using this monitoring technique. To our knowledge, this is the first large series of SCAVMs embolized by using SEP and MEP monitoring and pharmacologic provocative testing.

Methods

Since 1996, 52 patients with SCAVMs underwent 84 spinal cord angiographic procedures. Endovascular embolization was performed in the same setting as the angiography whenever feasible. During these procedures, 60 provocative tests were performed. The results of SEP and MEP monitoring, provocative tests, and embolization were retrospectively analyzed.

During angiographic assessment and embolization, the patients were given general anesthesia by means of a continuous infusion of propofol (100–150 $\mu\text{g/kg/min}$) and fentanyl (1 $\mu\text{g/kg/h}$). After anesthesia was induced, no inhalational anesthetics were used.

SEP and MEP Monitoring

SEP monitoring was performed in a conventional method (10). Briefly, SEPs were elicited by stimulating the right and left posterior tibial nerves at the ankle and the median nerves at the wrist with electric stimuli (40 mA, 0.2-ms duration, 4.3-Hz repetition rate). SEPs were recorded via corkscrew-type electrodes (Spinal Corkscrew Electrode; Nicolet, Madison, WI) placed on the patient's scalp over the primary sensory cortex. MEPs were elicited with transcranial electrical stimulation of the motor cortex by using corkscrew type electrodes (Nicolet). Short trains of 5–7 square-wave stimuli of 500- μs duration and 4-millisecond interstimulus intervals were applied at a 1-Hz repetition rate through electrodes placed at C1 and C2 scalp sites according to the International 10/20 EEG System. The intensity of stimulation did not exceed 200 mA. Muscle responses were recorded with needle electrodes inserted in the bilateral anterior tibialis, toe abductor, and thenar muscles. Recordings from the upper-extremity muscles were used as controls (6) for embolization of thoracic or lumbar lesions.

SEPs and MEPs were recorded at the beginning of the procedure as the baseline after the induction of general anesthesia and then immediately before provocative testing and embolization. The monitorability of SEPs and MEPs was assessed by the number of the monitorable limbs below the level of the malformation. For example, if monitorable MEPs were obtained from only the left upper and lower extremities in a patient with a cervical SCAVM, the monitorability of the MEPs was 2 of 4. If monitorable MEPs were obtained from all four extremities in a patient with a thoracic SCAVM, the monitorability was 2 of 2. When the lesion involved the conus of the spinal cord, we also monitored bulbocavernosus reflexes (BCRs). These oligosynaptic reflexes allowed us to assess the functional integrity of both afferent and efferent fibers of the pudendal nerves, as well as the reflex center located in the gray matter at the S2–S4 spinal levels. The technical details are described elsewhere (11, 12).

Provocative Testing

Provocative testing was performed just before the injection of a liquid embolic agent for embolization of all nidus-type arteriovenous malformations (AVMs) and arteriovenous fistulas (AVFs) when there was some distance between the tip of the microcatheter and the fistula site. Provocative testing was not performed for an extradural component of the malformation or if the tip of the microcatheter was close to the fistula site of an AVF. Provocative testing was also not performed before particle or coil embolization. Superselective digital subtraction angiography was performed to study the normal and abnormal vascular anatomy with the microcatheter placed as close as possible to the AVM at the location intended for embolization. Contrast material was injected under roadmap fluoroscopy to determine the optimal force for injection to distribute the anesthetic distal enough without creating reflux near the microcatheter tip. This was followed by provocative testing for neuronal function with an intra-arterial injection of 50 mg of sodium amytal. If SEPs or MEPs did not change, 20–40 mg of lidocaine was injected intra-arterially depending on the feeder size and degree of shunting. If SEPs or MEPs still did not change, embolization was performed by using n-butyl cyanoacrylate (NBCA) from that catheter position. If the amplitude of SEPs decreased by >50% or if MEPs disappeared after the injection of amytal or lidocaine, the result was considered positive, and NBCA embolization from that position was not performed. If amytal produced a positive result, the test was considered positive and lidocaine was not injected. If the lidocaine test was positive after a negative amytal test, a second provocative test in the same vascular territory was performed by injecting only lidocaine, after we advanced the microcatheter further distally or protected the normal territory with a liquid coil. Technical details are described elsewhere (8, 12). In cases of a radicular feeder to the vascular malformation, provocative testing was performed with monitoring of the MEPs of the related nerve distribution. For example, deltoid and biceps MEPs were monitored for provocative testing in the C5 radicular feeder.

Results

SEP and MEP Monitoring

SEP and MEP monitoring was attempted in all 84 procedures. Embolization was performed in 48. In 36 procedures, no feasible feeder was available for embolization, or embolization was attempted and aborted, because it was impossible to perform catheterization distal enough to consider embolization, or because provocative test results were positive. Monitorable SEPs were obtained in 66.5% (153 of 230 limbs) and

TABLE 1: Summary of provocative test results

Vessel	Sodium Amytal		Lidocaine	
	No. of Vessels	No. of Positive Results	No. of Vessels	No. of Positive Results
ASA	32	3	37	8
PSA	13	1	15	6
Posterior inferior cerebellar artery	1	0	1	1
Radicular artery	1	0	3	0
Total	47	4	56	15

TABLE 2: Summary of positive provocative test results

Agent and Vessel	Change	No. of Procedures (n = 19)
Sodium amytal		
PSA	Unilateral MEP	1
ASA	Unilateral MEP	2
ASA	Bilateral BCR, unilateral MEP	1*
Lidocaine		
PSA	Bilateral MEP	1
PSA	Bilateral MEP and SEP	1
PSA	Unilateral MEP	1
PSA	Unilateral SEP	1
PSA	Unilateral MEP and BCR	2
ASA	Unilateral MEP	4
ASA	Bilateral MEP	4
PICA	Unilateral MEP	1

* MEPs and SEPs were monitored from only one leg because of previous amputation of the other leg.

MEPs in 83.9% (198 of 230 limbs). BCRs were monitorable in 76.7% of attempted cases (66 of 86 sides in 43 patients). Sixty provocative tests were performed, with 19 positive results (31.7%). Forty-seven amytal tests were performed, with four (8.5%) positive results. Fifty-six lidocaine tests were performed, with 15 (26.8%) positive results (Table 1). Table 2 summarizes the positive results.

A positive amytal result occurred after one injection in the posterior spinal artery (PSA) and two injections in the ASA feeders, resulting in loss of MEPs. In one patient with a conus AVM, bilateral BCRs and MEPs were lost without changes in SEPs after an injection of amytal into the ASA feeder. The positive lidocaine results involved six injections in the PSA (loss of MEP in two, SEPs in one, MEPs and BCRs in two, and MEPs and SEPs in one), eight injections in the ASA (loss of MEPs in eight), and one injection in the posterior inferior cerebellar artery with loss of MEPs. Once a positive result was obtained with an injection of amytal, lidocaine was not injected from the same microcatheter position. Only one injection of an anesthetic (amytal or lidocaine) resulted in the loss of both MEPs and SEPs. Each positive test resulted in either unilateral or bilateral loss of MEPs or SEPs. Whether unilateral or bilateral responses would be lost were not predictable based on findings of superselective angiography performed with the microcatheter. In one patient, the injection of lidocaine into an ASA feeder of the cervical SCAVM resulted in the transient disappearance of

MEPs from both upper extremities without changes in lower-extremity MEPs.

Provocative Testing

After positive provocative testing and disappearance of MEPs or SEPs, MEPs or SEPs recovered to the baseline value within 15 minutes for the initial testing in all patients. Recovery of MEPs or SEPs tended to be delayed up to 1 hour after the second or third injection of amytal or lidocaine in the same patient. This was the notable limiting factor for repeating a provocative test. No patient underwent more than three sets of provocative tests during one angiography and embolization session.

Of 19 patients with positive provocative test results, embolization was aborted in six. Two patients of these patients had two consecutive positive results on repeated provocative tests, as assessed by advancing a microcatheter distally. Embolization with NBCA was possible in five patients by further advancing a microcatheter. One patient previously had two consecutive positive results during microcatheter advancement. One patient underwent embolization with diluted particles, and another patient received coils. In one patient, we performed a clinical provocative test to further clarify a positive provocative test result by using electrophysiologic monitoring. We woke the patient from general anesthesia, injected the same pharmacologic agent (lidocaine), and assessed the patient for new neurologic signs. We thought that this wake-up test was indicated in this young patient with progressive neurologic deterioration, because we were able to achieve an optimal catheter position for embolization, and NBCA embolization was believed to be safe. This patient underwent embolization with NBCA after the wake-up test showed no changes in neurologic signs. In one patient, a positive result was due to the reflux of lidocaine to the ASA, which had a common origin with the PSA feeder. This patient underwent embolization with gentle antegrade NBCA injection without reflux. In one patient, a normal PSA was found by advancing the microcatheter. NBCA embolization was performed after we protected the normal territory with liquid injectable microcoils (Table 3). Details of this procedure are reported elsewhere (13).

Only one patient had worsening of symptoms after the embolization, as shown on the results of the provocative tests. This patient had a transient worsening

TABLE 3: Actions taken after positive provocative test results

Action	No.
Aborted embolization	6*
Advanced catheter and embolization with NBCA	5†
Distal vessel protection and embolization with NBCA	1
Embolization with particles	1
Embolization with coils	1
Embolization with NBCA after negative wake-up test	1
Embolization with NBCA with less forceful injection	1

* In two patients, the procedure was aborted after two consecutive positive results during advancement of a microcatheter.

† In one patient, embolization was performed by advancing a microcatheter from the proximal positions where two positive results were obtained.

of spasticity after NBCA embolization through an ASA feeder after a negative provocative test.

Illustrative Cases

Patient 1.—A 24-year-old woman initially presented with progressive weakness and numbness of the right lower extremity since the age of 17 years. At 23 years old, she had a spinal subarachnoid hemorrhage. Spinal angiography demonstrated a SCAVM that extended from C5 to C7 (Fig 1A). She underwent two previous endovascular embolization procedures for this SCAVM, with partial occlusion of the nidus. During the second procedure, the ASA feeder was embolized from the dorsocervical artery, with substantially decreased opacification of the nidus and preservation of the ASA axis (Fig 1B). At the time of the third procedure, spontaneous thrombosis and disconnection of the ASA axis were discovered (Fig 1C). The ASA was superselectively catheterized to the origin of this remaining feeder, and digital subtraction angiography was performed (Fig 1D). Whether this vessel provided collateral supply to the normal spinal cord at the level of the occluded ASA segment was unclear on angiograms. On the basis of the negative provocative test result, this was embolized with NBCA (Fig 1E), without aggravating the patient's neurologic conditions.

Patient 2.—A 20-year-old man had a cervical SCAVM that extended from C5 to C6. He initially presented with cervical subarachnoid hemorrhage at the age of 10 years and underwent three embolization procedures to decrease the size of the nidus. He later developed a small hematomyelia without neurologic deterioration. Follow-up angiograms demonstrated a remaining cervical SCAVM supplied by the ASA and the lateral spinal artery from the vertebral artery and also the ASA from the dorsocervical artery (Fig 2A). After embolization from the ASA through the vertebral artery, the feeder from the radiculomedullary artery from the dorsocervical artery was superselectively catheterized. Superselective angiography demonstrated a feeder on the surface of the spinal cord supplying the malformation (Fig 2B–D). It was not possible to determine if this vessel supplied the functional spinal cord on the basis of angiographic find-

ings. Because the lidocaine injection from the microcatheter caused both upper-extremity MEPs to disappear, we decided not to embolize this feeder.

Discussion

In the early 1980s, we started monitoring SEPs during spinal cord angiography and embolization, with relatively good reliability (2, 14). Later, several reports noted that SEP monitoring failed to predict postoperative motor deficits (3, 15). Although both SEP and MEP monitoring is frequently used in spinal cord surgery, MEP monitoring during embolization is not often used because of its invasiveness (eg, burr-hole placement for eliciting MEPs and inserting epidural electrodes for recording them) (4). One of the present authors (V.D.) established our protocol for reliable and noninvasive MEP monitoring in the mid-1990s (7, 8). We now routinely use SEP and MEP monitoring in all spinal angiography procedures with intended embolization, including cases of SCAVMs, spinal dural AVFs, and spinal tumors. This monitoring is useful for the early detection of ischemia due to blocked flow in the spinal cord artery from vasospasm, the microcatheter, or the effects of particle embolization. One of the illustrative cases demonstrating the high sensitivity of SEP and MEP monitoring was previously reported (7). Monitorable SEPs and MEPs can be obtained, even in patients with existing moderate sensory or motor deficits. However, monitorable SEPs often cannot be obtained in patients who have lost proprioception. In addition, SEPs and MEPs are sensitive to the depth of anesthesia, even without the use of muscle relaxants or inhalational anesthetics. Therefore, it is important to obtain baseline recordings just before provocative testing is done. For thoracic and lumbar lesions, upper-extremity responses can be used as controls. For conus lesions, we also monitor BCRs. Absent BCRs are well correlated with symptoms of bladder, bowel, or sexual dysfunction. The clinical use of BCR monitoring for spine and spinal cord embolization is still under investigation.

Regarding pharmacologic provocative testing, a low dose of a short-acting barbiturate, such as amytal, predominantly suppresses neuronal activity (16) as opposed to a low dose of lidocaine, which predominantly suppresses axonal conduction in the CNS (17). Therefore, both agents should theoretically be used for better reliability of provocative testing. However, we do not inject lidocaine when we have a positive result with amytal, because it does not change the interpretation of the already-positive result. In our series, lidocaine caused more positive results than did amytal. The most likely reason is that lidocaine blocks nerve transmissions through the fibers traversing the anesthetized area, as opposed to amytal, which blocks transmission of neurons in the anesthetized area. The motor pathway affected by amytal may not be detectable because of a limited number of muscles monitored with the MEP technique. Therefore, we have added monitoring of important muscles in specific

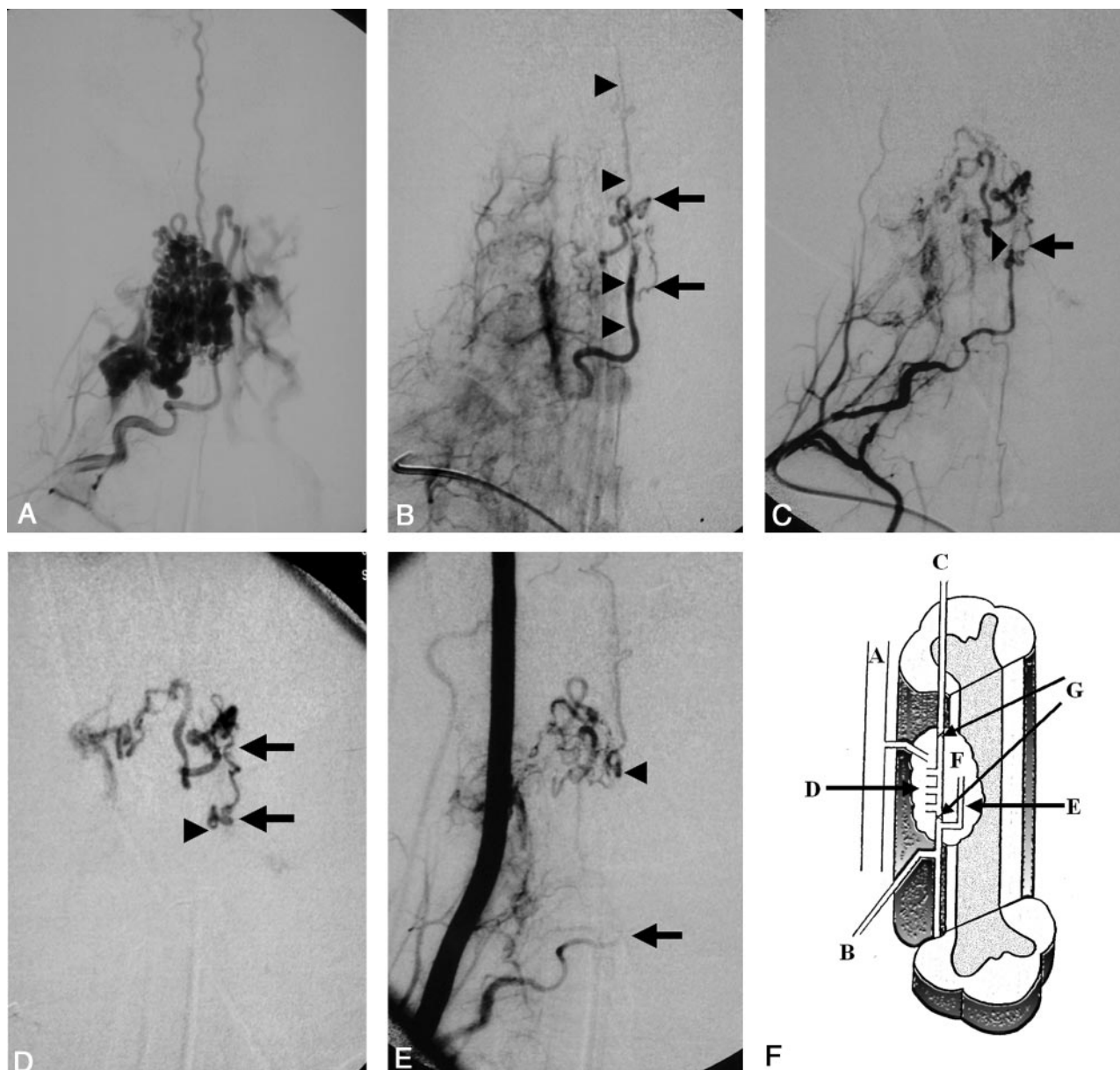


FIG 1. Illustrative patient 1.

A, Anteroposterior (AP) view of the right dorsocervical artery obtained before embolization shows a large AVM involving C5-C7 and supplied by the ASA.

B, AP right dorsocervical angiogram obtained after second embolization shows decreased opacification of the nidus with preservation of the anterior spinal axis (*arrowheads*) with one remaining indirect feeder (*arrows*).

C, AP right dorsocervical angiogram obtained 11 months after second embolization shows spontaneous occlusion of the anterior spinal axis (*arrowhead*) and the remaining indirect feeder (*arrow*). Note the decreased caliber of the ASA proximally and the increased diameter of the indirect supply. Compare with B.

D, AP superselective ASA angiogram from just before the origin of the feeder shows complete occlusion of the anterior spinal axis distal to this origin. *Arrowhead* indicates the microcatheter tip in the anterior spinal axis. *Arrows* indicate the remaining feeder. Because provocative test results were negative, we embolized the malformation from this position with NBCA; symptoms did not worsen.

E, AP right vertebral angiogram after third embolization. ASA is opacified from above, with minimal supply to the remaining nidus (*arrowhead*) mainly supplied by the vertebral artery branch. There is slow flow in the radiculomedullary artery from the right dorsocervical artery (*arrow*), which reaches the level of embolization in a later phase (not shown).

F, Schematic illustration of the AVM in relation to the spinal cord. A indicates vertebral artery; B, radiculomedullary artery from the dorsocervical artery; C, ASA; D, feeders embolized in the first two procedures; E, feeder embolized in the third procedure; F, AVM nidus; and G, ASA segment occluded in the third embolization.

cases, such as diaphragmatic MEPs for lesions in the high cervical cord. For radicular feeders to a malformation, we place additional electrodes to monitor MEPs from muscles supplied by the nerve root at the

level of the lesion. Although we have not yet had positive results from the provocative testing with these additional MEPs, the number of patients is small, and further investigation is needed.

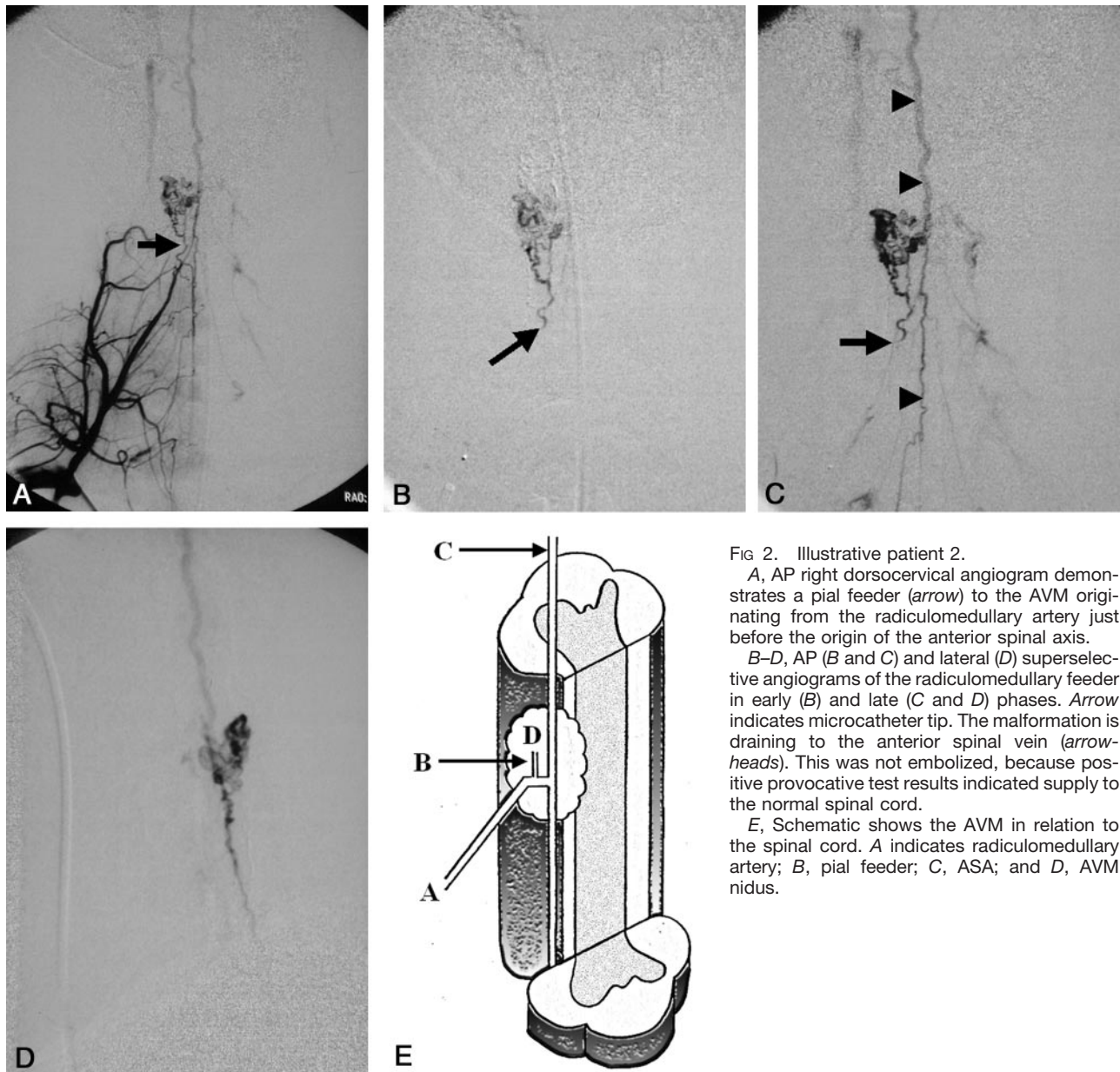


FIG 2. Illustrative patient 2.

A, AP right dorsocervical angiogram demonstrates a pial feeder (arrow) to the AVM originating from the radiculomedullary artery just before the origin of the anterior spinal axis.

B–D, AP (B and C) and lateral (D) superselective angiograms of the radiculomedullary feeder in early (B) and late (C and D) phases. Arrow indicates microcatheter tip. The malformation is draining to the anterior spinal vein (arrowheads). This was not embolized, because positive provocative test results indicated supply to the normal spinal cord.

E, Schematic shows the AVM in relation to the spinal cord. A indicates radiculomedullary artery; B, pial feeder; C, ASA; and D, AVM nidus.

In our series, one injection of amytal and five injections of lidocaine in the PSA resulted in the loss of MEPs. In contrast, changes in SEPs occurred in only two injections in the PSA, one of which resulted in changes in both MEPs and SEPs. All positive results from amytal or lidocaine injections in the ASA caused a loss of MEPs without changes in SEPs. Although the ASA is generally thought to supply the anterolateral motor pathways and the PSA supplies the posterior sensory pathways of proprioception, our observation suggests that the superselective injection of anesthetics through the PSA can affect motor pathways. This effect may be due to the rich anastomosis between ASA and PSA branches, especially in the presence of an AVM. There may also be a hemodynamic shift of the watershed zone between the ASA and the PSA territories due to the presence of the AVM or previous embolization. Among six patients

in whom MEPs were lost with provocative testing from a PSA feeder, four had supply from both the ASA and PSA. One patient had supply to the AVM from the contralateral PSA across the midline, and another patient had a common trunk between the ASA and the PSA. In four patients, angiograms showed rich anastomoses between the ASA and PSA, and two patients had undergone a previous embolization procedure. Although SEPs did not change in any patients after anesthetics were injected in the ASA, this occurred in our experience (2, 14). When we first started electrophysiologic monitoring, we injected only amytal as a provocative agent and were able to monitor only SEPs during provocative testing (1, 2). At that time, we avoided complications of embolization due to false-negative provocative results by more frequently performing the wake-up test (ie, repeating the provocative test by temporarily awak-

ening the patient and injecting amytal to evaluate clinical changes). However, waking the patient and re-inducing general anesthesia was cumbersome and uncomfortable for the patient, and interpretation of the results was sometimes difficult because the patient was too sleepy during testing. Our data suggest that both SEPs and MEPs should be monitored regardless of whether the provocative test is performed in the ASA or PSA.

The negative predictive value of our provocative test was high (97.6%), even when we considered one case of transiently increased spasticity after embolization as a false-negative finding. With the current technique of MEP monitoring, subtle changes (eg, increased spasticity without worsening of motor strength) cannot be reliably predicted. If results of a provocative test are negative, however, the malformation might be safely embolized from that catheter position by using a liquid embolic agent without causing damage. In patient 1, deciding to embolize this feeder with a liquid agent would have been difficult if provocative testing had not been available. On the basis of our previous experience, we could comfortably embolize this feeder with NBCA because of the negative provocative test result.

A positive provocative test result generally indicates normal supply to the spinal cord downstream of the tip of the microcatheter. In patient 2, this ASA branch might have been embolized if we had not performed provocative testing, because this feeder was a pial branch and did not originate from the ASA axis itself. The positive result suggested that this vessel might supply the motor pathway to both upper extremities; therefore, embolization of this vessel with NBCA was aborted. However, the number of true-positive and false-positive results is unknown, because we generally do not embolize the malformation with a liquid agent from that catheter position if the provocative test result is positive. Therefore, the sensitivity, specificity, accuracy, and positive predictive value cannot be calculated; this is a limitation of this type of clinical study. We had only one false-positive result, which occurred in a cervical SCAVM; in this case, an injection of lidocaine caused the right lower-extremity MEPs to disappear. Because the position of the microcatheter was thought to be suitable for NBCA embolization, the patient was awakened, and the lidocaine test was repeated. The second injection did not cause worsening of motor strength, and the AVM was embolized from this catheter position with a liquid agent without worsening of symptoms.

Theoretically, false-positive results can occur because the distribution pattern of the liquid embolic material differs from that of anesthetics; this reflects the different viscosities and injection forces, as well as the progressively polymerizing nature of the embolic material as opposed to persistently liquid nature of anesthetics. False-negative results can also happen for the same reasons, but these are rare in our experience. These may be owing to the relatively large doses of amytal (50 mg) and lidocaine (40 mg) used to anesthetize a small territory distal to the microcath-

eter tip, as well as the tendency of the embolic agent to penetrate less than amytal or lidocaine because of its higher viscosity and progressively polymerizing nature. Therefore, we think that this method of provocative testing tends to overestimate the risk of embolization, resulting in its high negative predictive value.

A provocative test result that is positive indicates an increased risk of functionally damaging the spinal cord during embolization with liquid material from that catheter position. The best solution is to advance the microcatheter closer to the nidus and repeat provocative testing. If the second result is negative, embolization can be performed with a liquid agent. Another solution is to protect the normal territory by using a fiber or liquid coil. If, after blocking the normal territory, the repeat result is negative, liquid embolization can be performed (13). If neither of these solutions is possible, embolization might still be performed by using particles, depending on the flow dynamics in the feeder. If none of these alternatives is possible, embolization from another feeder should be considered. In a patient in whom embolization is highly indicated but results of provocative testing at the best catheter position are positive, a wake-up test may be considered if angiography indicates a good catheter position for embolization. However, performing liquid embolization despite a positive result violates the safety margin of the provocative testing because of its tendency to overestimate the risk of embolization. Therefore, this decision should be made carefully on the basis of precise angiographic analysis and the indication for embolization. If we are confident that liquid embolization can be performed safely from a certain catheter position (eg, microcatheter tip in the venous side of a fistula), provocative testing is not necessary. We performed less provocative testing for fistulous malformations than for nidus-type malformations. In cases with previous interventions and altered anatomy, testing is of great value.

Provocative testing with amytal and lidocaine, and monitoring of MEPs and SEPs are useful adjuncts to SCAVM embolization under general anesthesia and make the procedure safer and more comfortable for the operator. However, this testing should not replace careful angiographic analysis of the vascular anatomy.

Neurophysiologic monitoring during embolization of brain AVMs is also performed in a small number of cases in our institution. However, we need more clinical experience and technical refinement to establish a reliable method. For example, transcranial electrical stimulation of the motor cortex to elicit muscle MEPs directly stimulates the subcortical axons of the motor pathways; this might cause false-negative provocative test results for cortical lesions. Deep anesthesia completely blocks trans-synaptic activation of the fast neurons of the corticospinal tract, which makes stimulation of the gray matter of the motor cortex unreliable. Multiple electrodes can obstruct angiographic visualization of the detailed vascular anatomy, even when a subtraction technique is used. For lesions in the thalamus and basal ganglia, MEP

and SEP monitoring should help in predicting the motor and sensory functional outcome of embolization. For brain stem lesions, monitoring of MEPs, SEPs, and brain stem auditory evoked potentials, with MEPs from cranial nerve-innervated muscles (eg, facial and glossopharyngeal nerves [corticobulbar tract]), may provide sufficient safety information before embolization.

Conclusion

Neurophysiologic provocative testing with amytal and lidocaine is a useful adjunct to SCAVM embolization under general anesthesia. Both MEPs and SEPs should be monitored whether provocative testing is performed in the ASA or PSA. If the result is negative, the AVM can be comfortably embolized by using a liquid embolic agent. If it is positive, aggressive embolization with a liquid agent poses a high risk of spinal cord damage. The decision should be based on careful angiographic analysis of the malformation and the indication for treatment.

References

1. Berenstein A, Choi I, Neophytides A, Benjamin V. **Endovascular treatment of spinal cord arteriovenous malformations (SCAVMs).** *AJNR Am J Neuroradiol* 1990;10:898
2. Berenstein A, Young Y, Ransohoff J, Benjamin V, Merkin H. **Somatosensory evoked potentials during spinal angiography and therapeutic transvascular embolization.** *J Neurosurg* 1984;60:777-785
3. Katsuta T, Morioka T, Hasuo K, Miyahara S, Fukui M, Masuda K. **Discrepancy between provocative test and clinical results following endovascular obliteration of spinal arteriovenous malformation.** *Surg Neurol* 1993;40:142-145
4. Katayama Y, Tsubokawa T, Hirayama T, Himi K, Koyama S, Yamamoto T. **Embolization of intramedullary spinal arteriovenous malformation fed by the anterior spinal artery with monitoring of the corticospinal motor evoked potential: case report.** *Neuro Med Chir* 1991;31:401-405
5. Kothbauer K, Deletis V, Epstein F. **Intraoperative spinal cord monitoring for intramedullary surgery: an essential adjunct.** *Pediatric Neurosurg* 1997;26:247-254
6. Kothbauer K, Deletis V, Epstein F. **Motor-evoked potential monitoring for intramedullary spinal cord tumor surgery: correlation of clinical and neurophysiological data in a series of 100 consecutive procedures [online serial].** *Neurosurg Focus* 1998;4:article 1
7. Sala F, Niimi Y, Krzan M, Berenstein A, Deletis V. **Embolization of a spinal arteriovenous malformations: correlation between motor evoked potentials and angiographic findings—technical case report.** *Neurosurgery* 1999;45:932-938
8. Sala F, Niimi Y, Berenstein A, Deletis V. **Neuroprotective role of neurophysiological monitoring during endovascular procedures in the spinal cord.** *Ann NY Acad. Sci* 2001;939:126-136
9. Niimi Y, Sala F, Deletis V, Berenstein A. **Provocative testing for embolization of spinal cord AVMs.** *Intervent Neuroradiol* 2000;6:191-194
10. Deletis V, Engler G. *The Textbook of Spinal Surgery.* Philadelphia: Lippincott-Raven; 1997:85-92
11. Deletis V, Vodusek D. **Intraoperative recording of the bulbocavernosus reflex.** *Neurosurgery* 1997;40:88-93
12. Sala F, Niimi Y. *Neurophysiology in Neurosurgery.* San Diego: Academic Press; 2002;119-151
13. Sala F, Niimi Y, Berenstein A, Deletis V. **Role of multimodality intraoperative neurophysiological monitoring during embolisation of a spinal cord arteriovenous malformation. A paradigmatic case.** *Intervent Neuroradiol* 1999;6:223-234
14. Berenstein A, Lasjaunias P. *Surgical Neuroangiography: Endovascular Treatment of Spine and Spinal Cord Vascular Lesions.* Berlin: Springer-Verlag; 1992:1-109
15. Touho H, Karasawa J, Ohnishi H, Yamada K, Ito M, Kinoshita A. **Intravascular treatment of spinal arteriovenous malformations using a microcatheter: with special reference to serial xylocaine tests and intravascular pressure monitoring.** *Surg Neurol* 1994;42:148-156
16. Doppman J, Girton M, Oldfield E. **Spinal Wada test.** *Radiology* 1986;161:319-321
17. Tanaka K, Yamasaki M. **Blocking of cortical inhibitory synapses by intravenous lidocaine.** *Nature* 1966;209:207-208