



Discover Generics

Cost-Effective CT & MRI Contrast Agents



WATCH VIDEO

AJNR

This information is current as of June 29, 2025.

Spontaneous Sphenoid Sinus Mucocele Revealed by Meningitis and Brain Abscess in a 12-Year-Old Child

Olivier Malard, Marie Gayet-Delacroix, Franck Jegoux, Alexis Faure, Philippe Bordure and Claude Beauvillain de Montreuil

AJNR Am J Neuroradiol 2004, 25 (5) 873-875
<http://www.ajnr.org/content/25/5/873>

Spontaneous Sphenoid Sinus Mucocele Revealed by Meningitis and Brain Abscess in a 12-Year-Old Child

Olivier Malard, Marie Gayet-Delacroix, Franck Jegoux, Alexis Faure, Philippe Bordure, and Claude Beauvillain de Montreuil

Summary: Sphenoid sinus mucocele is an uncommon lesion related to inflammatory disease that is diagnosed after surgery or a traumatic event. This report describes an unusual case revealed by bacterial meningitis and cerebral abscess in a 12-year-old child. CT and MR imaging allowed precise extension to the skull base in preoperative management and follow-up investigations. Endoscopic transnasal marsupialisation of the mucocele and antibiotic therapy led to complete remission. There was no evidence of recurrence after 6 months, which suggests that sphenoid mucoceles, regardless of size and complications, can be treated by endoscopic sinus surgery.

Sphenoid sinus mucocele is rare (1, 2) and generally caused by direct trauma (3). Patients with these lesions present with various symptoms and signs that may include nasal problems (4) and cranial nerve palsy (5–7). Few cases have been reported in children (8, 9), and the spontaneous case described here appears to be the first diagnosed in a child in conjunction with an infectious brain complication. Since the introduction of endoscopic techniques and instruments, the efficiency of the transnasal route has been evaluated for sphenoid mucocele removal (10, 11). There is increasing evidence in the literature that endoscopic surgery is safe and has a very low rate of recurrence. In our opinion, the transnasal approach is valid even for the management of complicated sphenoid mucocele.

Case Reports

A 12-year-old boy seen in the pediatric emergency department of the Nantes Teaching Hospital complained of severe diffuse headache and persistent fever. He had no history of cranial traumatism, sinus surgery, or chronic sinusitis. Clinical examination revealed typical acute meningitis but no neurologic palsy or ocular complications. CSF assessment confirmed a bacterial pneumococcus-related infection. Treatment was

initiated in the emergency department (injection of amoxicillin 200 mg/kg/day). CT and MR imaging revealed a sphenoid mucocele eroding adjacent bone in the roof of the sinus, associated with a 2-cm-diameter brain abscess diameter situated in the right inferior frontal area (Figs 1 and 2).

Surgical drainage was performed under general anesthesia 48 hours after antibiotic induction. The patient underwent a bilateral endoscopic procedure by the transnasal route, with video monitoring. A huge mucocele was easily located, emerging from the right sphenoid anterior wall above the choana. Bacteriologic analysis of the pus in the mucocele showed numerous leukocytes, but no bacteria. Marsupialisation was gradually achieved after endoscopic instruments were used to enlarge the sphenoid sinus. Complete removal of the mucocele produced a large opening of the rostrum. Bone erosion in the roof of the sinus had allowed the dura mater to enter the sphenoid sinus cavity (Fig 3). There was, however, no interruption of the dura mater and no CSF leakage. At the end of marsupialisation, a Merocel sponge (Medtronic Xomed, Saint Aubin Le Monial, France) was placed in the nasal cavity for 24 hours to prevent bleeding.

The patient had no postoperative complications. Because of its depth, the brain abscess was not surgically treated first. The

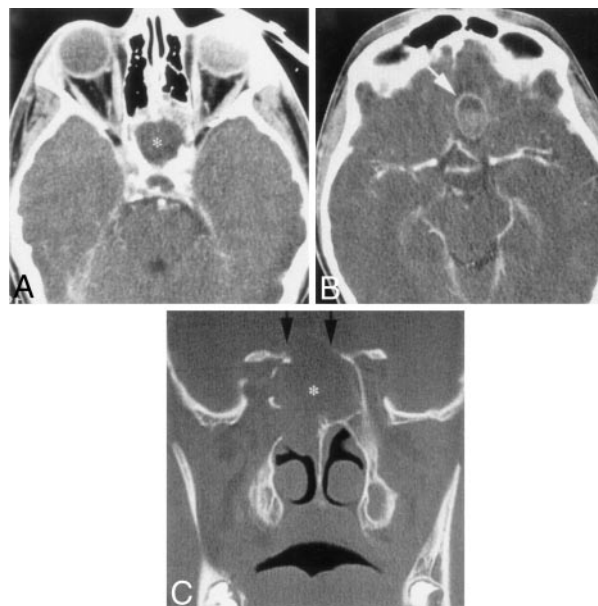


FIG 1. Preoperative CT scans

A, Axial scan showing abnormal opacification of the sphenoid sinus (asterisk [*]).

B, Axial scan showing a right frontal brain abscess (arrow) up to the sphenoid sinus.

C, Coronal scan revealing the sphenoid sinus mucocele (asterisk [*]) with osseous erosion of the sinus roof (arrows).

Received May 21, 2003; accepted after revision August 26.

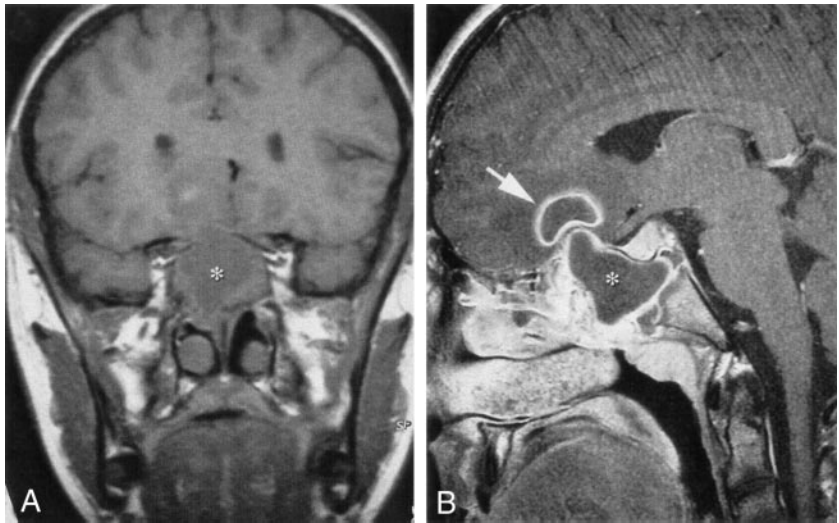
From the Service de clinique O.R.L. et de chirurgie cervico-faciale (O.M., F.J., P.B., C.B.d.M.), Service de radiologie et d'imagerie médicale (M.G.-D), and Service de neurochirurgie et neurotraumatologie (A.F.), CHU de Nantes, Nantes, France.

Address correspondence to Olivier Malard, CHU de Nantes, Hotel-Dieu, Service de clinique O. R. L. et de chirurgie cervico-faciale, Place A. Ricordeau, BP 1005, 44093 Nantes Cedex 01, France.

FIG 2. Preoperative T1-weighted MR images.

A, Coronal MR image showing abnormal opacification of the sphenoid sinus (asterisk [*]).

B, Right parasagittal MR image showing the sphenoid sinus mucocoele (asterisk [*]) and the adjacent frontal brain abscess (arrow).



patient's course was rapidly satisfactory under antibiotics. After 10 days, injections were replaced by oral administration of 6 g/day of amoxicillin, and the patient was allowed to return home. Antibiotics were maintained for 10 weeks, until CT and MR control imaging showed complete extinction of the brain abscess. No signs of recurrence were observed after 6 months of follow-up (Figs 4 and 5).

Discussion

Trauma and chronic inflammation (polypoid sinusitis) are frequent causes of mucocoele (3). In addition,

many of the mucocoeles are simply related to inflammatory disease, without accidental or postsurgical evidence; to our knowledge, mechanisms of expansion have not been elucidated in literature. The development of a sphenoid mucocoele in a child has been reported in only a small number of articles (6, 9, 12).

To our knowledge, this clinical case is the first report of sphenoid mucocoele in a child revealed by meningitis and a brain abscess. Because sphenoid sinus mucocoeles represent only about 1% of all paranasal mucocoeles (11), it is difficult to determine their standard clinical features. Pain (vertex or occipital headache) seems to be the most common symptom

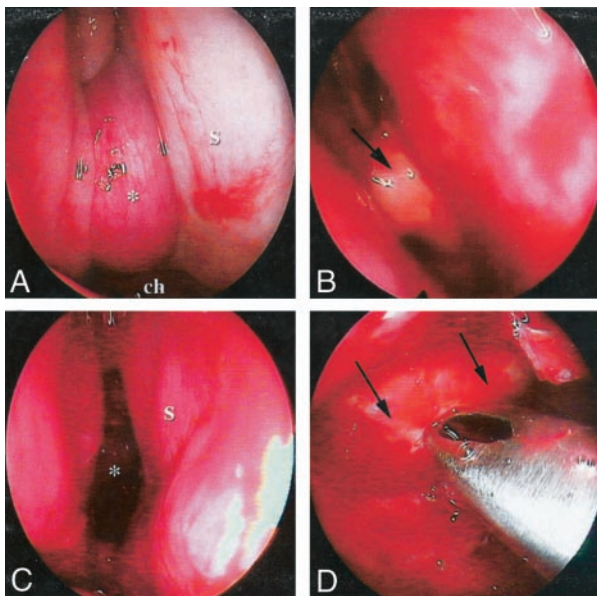


FIG 3. Endoscopic perioperative management.

A, Endoscopic view (0°) by a right transnasal route showing the mucocoele (asterisk [*]) up from the choana (ch) and laterally from the nasal septum (s).

B, Endoscopic view (0°) after opening of the mucocoele, showing a huge pus discharge (arrow).

C, After marsupialisation of the mucocoele, 0° endoscopic view of the right sphenoid sinus (asterisk [*]) lateral and posterior to the nasal septum (s).

D, Endoscopic view (60°) inside the left sphenoid cavity, showing bone erosion of the sinus roof. Dura mater, inspected directly by endoscopy, was not ruptured (arrow).

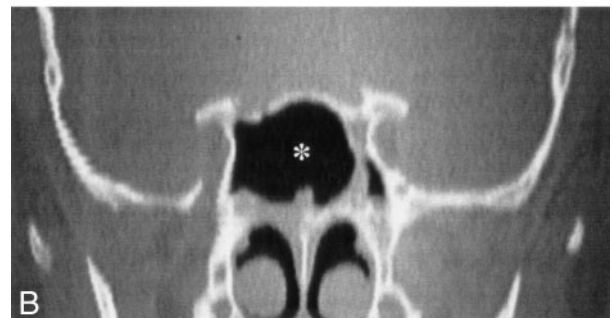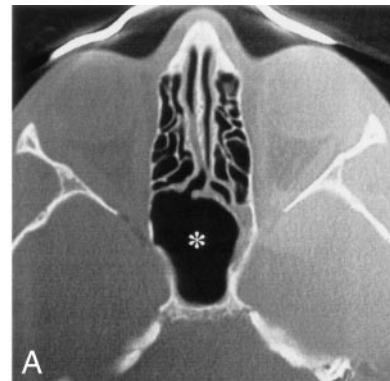


FIG 4. Postoperative axial (A) and coronal (B) CT scans 4 months after marsupialisation, showing normal opening and ventilation of the sphenoid (asterisk [*]). There is no evidence of recurrence of the mucocoele and no outstanding abscess.

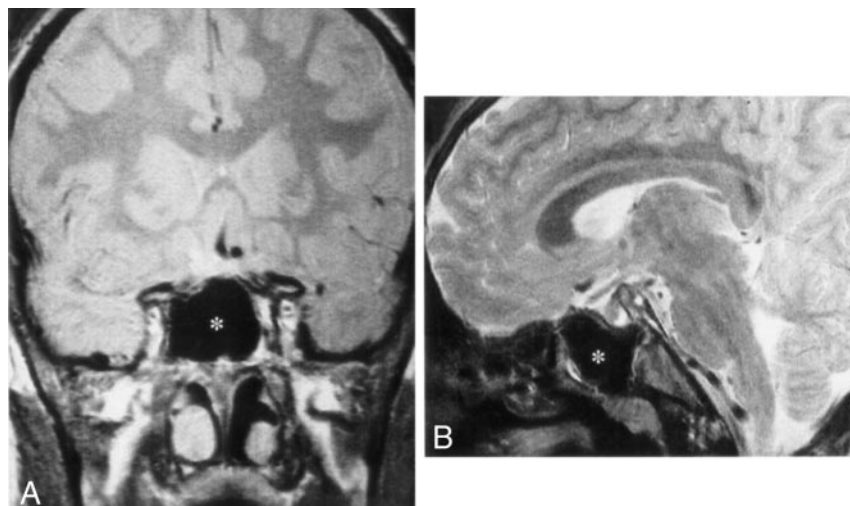


FIG 5. Preoperative coronal (A) and sagittal (B) T1-weighted MR images showing normal ventilation of the sphenoid sinus (asterisk [*]) and complete abscess extinction.

(1), and eye-threatening complications often reveal the lesion.

Accurate imaging is required to define the precise extension and boundaries of the mucocoele. Both CT and MR imaging are recommended before a surgical approach (13). Mucocoeles can show various imaging features, depending on the contents (especially water). When the water rate is high, the space occupied by the lesion is hypoattenuated at CT. The sinus wall may be very thin because of constant and prolonged pressure and be conducive to extensive destructive growth on surrounding components. Sinus cavities are hypointense on T1-weighted MR images and hyperintense on T2-weighted MR images but without enhancement. Because of a large increase in the protein rate, a hyperintense signal can be observed on T1-weighted MR images. Thus, in some cases, images can be very difficult to analyze.

An external surgical approach was used in the past for mucocoele management, but an exclusively endoscopic transnasal route has become the standard and generally uncontested treatment (4, 11). Some authors, however, have suggested using an endoscopic technique combined with a navigating system (14). In our opinion, the transnasal approach is valid even for the management of complicated sphenoid mucocoeles regardless of their size and preoperative complications. This type of treatment is clearly radical, postoperative care is reduced, and sequelae are quite limited.

References

1. Stankiewicz JA. **Sphenoid sinus mucocoele.** *Arch Otolaryngol Head Neck Surg* 1989;115:735–740
2. Sugiura N, Ochi K, Komatsuzaki Y, Koizuka I. **Powered endoscopic marsupialization for recurrent sphenoid sinus mucocoele: a case report.** *Auris Nasus Larynx* 2003; 30(Suppl):S107–S110
3. Iqbal J, Kanaan I, Ahmed M, al Homsy M. **Neurosurgical aspects of sphenoid sinus mucocoele.** *Br J Neurosurg* 1998;12:527–530
4. Hadar T, Shvero J, Nageris B, Yaniv E. **The endoscopic approach to isolated sphenoid sinus disease.** *Harefuah* 2002;141:670–672, 764
5. Shikowitz MJ, Goldstein MN, Stegnajic A. **Sphenoid sinus mucocoele masquerading as a skull base malignancy.** *Laryngoscope* 1986; 96:1405–1410
6. Casteels I, De Loof E, Brock P, et al. **Sudden blindness in a child: presenting symptom of a sphenoid sinus mucocoele.** *Br J Ophthalmol* 1992;76:502–504
7. Bauer B, Evers S, Lindorfer HW, et al. **Headache caused by a sphenoid mucocoele but presenting as an ergotamine-induced headache.** *Headache* 1997;37:460–462
8. Nicolino MP, LeBrigand B, Langevin L, et al. **Radiological case of the month: mucocoele of the sphenoid sinus.** *Arch Pediatr Adolesc Med* 1997;151:93–94
9. Froehlich P, Remond J, Morgon A. **Mucocoele of the sphenoid sinus in a child.** *Ann Otol Rhinol Laryngol* 1995;104:738–740
10. Har-el G. **Telescopic extracranial approach to frontal mucocoeles with intracranial extension.** *J Otolaryngol* 1995;24:98–101
11. Lund V. **Endoscopic management of paranasal sinus mucocoeles.** *J Laryngol Otol* 1998;112:36–40
12. Uren BA, Berkowitz RG. **Isolated inflammatory sphenoid sinus disease in children.** *Ann Otol Rhinol Laryngol* 2003;112:370–372
13. Sievers KW, Greess H, Baum U, et al. **Paranasal sinuses and nasopharynx CT and MRI.** *Eur J Radiol* 2000;33:185–202
14. Nagatani T, Saito K, Yoshida J. **Treatment of a sphenoid sinus mucocoele using an endoscope combined with a navigating system: a case report.** *J Clin Neurosci* 2001;8:456–460