



## Discover Generics

Cost-Effective CT & MRI Contrast Agents



FRESENIUS  
KABI

WATCH VIDEO

# AJNR

## Imaging of atherosclerosis

*AJNR Am J Neuroradiol* 2004, 25 (1) 151-152  
<http://www.ajnr.org/content/25/1/151>

This information is current as  
of June 19, 2025.

**Imaging of atherosclerosis.** *Neuroimaging Clinics of North America*. Zahi A. Fayad, ed. August 2002. WB Saunders. ISSN 1052-5149 Subscription price, \$184.00.

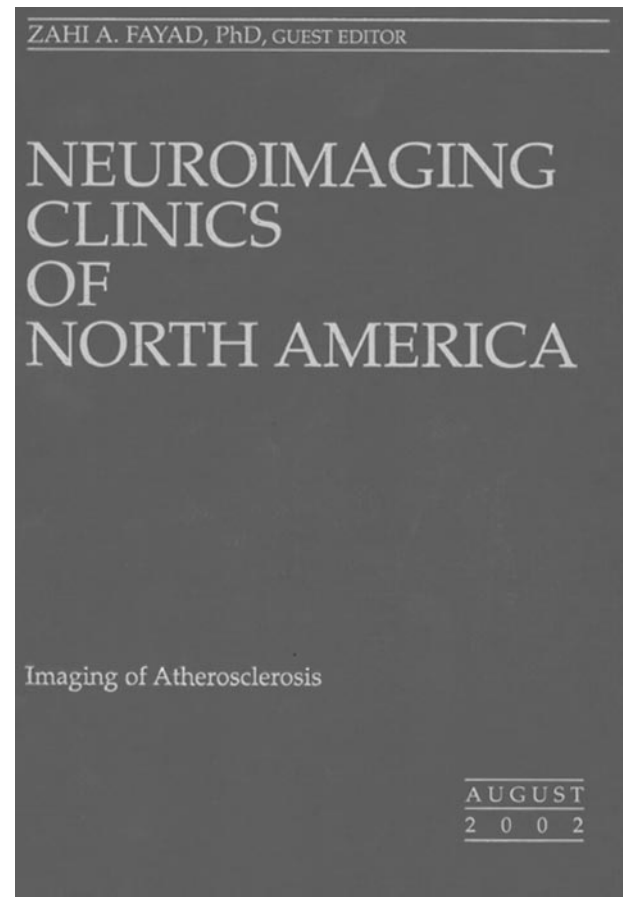
The diversity of medical disciplines represented by contributors to this book underscores the growing heterogeneity and hence complexity of the stroke field. Of its 10 chapters, four are primarily from divisions of cardiology, one from neuroradiology, two from other radiologic subspecialties, two from neurology, and one from vascular surgery. The disproportionate representation from cardiology reflects the changing composition of the teams that carry out procedures once considered to be "neuroradiologic." For example, in the United States, 65% of carotid stent procedures now are done by cardiologists.

Changing the culture that drives neurovascular activities inevitably causes a refocusing of concepts of neurovascular disease. The cardiological emphasis on the "vulnerable plaque" as a cause of (coronary) ischemic events echoes throughout the book. In various sections, it becomes a targeted imaging rationale in the evaluation of carotid artery disease, despite a contrary advisory in the splendid opening chapter on atherothrombotic plaques by Zahi A. Fayad, the guest editor of this volume, and Valentin Fuster, both of whom are affiliated with the Cardiovascular Institute at Mt. Sinai Medical School, where Dr. Fuster is chief of cardiology.

The concept of the "vulnerable plaque" suggests that in some patients the presence of a thin fibrous cap over a lipid-rich core is the requisite precondition for ischemic events, independent of degree of stenosis. When the plaque ruptures through the thin cap, it releases lipid core contents into the lumen and precipitates in situ thrombosis and occlusion. If the identification of the vulnerable plaque were to become the end point of neurovascular investigation and diagnosis, it would transform the mandate of neuroatheromatous imaging from the measurement of stenosis to identification of plaque wall characteristics. And it would support the concept of intervening on carotid atheromatous disease at lesser degrees of stenosis.

Identifying the vulnerable plaque is a real clinical imperative with regard to coronary atherosclerosis. Many myocardial infarctions seem to occur in previously asymptomatic patients whose plaques have a large lipid core that at arteriography has caused only 0–50% stenosis. MR imaging and pathologic examinations have shown that the degree of stenosis is limited because the vessel has expanded outward as the core has enlarged, rather than having intruded significantly on the lumen. Hence, for the coronary arteries, degree of stenosis may not be as reliable an index of ischemic risk as plaque characteristics.

It is known, however, that degree of carotid artery stenosis is a hallmark of relative risk for carotid territory stroke. Outward expansion of the carotid artery



wall due to an atheromatous plaque is rarely, if ever, seen. Strokes from carotid artery disease typically are due to emboli, not thrombosis per se. Further, whereas coronary atherosclerosis tends to be a diffuse process in the artery involved, extracranial carotid artery atheromatous disease is focal, typically occurring within 2 cm of the common carotid artery bifurcation.

The bottom line is that in important ways coronary artery atherosclerotic plaques often are different morphologically and pathophysiologically from carotid artery atherosclerosis. One must keep this in mind in applying lessons from this volume to neuroimaging, because it is not readily evident in the text. The neurovascular field certainly would benefit from learning how to recognize carotid plaque characteristics that predispose to stroke, but at the moment the most productive application of this information would seem to be in examining patients with advanced carotid stenosis to try to discriminate those who might benefit from endarterectomy from those who might not.

Methodologies for characterizing carotid artery plaque in relation to stroke risk and/or response to therapy are covered very nicely in chapters from the University of Washington (Chun Yuan, Zachary E. Miller, Jianning Cai, and Thomas Hatsukami), Johns Hopkins University (Bruce A. Wasserman), and the University of Copenhagen (Marie-Louise Gronholdt). The former center concentrates on MR imaging and the latter on B-mode sonography and spiral CTA methodologies. The Heidelberg group (Michael Hennerici, Kristina Szabo, and Achim Gass) provide a useful chapter on acute stroke that correlates MR imaging findings of carotid artery stenosis and circle of Willis competency with the results of MR imaging diffusion- and perfusion-weighted images.

A chapter on embolization in atherosclerosis, by interventional cardiologists Leslie Cho and Jay Yadav (Loyola University and the Cleveland Clinic, respectively), is introduced as a review of microvascular embolization, especially of the technology for detecting and preventing microembolization during coronary artery bypass grafting, carotid endarterectomy, and stent placement. Although salient facts are presented, the discussion does not clearly sort out the context and pathophysiology of large vessel versus small vessel embolic events, so the article loses its way at some points.

Jesse Weinberger (Mt. Sinai School of Medicine) has a discussion of a "new" noninvasive method for the aortic arch that has an 86% accuracy for identifying complex aortic arch plaques compared with transesophageal echocardiography. It uses a color-flow duplex Doppler sonography probe positioned in the right supraclavicular fossa. The results are based on a paper from his laboratory from 1998, which was updated in 2000 with findings from sequential examinations performed over 18 months in 89 patients. Of the latter, 38% showed regression and only about 13% experienced progression, apparently asymptomatic. It is surprising that, despite the impressive results, other reports of such noninvasive aortic arch plaque imaging are not easy to find in the literature. Two chapters cover well imaging of aortic atherosclerosis by CT/MR and by transesophageal echocardiography. They are, respectively, by Glenn A. Krinsky, of New York University Medical Center, and Marco R. Di Tullio and Shunichi Homma, of Columbia University.

The images, tables and references are well done throughout the book. Individuals who want a meaningful overview of newer concepts on vulnerable plaques and of methods for imaging atherosclerosis and its consequences will find this a book a useful introduction and a good resource.