



Get Clarity On Generics

Cost-Effective CT & MRI Contrast Agents



FRESENIUS
KABI

WATCH VIDEO

AJNR

Giant Ranula of the Neck: Differentiation from Cystic Hygroma

Andre J. Macdonald, Karen L. Salzman and H. Ric Harnsberger

AJNR Am J Neuroradiol 2003, 24 (4) 757-761

<http://www.ajnr.org/content/24/4/757>

This information is current as of August 1, 2025.

Giant Ranula of the Neck: Differentiation from Cystic Hygroma

Andre J. Macdonald, Karen L. Salzman, and H. Ric Harnsberger

BACKGROUND AND PURPOSE: Occasionally, diving ranulas may attain large dimensions (giant ranula); gross involvement of the submandibular and parapharyngeal spaces makes differentiation from other cystic neck masses, particularly cystic hygroma, difficult. As diving ranula and cystic hygroma are managed with different surgical approaches, avoidance of this pitfall is critical. Our purpose was to review the imaging findings of giant ranula and compare them with those of cystic hygroma to define those features that are helpful in differentiating these different disease entities.

METHODS: We conducted a retrospective review of all cases of ranulas that had been surgically treated at our institution in a 15-year period. These were compared with cases of cystic hygroma that involved the same anatomic regions. Images were analyzed for anatomic location and morphology, with specific attention paid to those characteristics that might assist differentiation. Giant ranula was defined as any ranula that significantly involved the parapharyngeal space in addition to the submandibular space.

RESULTS: Six patients with giant ranula and fifteen patients with cystic hygroma were reviewed. All giant ranulas retained tapered communication with the sublingual space and were homogeneous, thin-walled, anatomic defined, fluid-containing masses. One infected lesion enhanced, and another previously operated lesion demonstrated mild septation. Cystic hygroma commonly did not communicate with the sublingual space and had features of lobulation, septation and heterogeneity. Additional involvement of spaces not typically involved by ranula further assisted differentiation.

CONCLUSION: Although giant ranulas may superficially resemble cystic hygroma, several imaging features allow confident differentiation of these two entities.

Ranula is a retention cyst of the sublingual gland, which, with progressive enlargement, may rupture and extend into the surrounding soft tissues as a pseudocyst. Ranulas have classically been divided into simple and diving on the basis of the sublingual space, their site of origin (1-4). Simple ranulas remain confined to the sublingual space, whereas diving ranulas extend beyond it.

Diving ranulas typically extend posteriorly beyond the free edge of the mylohyoid muscle to enter the submandibular space. Occasionally, progressive enlargement leads to further extension from the submandibular space posterosuperiorly into the parapharyngeal space. Usually, the morphology and signal characteristics of diving ranulas allow accurate differ-

entiation from other cystic lesions of this area. Occasionally, a diving ranula may attain very large dimensions (giant ranula) by gross involvement of the submandibular and parapharyngeal spaces. These lesions may be difficult to differentiate from other cystic neck masses, especially cystic hygromas (1, 5). Correct differentiation is critical, because diving ranulas and cystic hygromas are managed with different surgical approaches. We evaluated cases of giant ranulas and cystic hygromas to define those imaging features that can help differentiate these different pathologic entities when they involve the same areas of the deeper spaces of the suprahyoid neck and oral cavity.

Methods

A retrospective review of surgically treated ranulas revealed six cases of giant ranula with available imaging studies. For the purposes of this report, giant ranula was defined as any ranula that significantly involved the parapharyngeal space in addition to the submandibular space. Simple and diving ranulas that did not extend into the parapharyngeal space were not considered for this review. Also included from the same time period were 15 cases of cystic hygroma that predominantly involved the

Received June 11, 2002; accepted after revision July 15.

From the Department of Radiology, University of Utah, Salt Lake City.

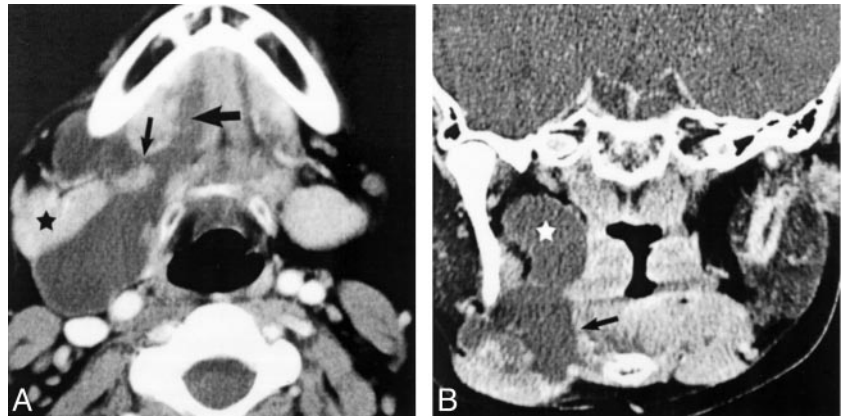
Address reprint requests to Andre J. Macdonald, MBChB, Section of Neuroradiology, Department of Radiology, 1A71 Medical Center, 50 North Medical Drive, Salt Lake City, UT 84132.

© American Society of Neuroradiology

Fig 1. Typical imaging findings of giant ranula.

A, Axial view contrast-enhanced CT scan shows a homogenous, fluid attenuation mass centered in the submandibular space with a tail of extension anteriorly into the sublingual space (*large arrow*). Note the location both anterior and posterior to the submandibular gland (*asterisk*) due to extension into the submandibular space both posterior to the mylohyoid muscle and laterally through a congenital mylohyoid defect (*small arrow*).

B, Coronal view image shows cranial extension into the parapharyngeal space (*asterisk*), without significant mass effect on the surrounding structures. Note the relation of the submandibular component to the mylohyoid muscle (*arrow*). Reprinted from Harnsberger (17) with permission from the Electronic Medical Education Resource Group.



submandibular space in an attempt to identify helpful differentiating imaging features.

All patients underwent either CT or MR imaging. Although individual parameters varied, axial contrast-enhanced CT and T1- and T2-weighted multiplanar contrast-enhanced MR imaging formed the basis of all cases examined. Six of six patients with giant ranulas were examined with CT in the axial plane, and two of the six patients underwent additional coronal imaging. IV administered contrast material and 3-mm section thickness were used in all cases. Most patients with cystic hygroma (11 of 15 patients) also underwent CT with similar parameters. Five patients (five of 15 patients) underwent MR imaging, and one underwent both CT and MR imaging. All scans and images were examined for lesion anatomic location, morphology, fluid attenuation or signal intensity, enhancement characteristics, and relationship to surrounding structures.

Results

Six cases of giant ranula were reviewed. The patients ranged in age from 13 to 47 years (mean, 31 years). All six patients were male.

Fifteen cases of cystic hygroma were reviewed. The patients ranged in age from 13 months to 74 years (mean, 27 years). Nine patients were male, and six were female.

Giant Ranula Imaging Findings

The imaging findings of all cases of giant ranula (six of six cases) were similar. All lesions (six of six lesions) were unilateral and were centered in the submandibular space. All were posterior to the submandibular gland, except for one that was both anterior and posterior to the gland.

All lesions showed contiguous involvement of the sublingual space, the so-called *tail sign*. In all cases, this was located posterior to the mylohyoid muscle and had a smooth, tapered appearance. In addition, one of these cases also showed communication laterally through a defect in the mylohyoid muscle (Fig 1A). The degree of sublingual space involvement varied widely, with half of the cases (three of six cases) involving only the posterior one-third, one case involving the posterior two-thirds, and the remaining two cases involving the entire sublingual space. All cases showed posterosuperior extension from the sub-

mandibular space into the parapharyngeal space toward the skull base (Fig 1B). Parapharyngeal space extension of ranula resulted in effacement of the fat without significant displacement or deformity of the surrounding structures. In addition to sublingual and parapharyngeal extension, two of six cases extended inferiorly from the submandibular space below the level of the hyoid bone into the anterior cervical space.

All giant ranulas were unilocular, homogeneous, well-circumscribed, fluid-containing lesions. A single lesion that showed strong, thin peripheral enhancement was proved at surgery to be secondarily infected (Fig 2A). Most of the cases (five of six cases) did not show enhancement.

One case showed subtle septation (Fig 2B and C). Although the preoperative diagnosis was diving ranula, multiple neck dissections were performed without removal of the sublingual gland. Repeated recurrence of the pseudocyst in the submandibular space resulted. The final surgical procedure included resection of the sublingual gland with no further recurrence. These septations may have been secondary to these surgical procedures.

Cystic Hygroma Imaging Findings

Fifteen cases of cystic hygroma that predominantly involved the submandibular space were included for review. Of these, only five showed contiguous extension into the sublingual space, with only two of the five having a tapered appearance similar to the tail sign described for ranula. The other three of the five lesions involving the sublingual space had a lobulated, nontapered appearance (Fig 3A). In addition to submandibular and sublingual space involvement, two of 15 cases extended into the parapharyngeal space and three of 15 involved the anterior cervical space. Additional anatomically defined spaces involved by cystic hygroma included the retropharyngeal space, carotid space, posterior cervical space, and visceral space (Fig 3A and B).

Cystic hygromas were typically well-margined fluid attenuation and signal intensity masses on CT and MR images, respectively, but 10 of 15 showed lobulation, 13 of 15 showed internal septation (Fig 3C), and three of

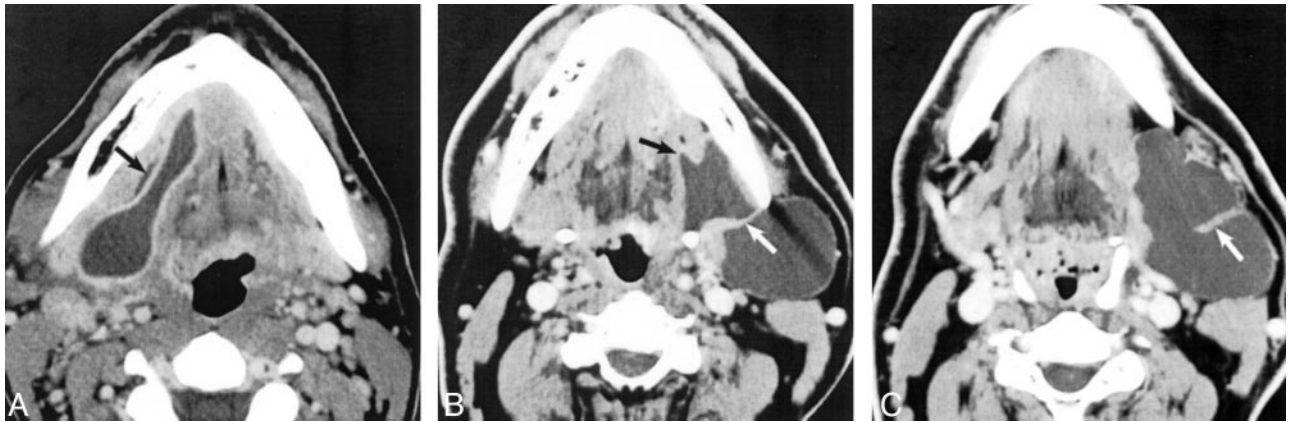

FIG 2. Atypical imaging findings of giant ranulas.

A, Axial view contrast-enhanced CT scan shows peripheral enhancement of this infected giant ranula. Note mild dilation of the submandibular gland duct (arrow) lateral to the sublingual tail in the sublingual space.

B and C, Contiguous (B slightly superior to C) axial view contrast-enhanced CT scans of a patient who had undergone seven failed neck operations. Mild septation is present (white arrows). Subsequent resection of the left sublingual gland resulted in complete resolution. Note the smooth, tapered tail extending into the sublingual space (black arrow). The lesion was pathologically proved to be a giant ranula. Reprinted from Harnsberger (17) with permission from the Electronic Medical Education Resource Group.

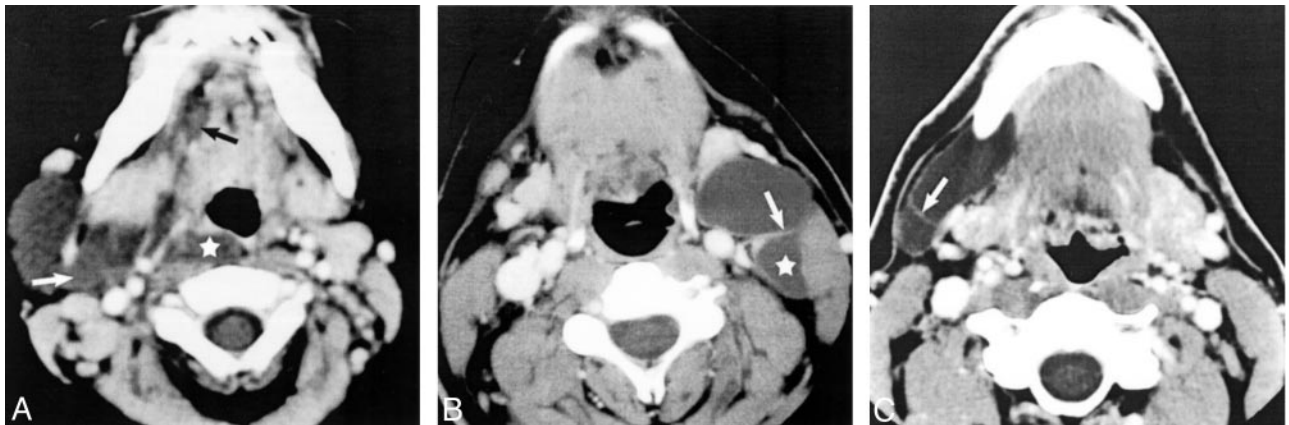


FIG 3. Axial view contrast-enhanced CT scans of three patients with cystic hygromas show helpful differentiating features.

A, Typical cystic hygroma shows lobulated involvement of the sublingual space (black arrow), mild heterogeneity (white arrow), and extension into the retropharyngeal space (asterisk).

B, Smooth, well-circumscribed cystic hygroma and septation (white arrow) and posterior extension into the posterior cervical space (asterisk) are present.

C, Subtle septation (arrow) is present in this well-circumscribed, homogenous cystic hygroma. Reprinted from Harnsberger (17) with permission from the Electronic Medical Education Resource Group.

15 showed slight heterogeneity. None of the lesions in our series showed enhancement.

Discussion

Giant ranula can be defined as any ranula that significantly involves the parapharyngeal space in addition to the submandibular space. This very large version of the typical diving ranula can be difficult to differentiate from cystic hygroma in this area on the basis of clinical and radiologic findings. Incorrect surgical management may result from confusing these two very different disease entities (1, 5).

The recommended surgical management of the giant diving ranula is removal of the ipsilateral sublingual gland via a cervical or intraoral approach. Excision of the pseudocystic extension into the deep spaces of the neck is unnecessary and places the

surrounding neurovascular structures at risk for surgical injury (1, 4, 6–9). Surgical management of cystic hygroma, on the other hand, requires localized removal of the lesion from the spaces involved (5, 10). In this project, we analyzed the imaging features of giant ranula, their anatomic location, and the differential features compared with cystic hygroma. If highly suggestive imaging findings can differentiate these two lesions, surgical planning can be affected.

Anatomy

A brief anatomic review is helpful to fully understand the fascial barriers of the oral cavity and oropharynx that direct the extension of giant diving ranula into the surrounding deep tissues (11, 12) (Fig 4).

The paired sublingual spaces are located within the floor of the mouth on either side of the midline

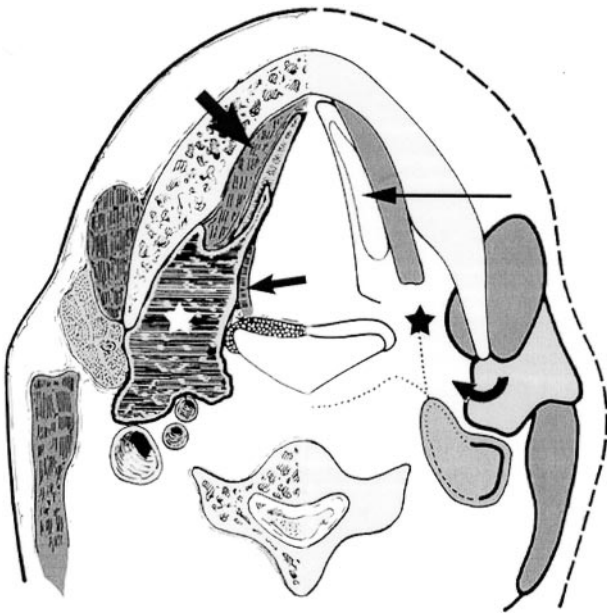


FIG 4. Giant ranula.

Diagram of axial view shows the anatomic relations of giant ranula (white asterisk), centered in the submandibular space with posterior extension into the parapharyngeal space and an anterior tail extending into the sublingual space. Note the mylohyoid muscle (large arrow) and hyoglossus muscle (small arrow), which define the margins of the sublingual space. Normal anatomic spaces are shown on the right side of the diagram: sublingual space (long thin arrow), submandibular space (black asterisk), and parapharyngeal space (curved arrow). Modified from Coit et al (12) with permission from the Radiological Society of North America.

genioglossus muscles and are not lined by fascia. They are separated from the submandibular space by the mylohyoid muscle that extends from the medial-inferior aspect of the mandible to the hyoid bone, separating the floor of the mouth and sublingual space superomedially, from the submandibular space inferolaterally.

The submandibular space is defined by the superficial investing layer of the deep cervical fascia that splits to encircle the submandibular space, with the deeper slip of fascia running along the external surface of the mylohyoid muscle and the more shallow slip paralleling the deep margin of the platysma. The two submandibular spaces therefore communicate freely with each other across the midline between the mylohyoid and platysma muscles. Posteriorly, the fascia is deficient, allowing direct communication with the parapharyngeal space posterosuperiorly and the sublingual space superomedially around the posterior free edge of the mylohyoid muscle. Congenital defects that transmit neurovascular structures may occur within the mylohyoid muscle in up to 77% of the normal population, allowing lateral free communication between the sublingual and submandibular spaces (13). Inferiorly, the fascial layers merge with the hyoid bone.

The parapharyngeal space is a complex anatomic compartment, triangular in cross section, and extending as a crescent-shaped space from the skull base

superiorly to the superior cornu of the hyoid bone inferiorly. Its fascial boundaries are formed from the surrounding spaces. Inferiorly, no fascia exists between the parapharyngeal space and the posterior aspect of the submandibular and sublingual spaces, allowing free communication among these three spaces.

Pathologic Findings

Simple ranulas represent postinflammatory retention cysts of the sublingual glands or the minor salivary glands of the sublingual space consisting of a unilocular central cystic space containing mucin with an epithelial lining. As a simple ranula enlarges, it usually ruptures and decompresses posteriorly spreading by mucus extravasation along pathways of least resistance into the submandibular space or parapharyngeal space or both, thus becoming a diving ranula. Diving ranulas are pseudocysts; the wall of a diving ranula is comprised of loose vascularized connective tissue lacking an epithelial lining (1, 3, 9, 14).

Imaging Findings

The bulk of an uncomplicated giant ranula is located within the submandibular space, with contiguous involvement of the ipsilateral sublingual and parapharyngeal spaces. It is a unilocular, homogeneous, well-defined, nonenhancing mass with fluid attenuation and signal intensity on CT scans and MR images, respectively (2, 12).

Communication between the sublingual and submandibular components typically occurs behind the posterior free edge of the mylohyoid muscle, the so-called *tail sign* (12). This typically appears as a smooth tapered continuation anteriorly into the sublingual space. In our experience, this feature has always been present. Less commonly, communication with the sublingual space may occur directly laterally via a congenital defect in the mylohyoid muscle (1, 7–9, 12). From the submandibular space, there is posterosuperior extension into the parapharyngeal space and hence to the skull base. Parapharyngeal extension tends to result in relatively little displacement of surrounding structures, even when the ranula fills a considerable part of the space, probably as a result of its low pressure fluid content and its tendency to follow the pathway of least resistance along the loose fatty tissue of the parapharyngeal space (2). Spread across the midline anteriorly within the submandibular space may occur, as may extension below the level of the hyoid bone into the anterior cervical space as the pseudocyst dissects between the fascial layers inferiorly. Recurrent and previously infected ranulas may show atypical features, such as septation and rim enhancement after the administration of contrast material (12).

Differential Diagnosis

Cystic hygroma typically presents early in life, with 50% present at birth and 90% evident by age 2 years

(10, 15). However, initial presentation later in life is well recognized (5, 10). Considering that it is generally accepted that cystic hygroma represents a congenital lesion, these cases likely represent the first manifestation of a previously unrecognized mass. Although our series of cases clearly represents a selected population (mean age, 27 years; age range, 13 months to 74 years), it serves to illustrate that initial presentation in adulthood is not uncommon.

Ranula typically presents during young adulthood, with most cases initially presenting during the third decade (1, 6, 7, 14). However, early presentation is not uncommon, and although helpful, age at time of presentation is not a reliable differentiating feature (8).

The typical appearance of cystic hygroma has been well described (12, 16). Cystic hygromas are characteristically infiltrative in nature and do not respect fascial planes typically involving contiguous anatomic regions in the neck. On images, they appear as defined but poorly circumscribed, lobulated, septated, homogeneous and fluid attenuation and signal intensity masses on CT and MR images, respectively. Previously infected lesions may show heterogeneous attenuation (CT) or signal intensity (MR), occasionally appearing hyperintense on T1-weighted images because of previous hemorrhage or high protein content. In the case of hemorrhage, fluid-fluid levels may be observed. Previously infected lesions and those with a vascular component may enhance after the administration of contrast material. Uncomplicated lesions usually do not show enhancement.

In our series of cystic hygromas selected for their location predominantly within the submandibular space, involvement of other anatomic regions not typically occupied by giant ranulas was an important differentiation feature. Two cases extended superiorly into the parapharyngeal space, but both of those cases also involved multiple other regions, including the retropharyngeal and posterior cervical spaces. Other anatomic regions involved included the carotid space, visceral space, and anterior cervical space.

Five of 15 cases showed anterior extension from the submandibular space into the sublingual space. Although most of these had a lobulated appearance, two of five lesions had a smooth tapered contour similar to those seen with ranulas. Therefore, the presence of a smooth tapered tail sign is not pathognomonic for ranula. Both cases with a classic tail sign showed other features, such as septation and lobulation, allowing differentiation from ranula. Although most of our cases were relatively well circumscribed, additional important morphologic features, such as lobulation and septation, were invariably present.

Second branchial cleft cyst, abscess, dermoid or epidermoid, and thyroglossal duct cyst are other frequently encountered cystic appearing lesions within these locations (8, 12, 16). Their differentiating features are well described in the literature, and their morphology, fluid attenuation and signal intensity

characteristics, and clinical findings usually allow accurate differentiation from giant ranulas.

Conclusion

The intention of this study was to review the imaging findings of giant ranulas, highlight the most important differential diagnostic conditions, particularly cystic hygromas, and evaluate helpful differentiating features. Uncomplicated giant ranulas usually are centered in the submandibular space with contiguous involvement of the ipsilateral sublingual, parapharyngeal, and, occasionally, anterior cervical spaces. They are unilocular, smooth, well-defined, fluid-filled, non-enhancing masses.

A lesion that shows other findings such as involvement of other anatomic spaces, lack of a smooth tapered tail extending into the sublingual space, lobulation, septation, heterogeneity, enhancement, or fluid-fluid levels in a younger patient should raise the possibility of cystic hygroma as the underlying cause. Subtle lobulation and septation in a previously non-infected, nonoperated lesion should be carefully evaluated for and may be the only differentiating features.

References

1. McClatchey K, Appelblatt N, Zarbo R, Merrel D. **Plunging ranula.** *Oral Surg Oral Med Oral Pathol* 1984;57:408-412
2. Kurabayashi T, Ida M, Yasumoto M, et al. **MRI of ranulas.** *Neuroradiology* 2000;42:917-922
3. Batsakis J, McClatchey K. **Cervical ranulas: pathology consultation.** *Ann Otol Rhinol Laryngol* 1988;97:561-562
4. Parekh D, Stewart M, Joseph C, Lawson H. **Plunging ranula: a report of three cases and review of the literature.** *Br J Surg* 1987; 74:307-309
5. Osborne T, Haller A, Levin S, Little B, King K. **Submandibular cystic hygroma resembling a plunging ranula in a neonate.** *Oral Surg Oral Med Oral Pathol* 1991;71:16-20
6. Davison M, Morton R, McIvor N. **Plunging ranula: clinical observations.** *Head Neck* 1998;20:63-68
7. Ichimura K, Ohta Y, Tayama N. **Surgical management of the plunging ranula: a review of seven cases.** *J Laryngol Otol* 1996;110: 554-556
8. Tavill M, Poje C, Wetmore R, Faro S. **Plunging ranulas in children: imaging case study of the month.** *Ann Otol Rhinol Laryngol* 1995;104:405-408
9. Zafarulla M. **Cervical mucocele (plunging ranula): an unusual case of mucous extravasation cyst.** *Oral Surg Oral Med Oral Pathol* 1986;62:63-66
10. Kennedy T, Whitaker M, Pellitteri P, Wood E. **Cystic hygroma/lymphangioma: a rational approach to management.** *Laryngoscope* 2001;111:1929-1937
11. Harnsberger HR. *Handbook of Head and Neck Imaging.* 2nd ed. St Louis: Mosby; 1995:199-223
12. Coit W, Harnsberger H, Osborn A, Smoker W, Stevens M, Lufkin R. **Ranulas and their mimics: CT evaluation.** *Radiology* 1987;163: 211-216
13. White D, Davidson C, Harnsberger H, Haller J, Kamya A. **Accessory salivary tissue in the mylohyoid boutonnière: a clinical and radiologic pseudolesion of the oral cavity.** *AJNR Am J Neuroradiol* 2001;22:406-412
14. Langlois N, Kolhe P. **Plunging ranula: a case report and a literature review.** *Hum Pathol* 1992;23:1306-1308
15. Ninh TN, Ninh TX. **Cystic hygroma in children: a report of 126 cases.** *Pediatr Surg* 1974;9:191-195
16. Koeller K, Alamo L, Adair C, Smirniotopoulos J. **Congenital cystic masses of the neck: radiologic-pathologic correlation.** *Radiographics* 1999;19:121-146
17. Harnsberger HR. *Head and Neck Digital Teaching File.* Salt Lake City: Electronic Medical Education Resource Group; 2002