



Building a Better Mousetrap: The Diagnosis of Metastatic Cervical Adenopathy

Jane L. Weissman

AJNR Am J Neuroradiol 2003, 24 (3) 297

<http://www.ajnr.org/content/24/3/297>

This information is current as
of May 31, 2025.

Building a Better Mousetrap: The Diagnosis of Metastatic Cervical Adenopathy

Technologic limitations are sometimes a boon. Whether in medicine or in other areas of science, limitations prompt a search for new and improved solutions.

In surgical oncology, once techniques for removal of tumor-bearing cervical lymph nodes became part of standard medical practice, it was important to identify those nodes preoperatively. Clever minds have devised many approaches, but the large number of methods currently used to find cancer in lymph nodes testifies eloquently to how unsatisfactory the available options are. These methods can be divided into those that evaluate the anatomic aspects of nodes and those that assess the physiological behavior of tissue. Clinical palpation, for example, relies on anatomic features. Palpation uses no special equipment but does require extensive training and experience and still yields a discouragingly low accuracy.

CT and MR imaging have improved on that rather dismal statistic by applying a variety of anatomic criteria (size, shape, attenuation, original intensity number) to differentiate normal from abnormal nodes. The inevitable tradeoff between sensitivity and specificity has limited the CT and MR imaging identification of tumor in cervical lymph nodes. If, for example, the cutoff for "normal" nodes is 0.5 cm, very few tumor-bearing nodes will be missed but many normal nodes will be misidentified as abnormal. Therefore, most radiologists use a higher cutoff. Sonography is subject to many of the limitations that plague CT and MR imaging. Color Doppler sonography evaluates the "angioarchitecture" of lymph nodes but is not widely used in this country.

Sentinel node imaging provides a "road map" of the lymphatic drainage from a tumor but no information regarding the presence or absence of tumor in those nodes. The technique entails injecting technetium-labeled sulfur colloid particles into and around a tumor. The particles migrate from the tumor into the draining lymphatics. Scintiphotos provide a map of the lymphatic drainage from the tumor, nothing more. Although this may be of use in identifying aberrant drainage pathways that would necessitate modifications of a planned neck dissection, sentinel node imaging provides no information regarding where or even whether tumor is present in nodes.

Elsewhere in the body, lymphangiography and lymphoscintigraphy have provided a combination of anatomic and physiological information about lymph nodes. Neither has proved especially useful in the neck, and both are invasive and can be technically difficult. MR imaging performed after the administration of superparamagnetic iron oxide particles, another hybrid of

anatomic and physiological assessment, is still not fully evaluated or widely available. Metabolic (functional, physiological) imaging with fluorine-18-fluorodeoxyglucose positron emission tomography is new and promising. The limited anatomic detail that positron emission tomography provides will likely require correlation with CT or MR imaging to make it widely useful.

So where does this leave us? Radiologists who attempt to diagnose tumor in cervical lymph nodes and surgeons who plan surgery with that information require more sensitive and specific information than is currently available. A new technique is needed. Add to the wish list a technique that simply applies existing equipment and technology to better advantage.

Enter dynamic contrast-enhanced MR imaging. This method, evaluated in the current issue by Fischbein et al, combines the best features of dynamic contrast-enhanced CT with the improved tissue contrast of MR imaging to open up a brave new world. Dynamic contrast-enhanced MR imaging has already proved its merit in evaluating primary tumors in a variety of locations (brain, head and neck, breast, cervix, bladder, and prostate, among others) and in cases of metastatic adenopathy.

For reasons that are as yet incompletely understood, the current study found that tumor-bearing lymph nodes handled a contrast bolus differently from non-tumor-bearing nodes. The time to peak enhancement was longer for nodes that contained tumor, the peak was lower, and the washout of contrast material was slower. These distinct differences separate the abnormal nodes from the normal nodes.

Work remains to be done. The pathophysiological underpinnings of dynamic contrast-enhanced MR imaging are yet to be elucidated. Understanding the physiology might lead to treatment for tumor-bearing nodes or, even better, to prevention of metastases. A prospective comparison of dynamic contrast-enhanced MR imaging and conventional MR imaging should prove interesting, as will the comparison of dynamic MR imaging to fluorine-18-fluorodeoxyglucose positron emission tomography.

Dynamic contrast-enhanced MR imaging seems to be an important new direction that the accurate diagnosis of head and neck metastases will take. The article by Fischbein et al shows us that the time to start moving in that direction is now.

JANE L. WEISSMAN, MD, FACR
*Departments of Radiology and Otolaryngology
Oregon Health and Science University
Portland, OR*

Myelography: Still the Gold Standard

In 1986, Modic et al (1) reported that 0.6-T MR imaging of the spine was equivalent to CT and myelography in the diagnosis of lumbar canal stenosis and herniated disk disease. They concluded that MR imaging could be viewed as an alternative to myelography. Since then, a steady decline has occurred in the number of myelograms obtained throughout the country. Speakers at national meetings discuss myelography "for historic interest only" or in the context of "malpractice" to discourage the practice of myelography. Institutions admitting to performing myelography are viewed with suspicion. This is unfortunate, because many institutions abandoned myelography in favor of MR imaging despite a paucity of good clinical studies comparing the two techniques. Neuroradiology fellows are no longer adequately trained in the techniques of myelography or the interpretation of myelograms.

A quality myelographic examination includes the combination of fluoroscopic observation, filming, thin-section CT, and use of contrast agent to exclude higher lesions. Many sites drop one or multiple components, decreasing the sensitivity and specificity of the examination and reducing the potential benefits. Advances in multidetector CT with capabilities to acquire isotropic pixels and multiplanar reformats increase the resolution of the study far beyond that of MR imaging and superior to that of conventional CT. Perhaps studies comparing myelography to MR imaging have to be repeated with the addition of this new technology.

Despite advances in MR imaging of the spine, pulse sequences, and coil design that have been accomplished during the 16 years since the article by Modic et al was published, we have always found myelography (fluoroscopic observation, filming, and thin-section CT) to be helpful in the presurgical evaluation of degenerative diseases of the cervical and lumbar spine. The MR imaging examination is sometimes indeterminate and nondiagnostic and often shows many abnormalities that are difficult to correlate with clinical data. MR myelography is disappointing because of the lack of resolution to reliably diagnose root compression and the inability to provide dynamic and functional information. The myelogram best shows whether the changes seen on MR images result in nerve root compression or obstruction to the flow of contrast material. Sometimes it is the fluoroscopic impression or plain myelographic films that are the most diagnostic.

In this issue of the *AJNR*, Drs. Bartynski and Lin report that conventional myelography is more accurate than MR imaging or follow-up CT for detecting nerve root compression in the lateral recess. Conventional myelography correctly predicted impingement

in 93% to 95% of the lateral recesses, whereas MR imaging underestimated root compression in 28% to 29% and follow-up CT underestimated root compression in 38% of the lateral recesses. Despite the shortcomings of the article, we agree with the conclusion presented by Bartynski and Lin that a myelographic study is useful for cases in which a strong clinical suspicion of nerve root compression is present and the MR images do not show the lesion or are not adequate to make this determination.

The use of surgical reports to confirm lateral recess compression is problematic; surgical impressions can be both biased and unreliable. In this article, the surgeons reported significant compression at every lateral recess explored (58 of 58 lateral recesses). This subjective assessment may have the effect of increasing the apparent sensitivity and specificity of myelography. Also, there is a high likelihood of selection bias; patients for whom there was a strong clinical suspicion of lateral recess syndrome who had nondiagnostic MR images were more likely to undergo myelography. Patients most likely to have lesions not visible on MR images underwent myelography; most patients with obvious lesions on MR images would not have undergone myelography.

Most surgeons recognize the superiority of CT myelography in visualizing bony pathologic abnormality in both the cervical and lumbar spine. However, MR imaging is a better screening study because it is less invasive, less expensive, and less labor intensive than is myelography. In most cases, MR imaging adequately defines the pathologic abnormality and allows for sound surgical decision making. Obtaining both studies for every surgical patient is not cost-effective. In clinical practice, surgeons request myelography for cases in which nerve root compression is strongly clinically suspected but for which MR imaging has failed to confirm the suspicion. The article by Bartynski and Lin supports the judicious use of myelography in such cases and emphasizes the need to train our neuroradiology fellows in the proper techniques of myelography and the interpretation of myelograms.

GARY M. MILLER, MD

Department of Radiology

WILLIAM E. KRAUSS, MD

Department of Neurologic Surgery

Mayo Foundation, Rochester, MN

References

1. Modic MT, Masaryk T, Boumphrey F, Goormastic M, Bell G. Lumbar herniated disk disease and canal stenosis: prospective evaluation by surface coil MR, CT, and myelography. *AJR Am J Roentgenol* 1986;147:757-765

Luminal and Mural Imaging of Aneurysms

*As you ramble on thru Life, Brother,
Whatever Be your Goal,
Keep your Eye upon the Doughnut,
and Not upon the Hole.*

—The Optimist's Creed

Aneurysms of the intracranial arteries are a significant source of morbidity and mortality and a significant part of the neuroradiology literature is dedicated to the analysis and evaluation of various methods of diagnosing and treating cerebral aneurysms and their associated comorbid complications. Much of the advanced training in neuroradiology is dedicated to acquiring the skills necessary to safely perform diagnostic and therapeutic endovascular procedures for the treatment of cerebral aneurysms, and newer training pathways have been developed to hone this therapeutic skill to a finer edge. It could be reasonably stated that the neuroradiologist is the fulcrum of the diagnosis and management of cerebral aneurysms.

Ever since Egas Moniz first demonstrated the intracranial arterial tree with a contrast injection in the carotid artery, angiography has been the mainstay of the diagnosis of cerebral aneurysms. It is often referred to as the *gold standard* or criterion standard by which any other method of diagnosis is measured. Although it is well accepted that, like any imaging study, angiography has its share of false-negative results, its status as the ultimate diagnostic tool for the diagnosis of cerebral aneurysms has remained essentially unchallenged. It should be remembered, however, that it is a tool used to directly evaluate only one component of the aneurysm: the lumen.

Three major modalities are used today in the imaging evaluation of suspected cerebral aneurysms: conventional angiography, MR angiography, and CT angiography. All three methods rely on luminal imaging to ascertain the correct diagnosis. In relying on these methods of diagnosis, the neuroradiologist tacitly assumes that the aneurysm wall is relatively imperceptible. This is a reasonable assumption in the case of berry aneurysms, which typically have a uniformly thin wall that parallels the contour of the aneurysm lumen. Information regarding the thickness of the aneurysm wall can be obtained by using the data used to generate CT angiographic (CTA) and MR angiographic (MRA) images, but a separate study is required when conventional angiography is employed to demonstrate the aneurysm. In a practical sense, this is not an issue, as a cross-sectional imaging examination, usually CT, has invariably been performed before cerebral angiography.

Berry aneurysms comprise most cerebral aneurysms in adults, but they are relatively rare in children. It has been stated that *atypical* aneurysms predominate in children, but this is merely a reflection of the fact that in the absence of berry aneurysms, the

more esoteric varieties take precedence. Cerebral aneurysms in children frequently do not occur with isolated subarachnoid hemorrhage. Asymptomatic lesions are common, and symptoms secondary to mass effect or parenchymal or subdural hemorrhage are seen with more frequency, in our experience. The true nature of the source of mass effect or hemorrhage is often not readily apparent. Arteriovenous fistulas, cavernous angiomas, arteriovenous malformations, hemorrhagic neoplasms, and nonaccidental trauma are all causes of spontaneous intracranial hemorrhage in a child that are equally or more frequently encountered than aneurysms. Cerebral angiography in children typically entails the use of general anesthesia. For all these reasons, a greater reliance on cross-sectional imaging is justified in the evaluation of cerebral aneurysms in children. Angiographic approaches are often reserved for combined diagnostic and therapeutic efforts.

In this issue, Sungarian et al present a case in a child with intracranial hemorrhage secondary to an anterior cerebral artery aneurysm. The diagnosis was strongly suspected after the initial nonenhanced CT study, and the patient directly underwent cerebral angiography, which failed to show an aneurysm. Another luminal imaging study was performed, MRA, which also did not show the aneurysm, for the same reason: The lumen was no longer patent. However, the authors were able to show the lesion by abandoning attempts to image the lumen and instead they concentrated on showing the aneurysm wall by administering contrast material for the MR examination. It is somewhat distressing that the diagnosis was not confirmed with follow-up luminal imaging or surgery, but the fact remains that the diagnosis was made by imaging the wall of the aneurysm and not its contents.

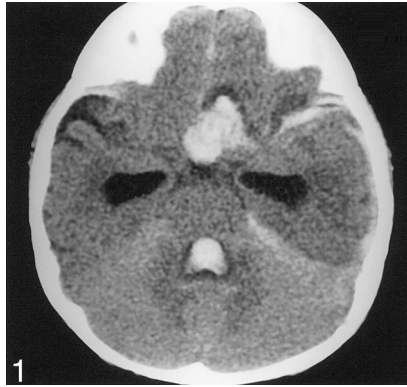
The ability to demonstrate the "lay of the land" with MRA or CTA before embarking on a catheter-directed diagnostic and therapeutic procedure is of immeasurable use to the neuroradiologist. The additional diagnostic and logistical hurdles inherent in the evaluation and treatment of cerebrovascular lesions in children accentuate this advantage. Although MRA has the distinct advantage of not using ionizing radiation, the speed and simplicity of acquisition of CTA studies make it an attractive technique in the urgent evaluation of suspected cerebrovascular lesions in children. Concerns regarding contrast agent volumes can be mitigated by judicious use of contrast material for both conventional angiography and CTA. At our pediatric hospital, we have long held the practice of performing a noninvasive luminal imaging study before conventional angiography whenever possible, and the addition of CTA to our diagnostic armamentarium has greatly enhanced our ability to do so. By using these modalities, previously unsus-

pected causes of intracranial hemorrhage can be revealed. One can minimize the incidence of false-negative catheter angiograms and subsequently perform more focused and efficient catheter-directed or surgical therapy. It also provides the opportunity to obtain a mural imaging evaluation at the same time as a luminal study, because it is sometimes to the benefit

of all for us to keep our eye on the doughnut, and not on the hole.

BLAISE V. JONES, MD
*Department of Radiology
Cincinnati Children's Hospital
Cincinnati, OH*

Case Report **Pediatric Intracranial Aneurysm: A Diagnostic Dilemma Solved with Contrast-Enhanced MR Imaging**, AJNR 24:370–372, March 2003. Figure 1 legend should read: Nonenhanced *axial* CT scan of the brain shows hydrocephalus and left anterior frontal lobe hematoma extending into the suprasellar cistern. The correct orientation of Figure 1 is shown below.



In the editorial **Building a Better Mousetrap: The Diagnosis of Metastatic Cervical Adenopathy**, Weissman JL, AJNR 24:297, March 2003, the following error occurred: In the third paragraph, the first sentence “CT and MR Imaging have improved on that rather dismal statistic by applying a variety of anatomic criteria (size, shape, attenuation, original intensity number) to differentiate normal from abnormal nodes” should read “CT and MR Imaging have improved on that rather dismal statistic by applying a variety of anatomic criteria (size, shape, attenuation, **signal intensity, number**) to differentiate normal from abnormal nodes.”