



Discover Generics

Cost-Effective CT & MRI Contrast Agents



FRESENIUS
KABI

WATCH VIDEO

AJNR

Case Review: Brain Imaging (Case Review Series)

AJNR Am J Neuroradiol 2003, 24 (2) 293
<http://www.ajnr.org/content/24/2/293>

This information is current as
of June 17, 2025.

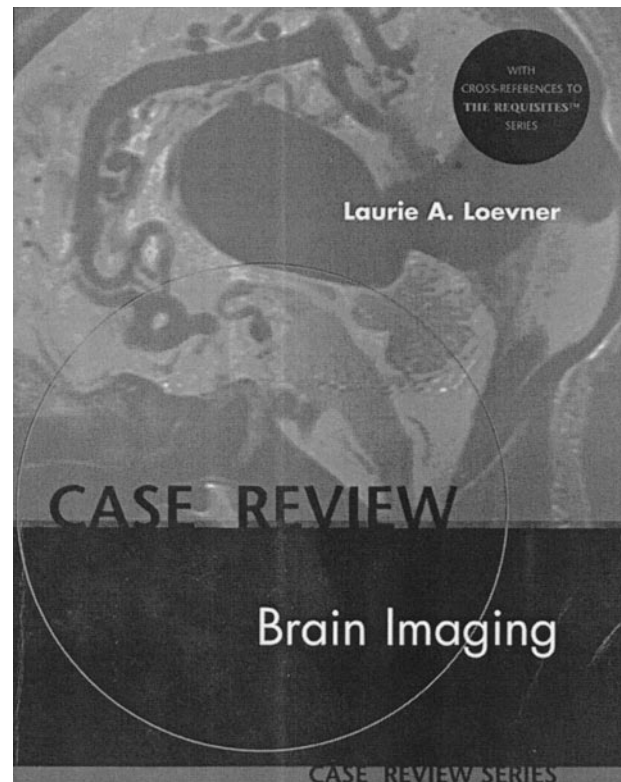
Case Review: Brain Imaging (Case Review Series)

Laurie A. Loevner. Mosby; 1999. 266 pages, 426 illustrations.

In the mold of the other soft-bound editions of the *Case Review Series* published by Mosby, Dr. Laurie Loevner has amassed 200 cases to challenge the reader in the diagnosis (predominately based on MR images) of brain abnormalities. This 266-page book is divided into three sections in which the author presents those unknown cases that she thinks are relatively straightforward (Opening Round), modestly challenging (Fair Game Cases), and reasonably difficult (Challenge Cases). One could quibble regarding this arbitrary division of case material, but no matter; the images are there to quiz the reader and the four questions that follow each set of images require the reader to supply factual information. No history is provided with the images, but that is reasonable considering the paucity of history or frank lack of history one encounters daily when reading routine MR images and CT scans.

The case material is well distributed over the major disease categories, and what is particularly important is that the material is mixed so that as one turns the page to a new set of images, one moves quickly from one category to the next. This keeps the reader's interest at a high level, and it simulates the way a consultative radiology service runs (ie, a potpourri of images). I think, however, that in a number of cases, the challenge of making the diagnosis has been diminished by the questions that are printed directly below the images. For example, directly below an MR image of a patient with gliomatosis cerebri, the question posed is, "histopathologically, what is meant by gliomatosis cerebri?" One's eyes could be averted from looking at these questions and not therefore be swayed by the question, but the material could have been set up in a different manner to avoid this. The factual material (ie, the answers to the four questions) is succinct and straightforward, often containing items of neuroradiology interest. For instance, the hypoglossal nerve is the cranial nerve most commonly affected in amyotrophic lateral sclerosis or Lhermitte Duclos disease is frequently associated with multiple hamartomas (Cowden disease). There are many more.

One is surprised, however, when reading about Creutzfeldt-Jakob disease. The author maintains this is caused by an "organism" and specifically a "slow virus"; our knowledge of Creutzfeldt-Jakob disease has progressed to a point that such a treatment should not appear in a text published in 1999. It is also a bit disappointing that more state-of-the-art imaging techniques are not included. Granted, there are a couple of MR angiograms and diffusion-weighted images, but more would have bolstered the material. For instance, in the two cases of pyogenic abscesses, it would have been ideal to include MR



spectroscopy and mention how this can differ from MR spectroscopy of a necrotic glioma. It is understood that the overall object of this book was to deal with routine imaging, but spectroscopy and diffusion, for example, are currently used on such a frequent basis that they almost could be considered in the routine category. Some of the physics of MR imaging is integrated into the answers, such as when describing the reason for the increased sensitivity of gradient-echo imaging to blood products in a case of multiple cavernous malformations.

Each case is followed by one or two references from the literature and by the appropriate citation from the text *Neuroradiology: The Requisites* by Grossman and Yousem. This case review is well indexed, so if the reader is not one to enjoy being quizzed, a specific disease can be searched for and the appropriate image(s) and factual material about the disease quickly accessed.

In summary, this publication will serve well those residents who are rotating through neuroradiology and those who are preparing for the American Board of Radiology examination. It may also be helpful for neuroradiology fellows who are preparing to earn certificates of added qualifications. It should find a place in every radiology library at institutions that offer neuroradiology training programs.