



Discover Generics

Cost-Effective CT & MRI Contrast Agents



WATCH VIDEO

AJNR

Increase in Vertebral Body Height after Vertebroplasty

Akio Hiwatashi, Toshio Moritani, Yuji Numaguchi and Per-Lennart Westesson

AJNR Am J Neuroradiol 2003, 24 (2) 185-189
<http://www.ajnr.org/content/24/2/185>

This information is current as of June 13, 2025.

Increase in Vertebral Body Height after Vertebroplasty

Akio Hiwatashi, Toshio Moritani, Yuji Numaguchi, and Per-Lennart Westesson

BACKGROUND AND PURPOSE: During clinical work, we have seen increases in vertebral body height associated with vertebroplasty, but our literature search revealed no reports as to how often and to what degree those increases occur. The purpose of this study was to document the frequency and degree of changes in vertebral body height after vertebroplasty.

METHODS: The heights of 85 vertebral bodies in 37 patients were measured before and after vertebroplasty. In addition, one adjacent vertebral body was measured in each patient as a control. Twenty-six patients had compression fractures in the thoracic spine, and 24 patients had compression fractures in the lumbar spine. Vertebroplasty was performed with a bilateral transpedicular approach by injecting polymethylmethacrylate, under biplane fluoroscopic control. Measurements were performed on preoperative MR images and on postoperative CT sagittal reformations. Anterior, central, and posterior vertebral body height measurements were obtained in the midsagittal plane.

RESULTS: The average increase in vertebral body height was 2.5 mm anteriorly, 2.7 mm centrally, and 1.4 mm posteriorly. Thirteen of 85 treated vertebrae remained unchanged. All control vertebral bodies also remained unchanged.

CONCLUSION: Vertebral body height often increases during vertebroplasty. The clinical significance of increasing vertebral body height is unknown.

Percutaneous vertebroplasty was described in 1987 (1) for the treatment of aggressive vertebral heman-gioma. It was later applied to osteolytic metastasis and osteoporotic compression fractures (2–10). The goal of percutaneous vertebroplasty is to alleviate spinal pain by stabilizing the fracture and strengthening the bone of vertebrae through the percutaneous injection of cement into the vertebral body. Although our literature search revealed no randomized studies, the procedure has been proved to be safe and effective in clinical work, and multiple case studies have documented an approximately 80% success rate for pain relief (1–10). During the clinical use of vertebroplasty, we have seen an increase in the vertebral body height in some patients as the cement is being injected. Our investigation sought to determine the frequency of increases and degree of increase in vertebral body height during vertebroplasty.

Methods

Patients

We performed vertebroplasty in 37 patients (16 men and 21 women; age range, 45–93 years; mean age, 78 years) because of painful compression fractures. The causes of fractures were osteoporosis (30 patients), metastases (three patients), multiple myeloma (two patients), and lymphoma and myelodysplasia (one patient each). A total of 85 vertebral bodies were treated in these 37 patients. Most of the fractured vertebrae were located around the thoracolumbar junction. The locations and numbers of the treated vertebrae were as follows: T4 (n = 1), T5 (n = 1), T6 (n = 4), T7 (n = 4), T8 (n = 5), T9 (n = 4), T10 (n = 9), T11 (n = 11), T12 (n = 7), L1 (n = 12), L2 (n = 10), L3 (n = 9), L4 (n = 6), and L5 (n = 2).

Vertebroplasty Technique

Vertebroplasty was performed through a bipedicular approach by using 13-gauge bone biopsy needles (Osteo-site; Cook, Bloomington, IN) placed into the anterior third of the vertebral body. The procedure was performed under biplane fluoroscopic control with use of moderate conscious sedation and local anesthesia on an outpatient basis. Balloon dilation before cement injection as in kyphoplasty (11) was not performed.

Once the two needles were placed in the vertebral body (Fig 1A), the liquid and powder polymethylmethacrylate (Cranio-plasty; Codman, Raynham, MA) was mixed with 12 g of barium sulfate (Biotrace; Bryan, Woburn, MA) and 1.2 g of tobramycin (Nebcin; Eli Lilly, Indianapolis, IN) to a doughlike consistency. The cement was thicker than toothpaste and relatively hard to inject through the 13-gauge needle by using the 1-ml syringe.

Received July 3, 2002; accepted after revision September 20.

From the Department of Diagnostic Radiology, University of Rochester Medical Center, Rochester, NY

Address reprint requests to Akio Hiwatashi, M.D., Department of Diagnostic Radiology, University of Rochester Medical Center, 601 Elmwood Ave, Box 648, Rochester, NY 14642-8648.

© American Society of Neuroradiology

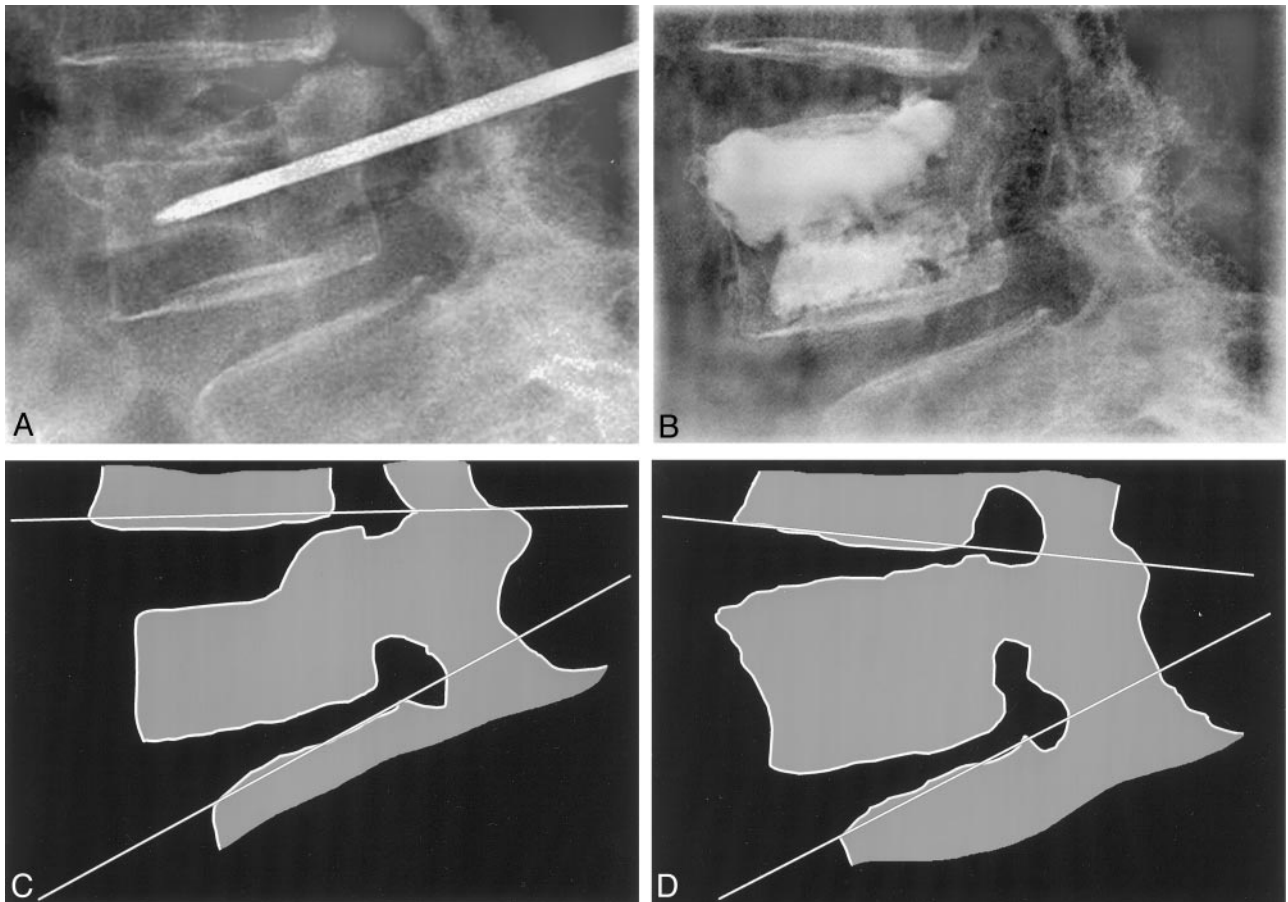


FIG 1. 85-year-old man with osteoporosis.

A, Preoperative lateral radiograph of the lumbar spine shows compression fracture of L4 with associated anterior wedging deformity. The transpedicular bone biopsy needle is in place.

B, Postoperative lateral radiograph shows considerable increase in vertebral body height, especially in the anterior (3 mm) and central (4 mm) portions.

C and D, Schematic drawings of the preoperative (C) and postoperative (D) lateral radiographs. Kyphosis is improved from 25° to 28°.

Under biplane fluoroscopic guidance (primarily lateral), the cement was injected alternatively through the left and right needles. The injection continued until the vertebral body was filled toward the posterior 20% of the vertebral body (Fig 1B and D) or there was significant leakage. If leakage was suspected, we stopped the injection temporarily and continued when there was no significant leakage into the paraspinal or disk area. If there was epidural extravasation, the injection was stopped and not attempted again. The patient was lying prone on the angiographic table during the injection, but no manipulations of the spinal column were performed before or during the procedure. After cement injection, the patient remained prone on the angiographic table until the cement was completely hard (approximately 15 minutes) and was then transferred to a regular bed. The patient remained in bed until CT had been performed. Thereafter, the patients were discharged to home as tolerated; this usually occurred approximately 2–3 hours after the procedure.

Imaging

All patients underwent preoperative MR imaging (Signa; GE Medical Systems, Milwaukee, WI) by using precontrast sagittal T1-weighted (600/14/1 [TR/TE/excitations]), fat-suppressed T2-weighted (4000/105/2), and contrast material-enhanced (Omniscan; Nycomed, Princeton, NJ) sagittal fat-suppressed T1-weighted (600/14/1) imaging. Imaging matrix was 512 × 256, field of view was 32 × 24 cm, and section thickness

was 3 mm with intersection gap of 0.2 mm. Immediately after the procedure, CT was performed (Lightspeed; GE Medical Systems) by using a section thickness of 1.25 mm with 0.6-mm overlap. Two-dimensional sagittal reformation of the CT data was performed. If there was motion during scanning, CT was repeated.

Measurement

The vertical height of the vertebral body was measured on the preoperative MR images and on the postoperative CT scans (Fig 2A-E). Measurements were performed of the anterior, central, and posterior vertebral height in the midsagittal plane by using a magnified image to the nearest 0.1 mm on a distant console (Advantage Windows 4.0; GE Medical Systems). Differences within 1 mm were considered unchanged. One untreated vertebral body adjacent to the treated vertebral body was measured as a control in each patient to evaluate the validity of our measurements.

Statistical Analysis

The statistical significance of changes in vertebral body height was evaluated with the Student's paired *t* test in which a *P* value of less than .05 was considered to indicate a statistically significant difference.

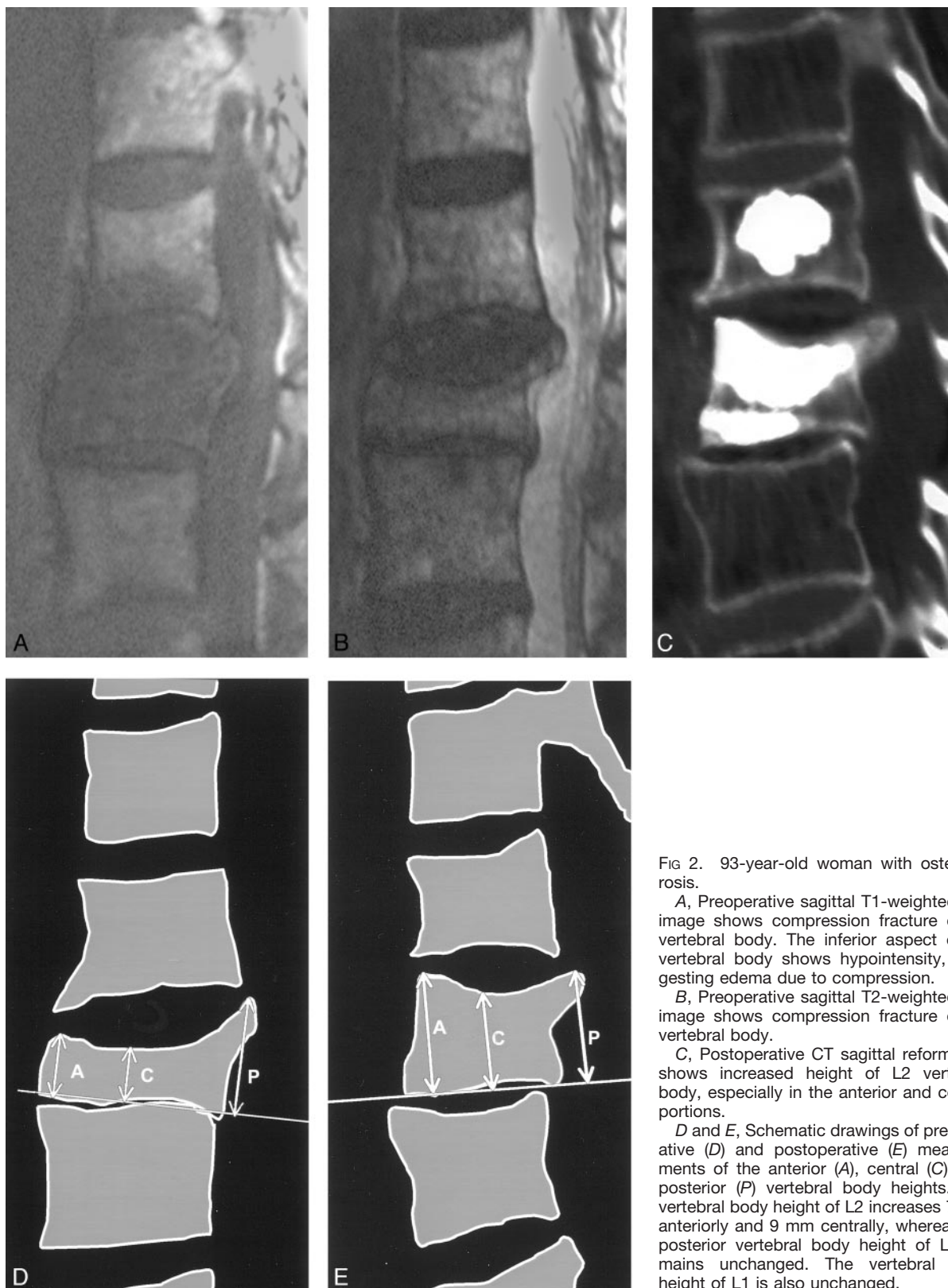


FIG 2. 93-year-old woman with osteoporosis.

A, Preoperative sagittal T1-weighted MR image shows compression fracture of L2 vertebral body. The inferior aspect of L1 vertebral body shows hypointensity, suggesting edema due to compression.

B, Preoperative sagittal T2-weighted MR image shows compression fracture of L2 vertebral body.

C, Postoperative CT sagittal reformation shows increased height of L2 vertebral body, especially in the anterior and central portions.

D and E, Schematic drawings of preoperative (D) and postoperative (E) measurements of the anterior (A), central (C), and posterior (P) vertebral body heights. The vertebral body height of L2 increases 7 mm anteriorly and 9 mm centrally, whereas the posterior vertebral body height of L2 remains unchanged. The vertebral body height of L1 is also unchanged.

Results

The vertebral body height increased in 72 of 85 treated vertebral bodies. Thirty-three vertebrae (25 patients) experienced minimal height increase (1–3 mm), whereas 39 vertebrae (24 patients) increased

more than 3 mm. The average increase in vertebral body height was 2.2 mm, with a range of 1–15 mm. The average preoperative anterior vertebral body height was 18 mm and increased to 20 mm after the procedure ($P = .006$). The average increase in ante-

rior vertebral body height was 2.5 mm (range, 1–14 mm). The average preoperative central vertebral body height was 13 mm and increased to 16 mm ($P = .001$). The average increase in central vertebral body height was 2.7 mm (range, 1–15 mm). The average preoperative posterior vertebral body height was 21 mm and increased to 23 mm ($P = .048$). The average increase in posterior vertebral body height was 1.4 mm (range, 1–9 mm). The anterior portion of vertebral body height increased in 55 vertebral bodies and remained unchanged in 30. The central portion of vertebral body height increased in 59 vertebral bodies and remained unchanged in 26. The posterior portion of vertebral body height increased in 40 vertebral bodies and remained unchanged in 45.

In patients with osteoporosis, the average increase in vertebral body height was 2.7 mm anteriorly, 2.8 mm centrally, and 1.4 mm posteriorly. In patients with neoplasia, the average increase in vertebral body height was 1.6 mm anteriorly, 1.9 mm centrally, and 1.1 mm posteriorly. However, we saw no statistical difference in height increase between these two groups of patients. There was no instance in which we could appreciate a decreased vertebral body height.

In no control instance was there a difference larger than 0.6 mm. No significant differences were noted in height of the anterior ($P = .900$), central ($P = .920$), and posterior ($P = .923$) control vertebral heights. The average pre- and postoperative vertebral body heights were the same: 24 mm anteriorly, 22 mm centrally, and 25 mm posteriorly.

The average duration between the preoperative MR images and postoperative CT scans was 14 days (range, 0–102 days). All CT scans were obtained within 4 hours of completion of procedures. No patients with a large increase in vertebral body height showed fluid- or gas-filled clefts on preoperative MR images.

The average amount of injected bone cement was 7 ml (range, 2–14 ml). There were no noteworthy complications.

Discussion

The results of this study demonstrate that vertebroplasty can increase the height of the treated vertebral body. The average increase in height was 2.2 mm (range, 1–15 mm). This confirms our clinical impression that vertebral height can increase during the procedure. Although the results of one study suggest that vertebral body height increases during kyphoplasty (11), we are not aware of any studies of vertebral body heights after vertebroplasty. The mechanism of the increase in vertebral body height is probably related to the injection of the high-viscosity bone cement under pressure. In a few patients, the increase in vertebral body height was so obvious that we could observe it as the cement was injected during the procedure (Fig 1). This seems to occur in patients whose bony walls of the vertebral bodies were intact, thus preventing leakage.

Kyphoplasty (11–14) is a variant of vertebroplasty

wherein the vertebral body is pretreated with an expandable balloon to create a space where the cement can be injected. The intention and purpose of kyphoplasty is to increase vertebral body height and to avoid injecting cement under pressure. The lack of pressure during the injection of the cement has been thought to be a safety feature to contain the cement in the precreated cavity, rather than injecting it under high pressure as in vertebroplasty. In our clinical experience, the cement injected under pressure tends to spread into preexistent cracks and spaces within the vertebral body. In this way, we believe that the cement fills the available space in the vertebral body and thereby has a better chance of stabilizing a vertebral body fracture than to fill a precreated central space. To our knowledge, no comparison has been made between vertebroplasty and kyphoplasty as to the effectiveness in relieving pain. It may, however, be possible that vertebroplasty with its more diffuse spreading of cement within the fractured vertebral body has a greater chance of stabilizing the fracture than does cement injection into a precreated space in kyphoplasty. This speculation needs to be documented with further studies.

We measured the vertebral body height on the preoperative MR images and compared it with the height on postoperative CT scans. This different methodology was prompted by the availability of images. However, measuring an adjacent untreated vertebral body in each patient assured us that the measurements were accurate and comparable. In no control instance was there a difference larger than 0.6 mm. Actually, the measurements were within 0.2 mm in most patients. We were very careful not to accept CT scans with motion since this would make the sagittal reformations unreliable for vertical measurement. The stability of our control measurements adheres to the accuracy of the measurements.

Conclusion

Vertebroplasty increased vertebral body height in 28 of 37 patients with an average of about 2 mm. Although the clinical significance of restoring some of the vertebral body height is unknown, it may explain the improved stature and amelioration of pain that many patients experience after the procedure.

Acknowledgment

The authors thank Margaret Kowaluk and Theresa Kubera for images.

References

- Galibert P, Deramond H, Rosat P, Le Gars D. Preliminary note on the treatment of vertebral angioma by percutaneous acrylic vertebroplasty [in French]. *Neurochirurgie* 1987;33:166–168
- Cortet B, Cotten A, Boutry N, et al. Percutaneous vertebroplasty in patients with osteolytic metastases or multiple myeloma. *Rev Rhum Engl Ed* 1997;64:177–183
- Cotten A, Dewatre F, Cortet B, et al. Percutaneous vertebroplasty for osteolytic metastases and myeloma: effects of the percentage of lesion filling and the leakage of methyl methacrylate at clinical follow-up. *Radiology* 1996;200:525–530

4. Kaemmerlen P, Thiesse P, Bouvard H, Biron P, Mornex F, Jonas P. **Percutaneous vertebroplasty in the treatment of metastases: technique and results [in French].** *J Radiol* 1989;70:557-562
5. Cotten A, Boutry N, Cortet B, et al. **Percutaneous vertebroplasty: state of the art.** *Radiographics* 1998;18:311-320
6. Jensen ME, Evans AJ, Mathis JM, Kallmes DF, Cloft HJ, Dion JE. **Percutaneous polymethylmethacrylate vertebroplasty in the treatment of osteoporotic vertebral body compression fractures: technical aspects.** *AJNR Am J Neuroradiol* 1997;18:1897-1904
7. Cortet B, Cotten A, Boutry N, et al. **Percutaneous vertebroplasty in the treatment of osteoporotic vertebral compression fractures: an open prospective study.** *J Rheumatol* 1999;26:2222-2228
8. Cyteval C, Sarrabere MP, Roux JO, et al. **Acute osteoporotic vertebral collapse: open study on percutaneous injection of acrylic surgical cement in 20 patients.** *AJR Am J Roentgenol* 1999;173:1685-1690
9. Barr JD, Barr MS, Lemley TJ, McCann RM. **Percutaneous vertebroplasty for pain relief and spinal stabilization.** *Spine* 2000;25:923-928
10. Mathis JM, Barr JD, Belkoff SM, Barr MS, Jensen ME, Deramond H. **Percutaneous vertebroplasty: a developing standard of care for vertebral compression fractures.** *AJNR Am J Neuroradiol* 2001;22:373-381
11. Theodorou DJ, Theodorou SJ, Duncan TD, Garfin SR, Wong WH. **Percutaneous balloon kyphoplasty for the correction of spinal deformity in painful vertebral body compression fractures.** *Clin Imaging* 2002;26:1-5
12. Belkoff SM, Mathis JM, Deramond H, Jasper LE. **An ex vivo biomechanical evaluation of a hydroxyapatite for use with kyphoplasty.** *AJNR Am J Neuroradiol* 2001;22:1212-1216
13. Lieberman IH, Dudeney S, Reinhardt MK, Bell G. **Initial outcome and efficacy of "kyphoplasty" in the treatment of painful osteoporotic vertebral compression fractures.** *Spine* 2001;26:1631-1638
14. Garfin SR, Yuan HA, Reiley MA. **New technologies in spine: kyphoplasty and vertebroplasty for the treatment of painful osteoporotic compression fractures.** *Spine* 2001;26:1511-1515