



Discover Generics

Cost-Effective CT & MRI Contrast Agents



WATCH VIDEO

AJNR

MR Imaging Findings of Spinal Dural Involvement with Wegener Granulomatosis

Sait Albayram, Osman Kizilkilie, Ibrahim Adaletli, Nuray Erdogan, Naci Kocer and Civan Islak

AJNR Am J Neuroradiol 2002, 23 (9) 1603-1606

<http://www.ajnr.org/content/23/9/1603>

This information is current as of June 20, 2025.

MR Imaging Findings of Spinal Dural Involvement with Wegener Granulomatosis

Sait Albayram, Osman Kizilkilie, Ibrahim Adaletli, Nuray Erdogan, Naci Kocer, and Civan Islak

Summary: Involvement of the brain and meninges is rare in cases of Wegener granulomatosis, occurring in 2% to 8% of cases. Meningeal involvement in association with Wegener granulomatosis has scarcely been reported as being confined to the dura mater of brain on images and is thought to represent granulomatous infiltration. There are a few reported cases of Wegener granulomatosis that document involvement of dura at the level of the spinal cord. We present the case of a 52-year-old man with Wegener granulomatosis involving the cervical spinal dura and include detailed MR imaging findings.

Wegener granulomatosis is a rare inflammatory disorder of unknown cause characterized by acute necrotizing granulomas of the upper and lower respiratory tract, with or without systemic vasculitis and focal or diffuse necrotizing glomerulitis (1, 2). Neurologic involvement, usually in the form of peripheral or cranial neuropathy, is common (22–54% of cases) but seems to have decreased as a result of effective therapeutic agents (3). Involvement of the brain and meninges is infrequent but occurs in 2% to 8% of cases (1, 2, 4, 5). Cranial meningeal involvement in association with Wegener granulomatosis may develop during the disease course or may be the initial clinical manifestation (4–7). Spinal cord involvement is rare. There are few cases reported in the literature in which the presentation of Wegener granulomatosis disease is a spinal dural mass, and no reports of the disease within the radiologic literature include detailed MR imaging findings (2, 8–10). To the best of our knowledge, the following case report of a 52-year-old man with Wegener granulomatosis disease involving the cervical spinal dura is the first to include detailed MR imaging findings.

Case Report

A 52-year-old man was admitted to the hospital because of weakness, headache, hemoptysis, and severe neck pain. The results of a neurologic examination were normal. The patient's temperature was 37°C, pulse was 70, respirations were 18, and blood pressure was 130/80 mm Hg. Findings of routine laboratory studies revealed increased erythrocyte sedimentation

rate (95 mm/h) and C-reactive protein. The results of urinalysis were normal. CT of the thorax revealed thick-walled cavities with irregular, shaggy borders. The results of a tuberculin test and specific studies for mycobacterium were negative. Serum angiotensin-converting enzyme and calcium levels were within normal limits. A diagnosis of sarcoidosis was excluded on the basis of clinical and laboratory findings. The results of an antineutrophil cytoplasmic antibodies test and indirect immunofluorescence for antineutrophil cytoplasmic antibodies were positive. A diagnosis of Wegener granulomatosis was made. A cervical MR imaging examination was ordered to assess the patient's severe neck pain. MR imaging showed two dural soft tissue masses located at the cervical and thoracic (C1–C2 and T1–T4, respectively) levels, and the dural soft-tissue masses caused indentations in the spinal cord without cord compression at the C1–C2 and T1–T4 levels (Fig 1A–F). The cranial MR imaging examination showed a small infarct on the splenic portion of corpus callosum and on the left cerebellar hemisphere. The diagnosis was considered to be spinal dural involvement and small intracranial arterial involvement of Wegener granulomatosis.

After making the diagnosis of Wegener granulomatosis, treatment with IV and orally administered corticosteroids and orally administered cyclophosphamide was started. A follow-up examination conducted 2 weeks later revealed that the neck pain and headache were totally disappeared. Follow-up cervical MR imaging performed 1 month later revealed total regression of soft tissue masses and nearly total regression of dural thickening (Fig 2A and B).

Discussion

Wegener granulomatosis is a rare disorder of unknown cause characterized by acute necrotizing granulomata of the nose, sinuses, and lung, multifocal necrotizing vasculitis affecting the small arteries and veins of the respiratory tract and other sites, and focal or diffuse glomerulonephritis (11). Although the paranasal sinuses, lungs, and kidneys are most commonly affected, many other organs can be involved (1–3, 11). The discovery that antineutrophil cytoplasmic antibodies are present in patients with Wegener granulomatosis has led to early diagnosis of the disease and improved monitoring of its progression and treatment. An immunofluorescent pattern of diffuse cytoplasmic staining has a sensitivity of at least 90% and a specificity approaching 99% for diagnosing generalized Wegener granulomatosis (12). An enzyme-linked immunosorbent assay has shown the presence of an antibody that in most cases is directed against a 29-kd serine proteinase (proteinase 3).

Neurologic involvement is not infrequent and has been reported to occur in 22% to 54% of cases, usually in the form of peripheral or cranial neuropathy (3). Involvement of the brain and meninges is reported to occur in only 2% to 8% of cases (1, 2, 4,

Received March 22, 2002; accepted after revision May 14.

From the Department of Radiology, The Cerrahpasa Medical School, Istanbul, Turkey.

Address reprint requests to Sait Albayram, MD, Department of Radiology, Division of Neuroradiology, The Cerrahpasa Medical School, 34300 Kocamustafapasa, Istanbul, Turkey.

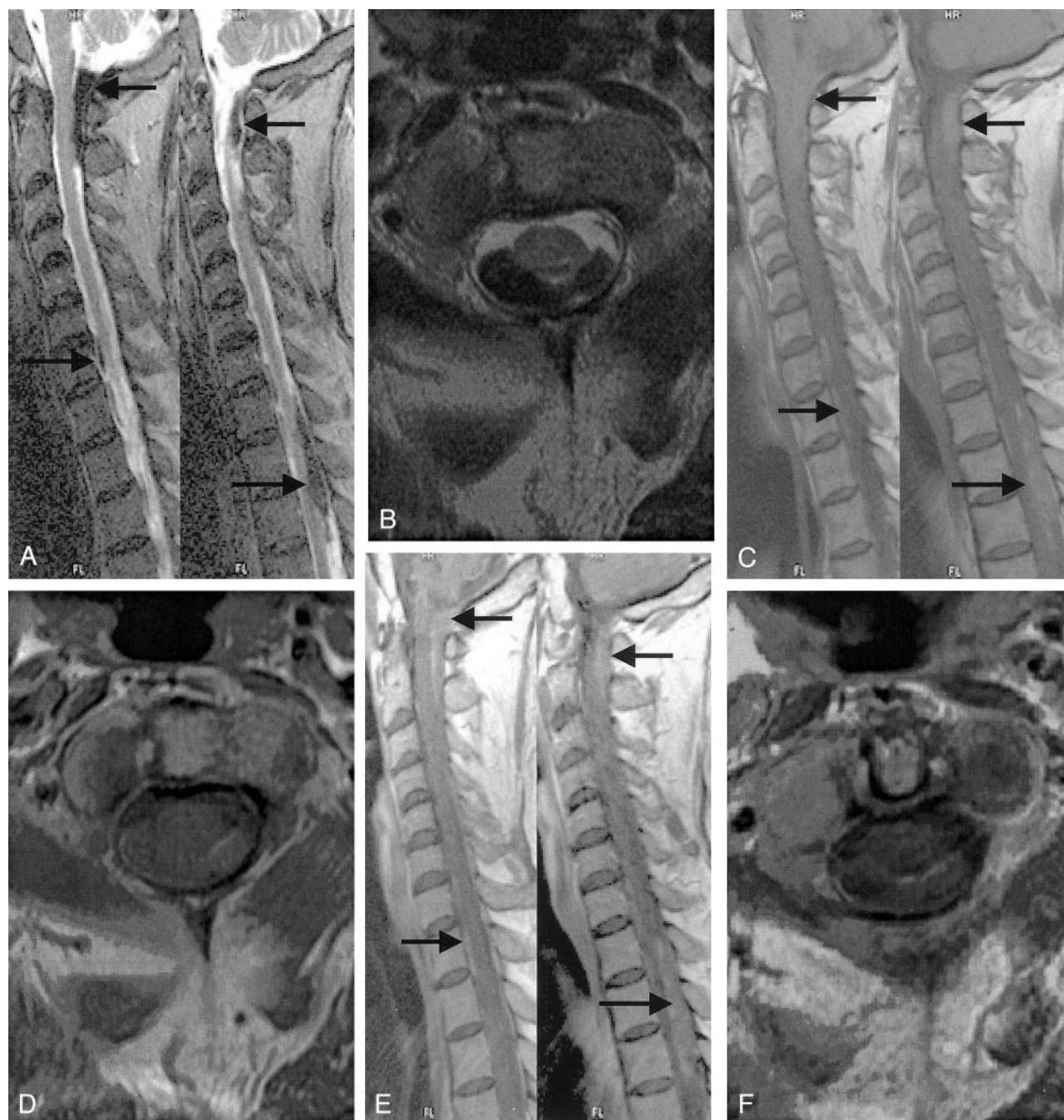


FIG 1. MR images show two dural soft-tissue masses (*arrows*) located at the cervical and thoracic (C1–C2 and T1–T4, respectively) levels. The dural soft tissue masses caused indentation to the spinal cord without prominent cord compression. They wrapped around the spinal cord, especially posteriorly at the cervical level and left posterolaterally at the thoracic level. These lesions are minimally hyperintense to spinal cord on T1-weighted MR images and prominently hypointense on T2-weighted images. Contrast-enhanced MR images reveal no prominent enhancement in these lesions except minimal peripheral enhancement. No abnormal signal intensity is present in the spinal cord on the T2-weighted images at the level of the lesions. At the lower cervical and upper thoracic levels, minimal anterior dural thickening with the same signal intensity features of dural masses on the C7–T1–T2 levels are also noted (*arrow*).

A, Sagittal T2-weighted (4550/137/2 [TR/TE/NEX]) MR image.

B, Axial T2-weighted (4360/100/2) MR image.

C, Sagittal T1-weighted (617/13/2) MR image.

D, Axial T1-weighted (516/13/2) MR image.

E, Sagittal contrast-enhanced T1-weighted (617/13/2) MR image obtained after the IV administration of contrast material.

F, Axial contrast-enhanced T1-weighted (516/13/2) MR image obtained after the IV administration of contrast material.

5). Drachman (13) described three mechanisms by which the nervous system can be affected: 1) necrotizing vasculitis involving the cerebral, spinal, and

radicular vasculature (28% of total cases); 2) contiguous extension from extravascular granulomas in the paranasal sinuses, nasal cavities, or orbits (26%); and

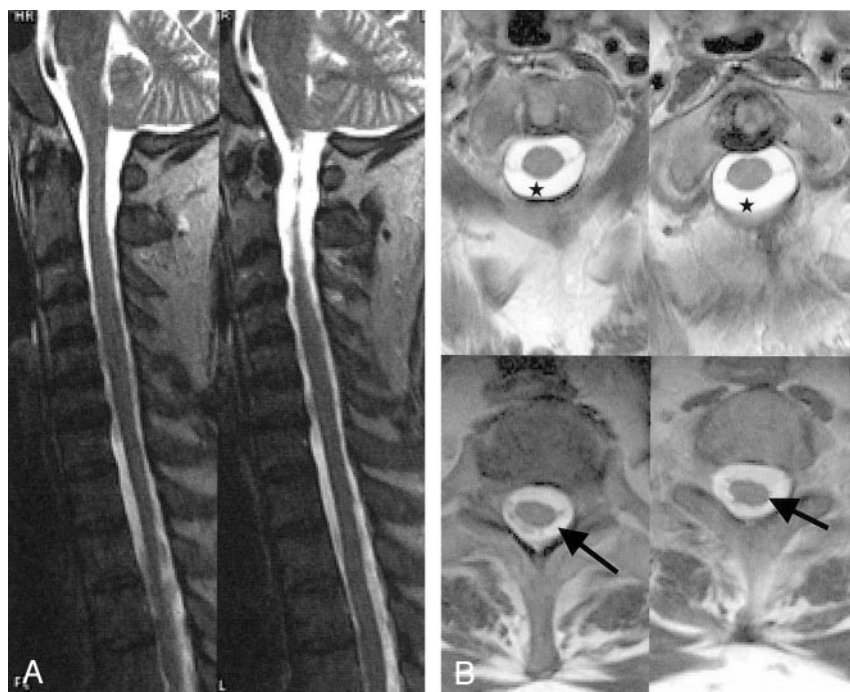


FIG 2. Follow-up MR images obtained 1 month later, after treatment.

A, Two sagittal T2-weighted (4550/137/2) MR images.

B, Four contrast-enhanced axial T1-weighted (4360/100/2) MR images reveal regression of posterior dural soft tissue masses (stars and arrows).

3) primary necrotizing granulomas in the skull, meninges, cranial nerves, or brain (4%).

Neurologic involvement in cases of Wegener granulomatosis primarily involves the peripheral nervous system, usually in the form of multiple peripheral neuropathies (mononeuritis multiplex) (1–3, 13). Cranial neuropathy is the most common CNS manifestation (3). Both the peripheral and cranial neuropathies are thought to be the result of small vessel vasculitis. Although one early article regarding the neurologic complications of any type in patients with Wegener granulomatosis reported a prevalence of 50%, subsequent articles have reported rates between 22% and 33% (2, 3). The lower figures in more recent series are thought to reflect earlier treatment with immunosuppressive therapy. Central neurologic manifestations of Wegener granulomatosis include cranial neuropathy, external ophthalmoplegia, hearing loss, headache (common manifestations), cerebrovascular accidents, cerebritis, Horner syndrome, and meningitis (rare manifestations) (2, 3, 9).

Cranial meningeal involvement with Wegener granulomatosis is rare. This disease can affect both dura and leptomeningeal structures (4–7, 14). Diffuse cranial dural thickening and contrast enhancement has previously been reported in connection with Wegener granulomatosis (5, 7, 9). Results of dural biopsy in previous cases have shown necrotizing granulomata, multinucleated giant cells, and lymphocytic infiltration (5, 7, 9). Meningeal involvement can be seen as located only in the dura or large focal regions of brain parenchyma adjacent to sites of dural thickening. Dural thickening patterns associated with Wegener granulomatosis may be symmetric thickening of the entire dura, focal diffuse, focal nodular, and plaque-like thickening that has mass effect on brain (5, 7, 9). Nusbaum et al (14) presented a case of Wegener

granulomatosis with abnormal pial enhancement and involvement of the perivascular spaces on MR images, pathologically proved to present granulomatous infiltration due to Wegener granulomatosis.

Paraparesis is rare, occurring not at all in the well-known large series presented by Hoffman et al (1) and Drachman (13) and occurring in only three of 324 patients in the series presented by Nishino et al (2). Of these three, pathologic data were available for only one patient, identifying dural vasculitis but no granuloma formation, with spinal cord involvement presumably related to either local compression by inflamed tissues or spread of inflammation to adjacent cord and leptomeninges (9). One other report describes a patient with Wegener granulomatosis and cauda equina syndrome, with normal CSF and without neuroimaging or pathologic details (8). Another report describes a patient with a spinal subarachnoid hemorrhage in the context of a preterminal generalized coagulopathy, but no pathologic data were available (9). The relation of spinal involvement to the disease process in these cases is not clear. Kelly et al (10) illustrated that the underlying pathologic mechanism in Wegener granulomatosis was extramedullary compression due to extradural and subdural granulomatous involvement of spinal meninges rather than vasculitic meningeal inflammation or cord infarction. Spinal manifestations of Wegener granulomatosis in our patient occurred at the cervical and thoracic (C1–C2 and T1–T4, respectively) levels. Both dural masses and plaque-like dural thickening were present, causing spinal cord indentation without prominent cord compression at the cervical and thoracic levels. Other cases of Wegener granulomatosis disease that have been published in the literature do not include detailed MR imaging findings of the disease's spinal dural manifestations (2, 8–10).

Our case details the MR signal intensity features of spinal dural masses associated with Wegener granulomatosis. The signal intensity pattern of the dural lesion was slightly hyperintense on T1-weighted images and prominently hypointense on T2-weighted images, with only minimal enhancement on T1-weighted images after the IV administration of contrast material. The exact reason for this interesting signal intensity pattern of the dural masses remains unclear; however, we suspect that these features arise from paramagnetic components or protein content of the masses. Follow-up MR imaging showed nearly total regression of the dural masses and dural thickening 1 month later, after the administration of immunosuppressive therapy. It is known that dural granulomatous disease associated with Wegener granulomatosis can respond in a dramatic manner to immunosuppressive therapy, as manifested by rapid symptomatic improvement (as seen in our patient) and nearly total regression in dural contrast enhancement (as seen in previously reported cases) (5).

Dural thickening and masses caused by Wegener granulomatosis need to be distinguished from those caused by other diseases. The differential diagnosis of dural lesions includes neurosarcoidosis, primary or secondary dural tumors, and infectious meningitis (5). The dural disease pattern associated with Wegener granulomatosis differs from that typically seen in association with neurosarcoidosis, in which a pial abnormality (with contrast enhancement typically extending along the contour of the brain and within brain sulci) predominates (5). Plaquelike or diffuse type dural enhancement and thickening can also be produced by primary tumors (eg, meningioma and dural lymphoma) and metastatic tumor (5). In most cases, conventionally, the distinction between Wegener granulomatosis and these tumors can be made on the basis of associated clinical or radiologic findings. However, in cases in which the non-CNS features of Wegener granulomatosis are absent or subtle, the distinction between tumor and Wegener granulomatosis can be made only by performing a biopsy. The MR imaging appearance of dural Wegener granulomatosis can also be simulated by infectious meningitis (including tuberculosis), in which only dural enhancement is present (5). It is difficult to establish an exact diagnosis on the basis of one case report, but our patient's MR signal intensity contrast enhancement patterns and very fast regression after treatment could be useful for the differential diagnosis of dural lesions. The lack of a prominent contrast enhancement pattern with dural spinal lesions associated with Wegener granulomatosis may differentiate these le-

sions from other dural lesions, which generally show prominent enhancement on T1-weighted images after the IV administration of contrast material. Such enhancing lesions include those associated with neurosarcoidosis, meningioma, dural lymphoma, and infectious meningitis. In addition, a very low signal intensity pattern on T2-weighted images may help to differentiate dural lesions associated with Wegener granulomatosis from other dural lesions.

Conclusion

Although Wegener granulomatosis very rarely affects the spinal dura, it should still be considered in the differential diagnosis of sub- or epidural masses of the spine or dural thickening. The signal intensity and contrast enhancement patterns of these masses revealed by MR imaging may be helpful in determining whether or not these masses are the result of Wegener granulomatosis.

References

1. Hoffman GS, Kerr GS, Leavitt RY, et al. **Wegener granulomatosis: an analysis of 158 patients.** *Ann Intern Med* 1992;116:488-498
2. Nishino H, Rubino FA, DeRemee RA, Swanson JW, Parisi JE. **Neurological involvement in Wegener's granulomatosis: an analysis of 324 consecutive patients at the Mayo Clinic.** *Ann Neurol* 1993;33:4-9
3. Fauci AS, Haynes BF, Katz P, Wolff SM. **Wegener's granulomatosis: prospective clinical and therapeutic experience with 85 patients for 21 years.** *Ann Intern Med* 1983;98:76-85
4. Katrib A, Portek I, Corbett AJ, Hersch MI, Zagami AS. **Meningeal involvement in Wegener's granulomatosis.** *J Rheumatol* 1998;25:1009-1011
5. Provenzale JM, Allen NB. **Wegener granulomatosis: CT and MR findings.** *AJNR Am J Neuroradiol* 1996;17:785-792
6. Shiotani A, Mukobayashi C, Oohata H, et al. **Wegener's granulomatosis with dural involvement as the initial clinical manifestation.** *Intern Med* 1997;36:514-518
7. Tishler S, Williamson T, Mirra SS, Lichtman JB, Gismondi P, Kibble MB. **Wegener granulomatosis with meningeal involvement.** *AJNR Am J Neuroradiol* 1993;14:1248-1252
8. Martens J. **Spinal cord involvement in Wegener's granulomatosis.** *Clin Rheumatol* 1982;1:221-221
9. Nishino H, Rubino FA, Parisi JE. **The spectrum of neurologic involvement in Wegener's granulomatosis.** *Neurology* 1993;43:1334-1337
10. Kelly PJ, Toker DE, Boyer P, McDonald CT, Niles J. **Granulomatous compressive thoracic myelopathy as the initial manifestation of Wegener's granulomatosis.** *Neurology* 1998;51:1769-1770
11. Cotran RS, Kumar V, Robbins SL. *Pathological basis of disease.* 4th ed. Philadelphia: W.B. Saunders; 1989:553-595
12. No authors listed. **Case records of the Massachusetts General Hospital: weekly clinicopathological exercises: case 9-1999: a 74-year-old woman with hydrocephalus and pleocytosis.** *N Engl J Med* 1999;340:945-953
13. Drachman DD. **Neurological complications of Wegener's granulomatosis.** *Arch Neurol* 1963;8:141-155
14. Nusbaum AO, Morgello S, Atlas SW. **Pial involvement in Wegener's granulomatosis shown on MRI.** *Neuroradiology* 1999;41:847-849