



## Discover Generics

Cost-Effective CT & MRI Contrast Agents



FRESENIUS  
KABI

WATCH VIDEO

# AJNR

## Radiologic and Cytologic Findings in a Case of Thyrolipoma

Gulgan Demirpolat, Bunyamin Guney, Recep Savas, Goksel Tuncay, Hadaver Alper and Rifat Nuri Sener

*AJNR Am J Neuroradiol* 2002, 23 (10) 1640-1641  
<http://www.ajnr.org/content/23/10/1640>

This information is current as  
of June 5, 2025.

## Case Report

# Radiologic and Cytologic Findings in a Case of Thyrolipoma

Gulgan Demirpolat, Bunyamin Guney, Recep Savas, Goksel Tuncay, Hadaver Alper, and Rifat Nuri Sener

**Summary:** Thyrolipomas are rare capsulated mass lesions containing fat and thyroid tissue. We herein report the case of a 60-year-old man who had goitre for 10 years, with rapid enlargement of the gland during the last several months before presentation. Sonography, scintigraphy, CT, MR imaging, and sonography-guided fine needle aspiration were performed. Sonography and scintigraphy revealed an unusual mass of the thyroid. The diagnosis of thyrolipoma was based on CT and MR imaging findings and fine needle aspiration cytology.

Thyrolipomas, also called *adenolipomas*, are rare capsulated mass lesions containing fat and thyroid tissue. They are benign and usually biologically inactive neoplasms of the thyroid gland (1–5). We report a case of thyrolipoma and discuss briefly the differential diagnosis of fat-containing thyroid lesions, with emphasis on imaging findings.

## Case Report

A 60-year-old man was admitted with dyspnea, expectoration, and fatigue. A physical examination revealed signs of chronic obstructive pulmonary disease and diffuse goitre with a soft swelling in the midline of the neck. The patient had goitre for 10 years, and a rapid enlargement of the gland was noted during the last several months before presentation. He had a history of having received antituberculosis treatment five times between 1960 and 1987. While he was hospitalized in another hospital 3 years previously, for chronic obstructive pulmonary disease, he was found to have mild renal insufficiency and gout. At admittance to our hospital, he had a white blood count of  $9.9 \times 10^3/\text{mm}^3$ , a blood creatinine level of 4.12 mg/dL, and a urea level of 149 mg/dL. Thyroid and thyroid-stimulating hormone levels were normal. Sonography of the thyroid gland revealed diffuse enlargement of the gland with retrosternal extension and a few solid and cystic nodules, measuring 1 to 1.5 cm in the left lobe. The soft mass in the midline was confined to the thyroid gland and was almost iso-echoic with no distinguished margins, but it caused more attenuation than the normal thyroid gland. No enlarged lymph nodes were detected. Thyroid scintigraphy revealed a large hypoactive mass in the midline. Unenhanced CT of the thorax and neck revealed a mass with distinct margins and predominantly fat attenuation in the thyroid gland (Fig 1). The hypoattenuated mass contained some high attenuation areas isoattenuated with the

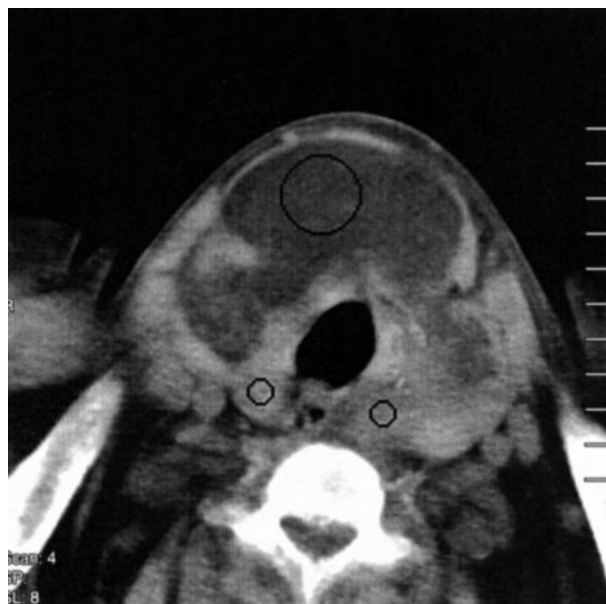

FIG 1. Unenhanced axial view CT scan shows a well-circumscribed, predominantly fatty mass (Hounsfield units  $H. = -60$ ) of the thyroid gland. The mass causes enlargement of the isthmus and extends to both right and left lobes. Small portions of the right and left lobes have a soft tissue attenuation (Hounsfield units  $= +50$ ), consistent with normal thyroid tissue.

normal thyroid gland. CT of the thorax showed left upper lobe atelectasis, fibrosis, and cicatricial emphysema in the left upper lobe, which were considered to be sequelae to previous tuberculous infection. MR images of the neck confirmed the fatty nature of the mass (Fig 2). Fine needle aspiration was performed under ultrasonographic guidance and revealed thyroid epithelial cells and fat cells containing mesenchymal elements, supporting the diagnosis of thyrolipoma. A skin biopsy was negative for amyloid deposition.

## Discussion

Small amounts of adipose tissue are rarely seen in normal thyroid glands adjacent to the capsule, adjacent to surrounding vessels, or in connective tissue septa. They have been described in rare conditions such as adenomas, papillary carcinoma, amyloid goitres, nodular hyperplasia, and Graves' disease (1, 2).

Fine needle aspiration cytology of these conditions may reveal adipocytes and follicular cells. Thyrolipomas differ from diffuse lipomatosis and amyloid goitre with adipose tissue in that they are well circumscribed and capsulated mass lesions (1, 2).

The origin of adipose tissue in the thyroid gland is unclear. Some authors think that adipose tissue is included

Received January 4, 2002; accepted after revision May 6.

From the Departments of Radiology (G.D., B.G., R.S., H.A., R.N.S.) and Chest Disease (G.T.), Ege University Hospital, Bornova, Izmir, Turkey.

Address reprint requests to Professor R. Nuri Sener, Ege University Hospital, Department of Radiology, Bornova, Izmir, 35100, Turkey.

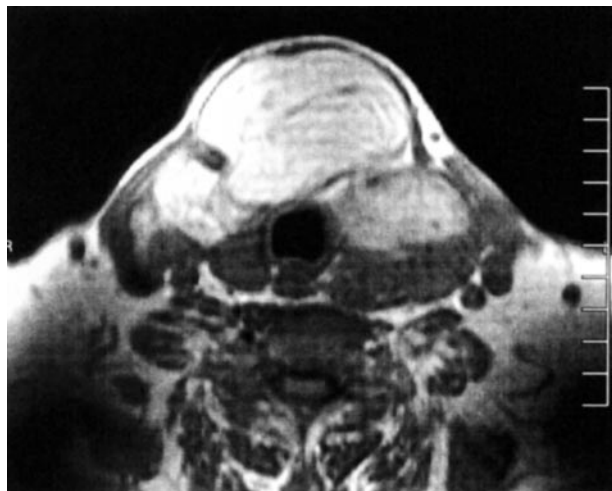


FIG 2. Fast spin-echo T1-weighted MR image (1104/12 [TR/TE]; acquisition, 2; section thickness, 5 mm). The thyrolipoma is isointense with subcutaneous fat.

in the thyroid gland during embryogenesis and that thyrolipoma is a true neoplasm with proliferation of fatty tissue (3). Other authors suggest metaplastic origin from fibroblasts (3). Trites (4), who reported a case of thyrolipoma associated with thymolipoma and a pharyngeal lipoma, noted that the thymus, thyroid, and aryepiglottic folds arise from the primitive foregut and added that the simultaneous appearance of these tumors suggested a disturbance in the development of the primitive foregut. Breek et al (5) reported a case of thyrolipoma and thymolipoma and agreed with the hypothesis presented by Trites.

Our patient had diffuse enlargement of the thyroid gland. His condition was euthyroid, and no enlarged lymph nodes or clinical signs of malignancy were found. Because the patient had a history of tuberculosis, amyloidosis was suspected to be the cause of

renal insufficiency. Diffuse enlargement of the thyroid gland could also be explained with amyloid goitre, but CT disclosed a well-circumscribed fatty mass in the thyroid gland instead of diffuse lipomatosis as seen in association with amyloid goitre. Amyloid goitre is always associated with amyloid deposition elsewhere in the body (2). Skin biopsy of our patient did not disclose amyloid deposition. Fine needle aspiration cytology of the mass confirmed the presence of adipocytes and normal follicular cells.

### Conclusion

Sonography and scintigraphy are widely performed for imaging the thyroid gland and are usually sufficient to make a diagnosis when combined with laboratory findings and fine needle aspiration cytology. Fatty tissue infiltration or fatty masses may be iso-echoic and cannot be differentiated from normal thyroid gland on ultrasonograms. For the current patient, sonography and scintigraphy were not diagnostic, and the diagnosis of thyrolipoma was based on the CT and MR imaging appearances, fine needle aspiration cytology, and exclusion of other disorders.

### References

1. Laforga JB, Vierna J. **Adenoma of thyroid gland containing fat (thyrolipoma): report of a case.** *J Laryngol Otol* 1996;110:1088-1089
2. Hjorth L, Thomsen LB, Nielsen VT. **Adenolipoma of the thyroid gland.** *Histopathology* 1986;10:91-96
3. Rosai J, Carcangiu ML, Delellis RA. **Tumors of the thyroid gland.** In: *Atlas of Tumor Pathology*. Washington: Armed Forces Institute of Pathology; 1992
4. Trites AE. **Thyrolipoma, thymolipoma and pharyngeal lipoma: a syndrome.** *Can Med Assoc J* 1996;95:1254-1259
5. Breek JK, Vallaey JH, Rutsaert RR. **Simultaneous presentation of a thyrolipoma and a thymolipoma in a young man.** *Eur J Surg* 1997;163:941-943