



Discover Generics

Cost-Effective CT & MRI Contrast Agents

 **FRESENIUS
KABI**

[WATCH VIDEO](#)

AJNR

Global Estimation of Myelination in the Developing Brain on the Basis of Magnetization Transfer Imaging: A Preliminary Study

Mark A. van Buchem, Stefan C.A. Steens, Henri A. Vrooman, Aeilko H. Zwinderman, Joseph C. McGowan, Margarethe Rassek and Volker Engelbrecht

This information is current as of June 21, 2025.

AJNR Am J Neuroradiol 2001, 22 (4) 762-766
<http://www.ajnr.org/content/22/4/762>

Global Estimation of Myelination in the Developing Brain on the Basis of Magnetization Transfer Imaging: A Preliminary Study

Mark A. van Buchem, Stefan C.A. Steens, Henri A. Vrooman, Aeilko H. Zwinderman, Joseph C. McGowan, Margarethe Rassek, and Volkher Engelbrecht

BACKGROUND AND PURPOSE: In the developing brain, myelination occurs in an orderly and predetermined sequence. The aim of this study was to determine whether such changes can be tracked using volumetric magnetization transfer imaging.

METHODS: Three-dimensional magnetization transfer imaging was performed in 50 children (age range, 0.6–190 months) with no evidence of developmental delay or structural abnormalities. Volumetric magnetization transfer ratio (MTR) parameters generated of the whole brain were mean MTR and height and location of the MTR histogram peak. Relationships between volumetric MTR parameters and age were assessed using nonlinear regression analysis.

RESULTS: With age, all volumetric MTR parameters changed exponentially in a way that was best expressed by the function $y = a + b \cdot \exp(-x/c)$ ($P < .0001$). The peak height of the MTR histogram was the parameter that changed most predictably and that continued to change for the longest period of time.

CONCLUSION: With this preliminary study, we show that by using volumetric MTR analysis, it is possible to monitor changes in the developing brain, presumably the myelination progress. This method has a potential role for detecting myelination disorders in the pediatric population, for studying the natural history of these diseases, and for monitoring the effects of treatment.

In the developing brain, the creation of myelin (myelination) occurs in an orderly and predetermined sequence, following a topographic variation in the CNS (1). The changes that occur in the developing brain as a result of myelination are detectable by MR imaging. Increasing myelination leads to shortening of T1 and T2 relaxation times, presumably because of decreasing free and total water concentrations and increasing cholesterol and glycolipid concentrations (2, 3). How these factors

influence relaxation times has not been completely determined (1). Nevertheless, on the basis of the changes in T1 and T2 relaxation times, a number of qualitative approaches to the assessment of myelination have been developed (2–8). The global appearance of the brain on T1- and T2-weighted images can be compared with a set of patterns that reflect different stages of the developing brain or appearances of specific parts of the brain can be compared with a list of normal milestones (3). Using these methods, disorders of myelination can be detected when the appearance of the brain deviates from the expected normal appearance for a certain age. Although these methods are currently widely used and have proved to be effective, the qualitative nature of the approach makes it subjective and therefore imprecise. A quantitative approach could circumvent this limitation.

Magnetization transfer (MT) imaging is a technique that is sensitive to the presence of myelin in the brain and that permits the generation of robust quantitative data (9–11). MT imaging is based on the exchange of magnetization in biologic tissues between a pool of protons in water and a pool of protons that is bound to macromolecules. The mag-

This work was presented in part at the 7th Scientific Meeting and Exhibition of the International Society for Magnetic Resonance in Medicine, Philadelphia, 1999.

Address reprint requests to Mark A. van Buchem, MD, PhD, Department of Radiology, C2S, Leiden University Medical Center, Albinusdreef 2, 2333 AA Leiden, The Netherlands.

nitude of the effect depends on the ratio of water and macromolecules and on the surface chemistry and biophysical dynamics of macromolecules and may be quantitated by calculation of the MT ratio (MTR) (10). In the brain, macromolecules that contribute to the MT effect are the cholesterol component of myelin, cerebrosides, and phospholipids (12, 13). MTR measurements can be obtained to determine the local tissue status by assessing MTR values in regions of interest. Another approach is to perform MTR analysis of the whole brain according to a method that was recently introduced (14). This volumetric approach has recently been used in a number of studies to assess the demyelinating lesion load in the brain in patients suffering from multiple sclerosis (15–18). Volumetric MT imaging analysis has been proved to be sensitive, quantitative, and observer independent (14). This study was designed to determine whether changes in the developing brain can be tracked using volumetric MT imaging analysis.

Methods

For 95 consecutive pediatric patients, MT imaging was added to a clinically indicated MR examination of the brain with institutional review board approval. These patients underwent imaging on a 1.5-T unit using the following sequences: axial view double spin-echo sequence (2000/20, 80 [TR/TE]) and coronal and sagittal view spin-echo sequences (600/14). MT imaging was performed running a spin-echo sequence (785/14) twice, first with and then without an off-resonance saturation pulse (7.5-ms gaussian pulse, 1.5-kHz off resonance). A constant gain and image scale was used for obtaining reference images and the images with MT saturation. Section thickness was adapted to the size of the head and varied from 4 to 6 mm for all sequences.

A pediatric neurologist performed a full clinical examination of each patient. Patients who were clinically suspected for developmental delay were psychologically tested by a pediatric psychologist. The tests that were used were the Kaufmann Assessment Battery for Children, the Griffiths Developmental Scale, and the Snijders-Oomen Test. For children who were diagnosed with developmental delay, the tests were repeated after 1 or 2 years. Conventional MR images were evaluated by a radiologist, who assessed the presence of disease and whether the degree of myelination was normal for the patient's age. For the latter, the images were evaluated using the guidelines presented by Barkovich et al (3), van der Knaap and Valk (6), and Grodd (19). The following criteria were used for inclusion of patients in this study: no abnormalities on conventional MR images, normal myelination for age, and either clearly normal results of the initial clinical examination or no disturbances revealed by the neurologic examination and no developmental delay at 1 or 2 years of follow-up. Using these criteria, 45 children were excluded from the study. For the 50 patients who were included, indications for MR examinations varied and included analysis after seizures and suspicion of brain tumor or encephalitis.

The age of the children was corrected for prematurity and ranged from 0.6 to 190 months, with a mean age of 41 months. Twenty-five children were male, and 25 were female. No child was studied more than once. Informed consent for performing the additional MT imaging sequence was obtained from the parents before examination.

Image postprocessing was performed on a Sun Ultrasparc 1 workstation using 3DVIEWNIX software (Medical Image Processing Group, Department of Radiology, Hospital of the Uni-

versity of Pennsylvania, Philadelphia, PA). This image post-processing method has been described in detail (14). Briefly, image postprocessing consisted of the following steps. The first step consisted of segmenting the brain from its surroundings. This was obtained by a semiautomated method based on signal intensity characteristics of brain tissue on MT images, with and without the RF saturation pulse. The only operator interaction during this part of the process consisted of outlining some pixels in selected regions occupied by CSF (frontal horns of the lateral ventricles). Subsequently, the software generated a mask for brain parenchyma that was verified and incidentally manually corrected by the operator. Corrections consisted of straightforward operator decisions, like deselecting extracranial and orbital structures from the mask. During the second step, MTR values were calculated for each voxel of the brain, and during the third step, the data set of MTR values was displayed as an MTR histogram. The second and third steps were fully automated, requiring no operator interference. The amount of MT was quantified by calculation of the MTR, defined as follows:

$$\text{MTR} = [1 - (M_S/M_0)] \times 100\%$$

M_0 and M_S represent the signal intensity of an area with the saturation off and on, respectively. This ratio indicates the percentage loss of signal intensity attributable to MT. Histograms were normalized by dividing by the total number of voxels contained therein. Voxels were included in the histograms if they had MTR values $>5\%$ (voxels with an MTR $<5\%$ were presumed to represent CSF or noise in the absence of signal). The following parameters were computed from this histogram: the peak height of the histogram; the peak location (MTR value corresponding to the peak); the mean MTR value of the voxels with an MTR value $>5\%$ (the voxels representing brain tissue); and the number of voxels with an MTR value $>5\%$ multiplied by the voxel size, representing brain volume. For each parameter, age dependency was assessed using nonlinear regression analysis (20). In addition, alternative models using spline functions were applied. To compare age dependency of the different MR parameters, we calculated the percentage change per month for each MR parameter. In all analyses, a P value of $<.05$ was assumed to represent a significant difference.

Results

With age, all volumetric MR parameters changed in a way that was best expressed by the monoexponential function, $y = a + b \cdot \exp(-x/c)$ ($P < .0001$). This function fitted better than did complete nonparametric (spline) functions. In the monoexponential function, y represents the value of an MR parameter at age x , and a , b , and c are parameters influencing the results. The sum of a and b is the value of an MR parameter at birth, and the value of a represents the value of the MR when the brain is fully mature, because b is always negative and gets smaller with increasing age. The parameter c indicates the slope of the curve, with a low value reflecting a steep slope and a high value reflecting a shallow slope. For individual MR parameters, values for a , b , and c differed (Table). Highest c values were found for brain volume and peak height.

Using this function, the highest R^2 value (reflecting the part of the observed variance that could be expressed by the function) was found for the MTR histogram parameter peak height (Table). The curves of the mean MTR (Fig 1), peak location

Volumetric parameter changes over time

Parameter	a Value	b Value	c Value	R ² Value
Mean MTR	28.36	-34.06	6.63	0.63
Peak height	0.06	0.05	16.38	0.71
Peak location	28.00	-180.62	3.05	0.50
Brain volume	223,199.04	-134,979.20	22.13	0.55

Note.—Volumetric parameter changes over time were expressed by the function $y = a + b \cdot \exp(-x/c)$. In this table the a, b, and c values of the different volumetric parameters and the corresponding R² values are provided.

(Fig 2), and brain volume increased exponentially with age, whereas the curve of peak height showed an exponential decrease with age (Fig 3). As reflected in Figure 4, differences were found between MR parameters in terms of the amount of change over time. Notably, as compared with other MR parameters, peak height showed less dramatic changes shortly after birth, whereas it continued to

change more over time. Peak height values continued to change even beyond the age that our study permitted to observe.

Discussion

The observed increase in the mean MTR of the brain with maturation state (Fig 1) was expected. Recently, Engelbrecht et al (20) reported age-dependent MTR changes in different regions of the pediatric brain. These changes were attributed to increasing myelination and, more specifically, to the concentration of galactocerebrosides. The increase of the MTR histogram peak location over time (Fig 2) could be explained by the same process of increasing myelination. However, the decrease of the MTR histogram peak height (Fig 3) presumably reflects another phenomenon. At birth, the brain is relatively homogeneous in terms of myelination. That is, most of the brain is relatively

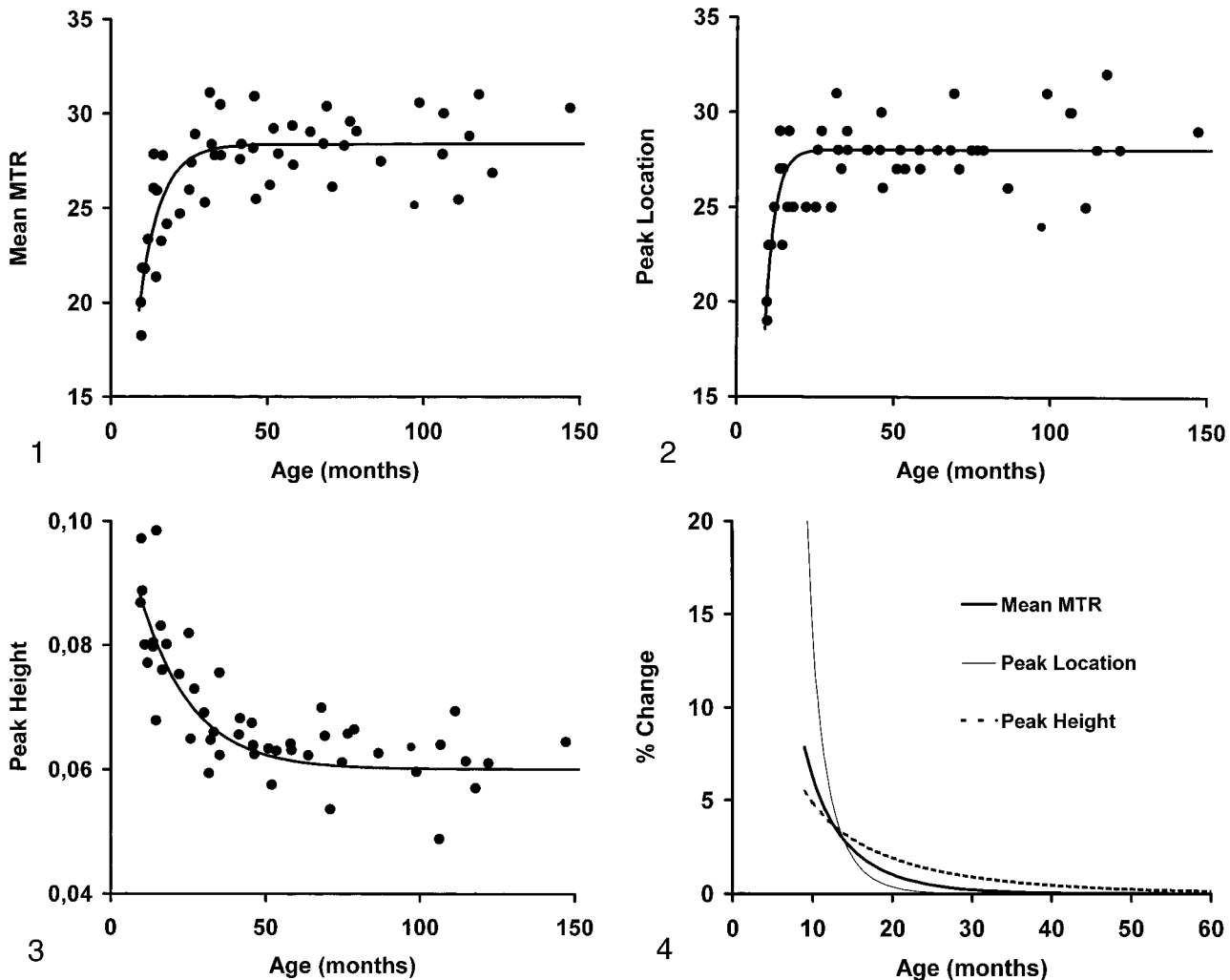


FIG 1. Mean MTR values plotted versus gestational age (in months); R² value, 0.63.

FIG 2. Peak location of MTR histograms plotted versus gestational age (in months); R² value, 0.50.

FIG 3. Peak height of MTR histograms plotted versus gestational age (in months); R² value, 0.71.

FIG 4. Mean changes of different volumetric values versus gestational age (in months).

unmyelinated. The observed high and narrow MTR histogram peak might reflect this situation. During the progress of maturation, myelination occurs at different paces in the different regions of the brain. These different paces not only lead to an increasing regional variation of myelination during the maturation progress but also result in regional variation of myelin concentration in the adult brain. It has been shown that this regional variation in myelination is accompanied by a regional variation in MTR values in the developing brain and in adults (20, 21). Our results suggest that the decrease and widening of the MTR histogram peak height reflect this increasing heterogeneity of the maturing brain.

In this study, we observed the most rapid changes of volumetric MTR parameters during the first 2 years of life. The dynamics of these changes are in agreement with those of MR measurements obtained in other studies and with those of myelination observed in autopsy studies (20, 22, 23). Although all volumetric MR parameters changed most dramatically during the first 2 years of life, interesting differences were observed in the dynamics of the changes between MR parameters. As compared with the mean MTR value of the brain and the closely related MTR histogram peak location, the peak height of the MTR histogram continues to change for a considerably longer period of time (Fig 4). This suggests that the peak height is more sensitive than the other parameters to the slowly progressing myelination that is known to occur in the brain up to the third decade of life (24).

Volumetric MT imaging analysis has several advantages over existing methods to assess myelination in the developing brain. As compared with the qualitative assessments based on conventional MR sequences that are mentioned in the introduction of this article, our method offers a reproducible quantitative approach. Previous work showed that the parameter MTR histogram peak height was reproducible when performed serially in the same participants (25). In addition, intraobserver and interobserver correlations for the image postprocessing steps involved in determination of peak height were both previously determined to be in excess of 99% (14). As compared with methods that aim at the local assessment of myelination in the developing brain, by means of calculation of the mean MTR in regionally placed regions of interest, the volumetric MTR analysis also has advantages (20). In these local analyses, the intraobserver and interobserver variation is expected to be considerable, because the degree of myelination in the brain varies and therefore a different position of a region of interest influences the measured mean MTR. Furthermore, using this method, a more global assessment of myelination requires region of interest analysis in many different areas of the brain, which is time consuming. Assessment of the volumetric MT imaging analysis does not suffer from these

limitations. In addition to being reproducible, it is fast (approximately 10 minutes per patient) and provides a global index that presumably reflects the degree of maturation of the whole brain.

Volumetric MT imaging analysis has the potential to become a clinical tool for monitoring myelination in children. However, further studies are suggested by our results. First, it remains to be shown that abnormal myelination can be discriminated adequately from normal myelination by using this method and that volumetric MT imaging analysis is more sensitive than conventional qualitative methods for that purpose. Second, large data bases of volumetric MT imaging studies of normal children of various ages are required to be able to create myelination curves, which are analogs to the head circumference curves currently used by pediatricians. Third, to be able to use uniform myelination curves, the MTR measurements of different MR units have to be comparable. Presently, MTR values for normal brain tissue vary among different machines (26). This is partly because of parameters that can be specified by the user on clinical MR units, such as the imaging sequence used in conjunction with the MT saturation pulse, and partly because of parameters that often are fixed, such as the characteristics of the MT saturation pulse (26). As long as it is impossible to perform identical MT imaging experiments on MR units of different vendors, the use of uniform myelination curves is still a distant goal.

Conclusion

The results of this preliminary study suggest that volumetric MR imaging analysis is a promising method for assessing the degree of maturation of the developing brain. Because MTR histogram peak height is the parameter that changed most predictably and that continued to change longer than the other volumetric MT imaging parameters, this parameter seems to be particularly well suited for this goal. Potential applications of this method are detection of myelination disorders, studying the natural history of these diseases, and monitoring the effects of treatment.

References

1. Barkovich AJ, Lyon G, Evrard P. **Formation, maturation, and disorders of white matter.** *AJNR Am J Neuroradiol* 1992;13:447-461
2. McArdle CB, Richardson CJ, Nicholas DA, Mirfakhraee M, Hayden CK, Amparo EG. **Developmental features of the neonatal brain: MR imaging: part I. gray-white matter differentiation and myelination.** *Radiology* 1987;162:223-229
3. Barkovich AJ, Kjos BO, Jackson DE Jr, Norman D. **Normal brain maturation of the neonatal and infant brain: MR imaging at 1.5 T.** *Radiology* 1988;166:173-180
4. Dietrich RB, Bradley WG. **Normal and abnormal white matter maturation.** *Semin Ultrasound CT MR* 1988;9:192-200
5. Holland BA, Haas DK, Norman D, Brant-Zawadzki M, Newton TH. **MR of normal brain maturation.** *AJNR Am J Neuroradiol* 1986;7:201-208

6. van der Knaap MS, Valk J. **MR imaging of the various stages of normal myelination during the first year of life.** *Neuroradiology* 1990;31:459-470
7. Johnson MA, Pennock JM, Bydder GM, et al. **Clinical NMR imaging of the brain in children: normal and neurologic disease.** *AJR Am J Roentgenol* 1983;141:1005-1018
8. Staudt M, Schropp C, Staudt F, Obletter N, Bise K, Breit A. **Myelination of the brain in MRI: a staging system.** *Pediatr Radiol* 1993;23:169-176
9. Wolff SD, Balaban RS. **Magnetization transfer contrast (MTC) and tissue water proton relaxation in vivo.** *Magn Reson Med* 1989;10:135-144
10. Wolff SD, Balaban RS. **Magnetization transfer imaging: practical aspects and clinical applications.** *Radiology* 1994;192:593-599
11. Grossman RI, Gomori JM, Ramer KN, Lexa FJ, Schnell MD. **Magnetization transfer: theory and clinical applications in neuroradiology.** *Radiographics* 1994;14:279-290
12. Koenig SH. **Cholesterol of myelin is the determinant of gray-white contrast in MRI of brain.** *Magn Reson Med* 1991;20:285-291
13. Kucharczyk W, Macdonald PM, Stanisz GJ, Henkelman RM. **Relaxivity and magnetization transfer of white matter lipids at MR imaging: importance of cerebroside and pH.** *Radiology* 1994;192:521-529
14. van Buchem MA, Udupa JK, McGowan JC, et al. **Global volumetric estimation of disease burden in multiple sclerosis based on magnetization transfer imaging.** *AJNR Am J Neuroradiol* 1997;18:1287-1290
15. Richert ND, Ostuni JL, Bash CN, Duyn JH, McFarland HF, Frank JA. **Serial whole-brain magnetization transfer imaging in patients with relapsing-remitting multiple sclerosis at baseline and during treatment with interferon beta-1b.** *AJNR Am J Neuroradiol* 1998;19:1705-1713
16. Rovaris M, Filippi M, Falautano M, et al. **Relation between MR abnormalities and patterns of cognitive impairment in multiple sclerosis.** *Neurology* 1998;50:1601-1608
17. van Buchem MA, Grossman RI, Armstrong C, et al. **Correlation of volumetric magnetization transfer imaging with clinical data in MS.** *Neurology* 1998;50:1609-1617
18. van Waesberghe JHTM, van Buchem MA, Filippi M, et al. **MR outcome parameters in multiple sclerosis: comparison of surface-based thresholding and segmentation magnetization transfer ratio histographic analysis in relation to disability (a preliminary note).** *AJNR Am J Neuroradiol* 1998;19:1857-1862
19. Grodd W. **Kernspintomographie neuropaediatrischer Erkrankungen: Normale Reifung des kindlichen Gehirns [in German].** *Klin Neuroradiol* 1993;3:13-27
20. Engelbrecht V, Rassek M, Preiss S, Wald C, Modder U. **Age-dependent changes in magnetization transfer contrast of white matter in the pediatric brain.** *AJNR Am J Neuroradiol* 1998;19:1923-1929
21. Mehta RC, Pike GB, Enzmann DR. **Magnetization transfer MR of the normal adult brain.** *AJNR Am J Neuroradiol* 1995;16:2085-2091
22. Kinney HC, Brody BA, Kloman AS, Gilles FH. **Sequence of central nervous system myelination in human infancy: II. patterns of myelination in autopsied infants.** *J Neuropathol Exp Neurol* 1988;47:217-234
23. Brody BA, Kinney HC, Kloman AS, Gilles FH. **Sequence of central nervous system myelination in human infancy: I. an autopsy study of myelination.** *J Neuropathol Exp Neurol* 1987;46:283-301
24. Yakovlev PI, Lecours AR. **The myelogenetic cycles of regional maturation of the brain.** In: Minkowski A, ed. *Regional Development of the Brain in Early Life.* Oxford: Blackwell;1967:3-70
25. Bakker D, van Buchem MA. **Reproducibility of quantitative volumetric brain analysis based on magnetization transfer.** Proceedings of the 5th Scientific Meeting and Exhibition of the International Society for Magnetic Resonance in Medicine, Vancouver, 1997
26. Finelli DA. **Magnetization transfer in neuroimaging.** *Magn Reson Imaging Clin N Am* 1998;6:31-52