



Discover Generics

Cost-Effective CT & MRI Contrast Agents



WATCH VIDEO

AJNR

Bilateral Type 1 Proatlantal Arteries with Absence of Vertebral Arteries

Richard J. Woodcock, Harry J. Cloft and J. E. Dion

AJNR Am J Neuroradiol 2001, 22 (2) 418-420

<http://www.ajnr.org/content/22/2/418>

This information is current as
of June 8, 2025.

Case Report

Bilateral Type 1 Proatlantal Arteries with Absence of Vertebral Arteries

Richard J. Woodcock, Harry J. Cloft, and J. E. Dion

Summary: The persistent proatlantal artery is a well-described communication between the carotid and vertebrobasilar system. However, persistence of bilateral proatlantal arteries is exceptionally rare. Although usually noted as an incidental finding, the presence of a proatlantal artery, particularly when bilateral, may result in unusual symptoms or may have implications for therapy. We report a case of bilateral proatlantal arteries, describe their embryology, and consider potential clinical implications of this finding.

Communications between the carotid and vertebrobasilar system are well-recognized anomalies. One such communication, the persistent proatlantal artery, was first described at autopsy in the 19th century (1). Since that time, more than 40 cases have been described in the literature. Persistence of multiple primitive arteries is much more rare, with only a single case of bilateral proatlantal arteries described (2). Although these arteries are typically identified serendipitously, they may be of clinical significance in certain patients. We report a case of incidentally identified bilateral proatlantal arteries, describe their embryology, and consider the implications of both unilateral and bilateral persistence of the proatlantal artery.

Case Report

A 61-year-old man presented for evaluation of possible left-sided carotid bifurcation stenosis, based on carotid duplex sonographic findings. The patient had undergone uncomplicated, left carotid endarterectomy 1 year previously and had been evaluated with sonography at a routine follow-up examination.

An aortic arch arteriogram revealed absence of the vertebral arteries bilaterally (Fig 1). Both subclavian and common carotid arteries originated normally. Evaluation of the right side of the neck via common carotid artery injection revealed the origin of a carotid-basilar anastomotic vessel from the internal carotid artery at the level of C2 (Fig 2). The vessel coursed dorsally at the atlantooccipital junction and entered the skull via the foramen magnum. Cerebral imaging with injection of the right common carotid artery showed that this vessel sup-

plied the basilar artery and both posterior cerebral arteries. In the anteroposterior projection, contrast medium refluxed into the distal portion of a smaller, left carotid-basilar anastomosis.

Evaluation of the left side of the neck via common carotid artery injection revealed the origin of a carotid-basilar anastomotic vessel from the internal carotid artery at the level of C2, although this vessel was smaller than that on the right (Fig 3). The vessel again coursed dorsally at the atlantooccipital junction and entered the skull via the foramen magnum. Minimal intracranial vessel opacification was seen because of wash-in from the contralateral carotid-basilar anastomotic vessel. Atherosclerotic stenosis of the distal left common carotid artery and proximal left internal carotid artery were present. No other communications between the anterior and posterior circulation were present, and no aneurysms or other anomalies were seen.

Discussion

Persistence of fetal communications between the carotid and vertebrobasilar systems is not uncommon, with the most frequent being the persistent trigeminal artery (3). More proximal anastomoses via the internal auditory meatus (otic artery) and hypoglossal foramen (hypoglossal artery) are less frequent, as is the persistent proatlantal artery (4). The proatlantal artery represents a very proximal anastomosis between the carotid and vertebrobasilar systems (4). The finding of multiple or bilateral fetal communications is exceedingly rare, with only scattered case reports in the literature (5, 6). To our knowledge, this is only the second report of bilateral persistence of proatlantal arteries.

At the 4- to 5-mm embryonic stage, each individual somite in the embryo receives blood supply from a single branch of the dorsal paired aorta and innervation from a single nerve. The artery between the occipital somites and the cervical somites accompanies the first cervical nerve and provides a communication between the forming carotid and vertebral circulation (7). Padget (7) named this artery the *proatlantal intersegmental artery*, as it was cranial to the first cervical segment. Similarly, other embryonic carotid-basilar connections exist. These are the primitive trigeminal, otic, and hypoglossal arteries. By the 7- to 12-mm embryonic stage, these connections have involuted, with the proatlantal artery being the last to do so. It has been suggested that a portion of the artery actually may persist and contribute to the formation of the normal occipital artery (5, 8). When the proatlantal artery persists in its entirety, the ipsilateral, contralateral, or both vertebral arteries are hypoplastic in

Received March 6, 2000; accepted after revision, May 24.

From Emory University Hospital, Department of Radiology, Division of Neuroradiology, Atlanta, GA.

Address reprint requests to Richard J. Woodcock, Jr., MD, Emory University Hospital, Department of Radiology, Division of Neuroradiology, 1364 Clifton Road, NE, Atlanta, GA 30322.

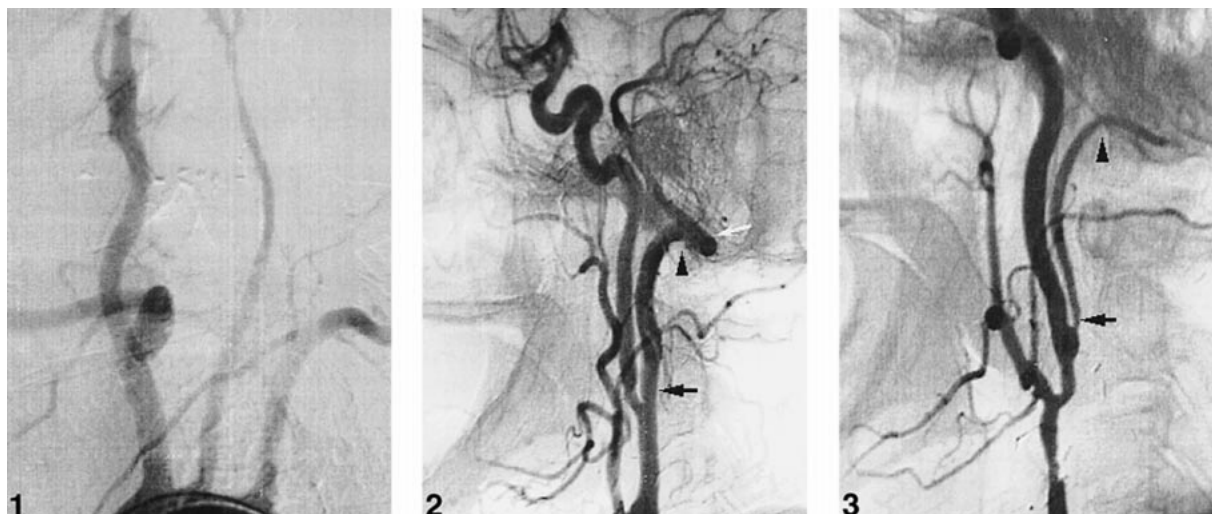


FIG 1. Aortic arch digital subtraction arteriogram, right posterior oblique projection. No vertebral arteries are present. Normal origins of the subclavian and carotid arteries can be seen.

FIG 2. Right common carotid artery digital subtraction arteriogram, lateral projection. Origin of a proatlantal artery from the internal carotid artery (type 1) at C2 can be seen (black arrow). The vessel courses dorsally above C1 (arrowhead) and enters the skull via the foramen magnum (white arrow).

FIG 3. Left common carotid artery digital subtraction arteriogram, lateral projection. Origin of a proatlantal artery from the internal carotid artery (type 1) at C2 can be seen (arrow). The vessel courses dorsally above C1 (arrowhead).

46% of reported cases (9). In our case and in the single other report of bilateral proatlantal arteries, both vertebral arteries were absent (2).

Our case illustrates proatlantal arteries arising from the internal carotid artery at the C2 level, coursing rostral to reach the C1 level, then passing dorsomedial, cephalad to C1, and entering the foramen magnum. Ultimately, they anastomose with one another to form the basilar artery. The origin of the proatlantal artery at C2 or C3 is typical (9). Because of its origin from the extracranial internal carotid artery, this anomaly may be easily confused with a persistent hypoglossal artery (10). The persistent proatlantal artery described herein may be distinguished from the hypoglossal artery by its passage through the foramen magnum rather than the hypoglossal canal, by its dorsal course at the skull base as opposed to the hypoglossal artery's relatively vertical course, and by its level of origin at C2 versus the hypoglossal artery's typical origin at the skull base (10).

Two types of proatlantal arteries distinct from the hypoglossal artery have been described, both arising from the carotid artery, anastomosing with the vertebrobasilar system, and entering the foramen magnum (8). The type 1 proatlantal artery, which is seen bilaterally in our case, was described in previous literature as the proatlantal intersegmental artery (9). It arises from the internal carotid artery anteromedially and courses on the anterior aspect of the vertebral bodies. The artery takes a dorsal course cephalad to the transverse process of C1 and then travels rostral to enter the foramen magnum. The type 2 proatlantal artery was described previously as the first cervical intersegmental artery (9). It arises from the external carotid artery laterally, remains more lateral in position

than the type 1 artery, and joins the course of the horizontal portion of the vertebral artery before entering the foramen magnum (8). Fifty-seven percent of the described proatlantal arteries are of the type 1 variety, 38% are type 2, and 5% arise from the common carotid artery (9).

The proatlantal artery most commonly is an incidental finding; however, it may be of clinical significance in some situations. The artery may account for unusual symptoms, particularly if the anomaly is bilateral. Combined anterior and posterior circulation disease manifestations, as well as isolated posterior circulation symptoms, have been described with carotid bifurcation disease and an ipsilateral proatlantal artery (9, 11). In the setting of carotid bifurcation disease, vertebral steal may occur because of preferential flow from the vertebrobasilar system to the carotid artery via the proatlantal artery (12).

The persistent proatlantal artery could be a source of complication for the surgeon performing endarterectomy (12). With embolization, or carotid sacrifice, the proatlantal artery potentially may allow catastrophic transmittal of particles or emboli. When the proatlantal artery provides the dominant blood supply to the posterior fossa, prolonged temporary occlusion may result in posterior fossa infarct.

References

1. Gottschau M. **Zwei seltene varietäten der stamme des aortenbogens.** *Arch Anat Entwicklgesch* 1885;245-252
2. Lui CC, Liu YH, Wai YY, Tsai CC. **Persistence of both proatlantal arteries with absence of vertebral arteries.** *Neuroradiology* 1987;29:304-305
3. Dilenge A, Heon M. **The internal carotid artery.** In: Newton TPD, ed. *Radiology of the Skull and Brain* St. Louis: Mosby;1974: 1238-1245

4. Rao TS, Sethi PK. **Persistent proatlantal artery with carotid-vertebral anastomosis.** *J Neurosurg* 1975;43:499–501
5. Suzuki S, Nobechi T, Itoh I, Yakura M, Iwashita K. **Persistent proatlantal intersegmental artery and occipital artery originating from internal carotid artery.** *Neuroradiology* 1979;17:105–109
6. Tanaka Y, Hara H, Momose G, Kobayashi S, Koybayashi S, Sugita K. **Proatlantal intersegmental artery and trigeminal artery associated with an aneurysm: case report.** *J Neurosurg* 1983;59:520–523
7. Padget DH. **Designation of the embryonic intersegmental arteries in reference to the vertebral artery and subclavian stem.** *Anat Rec* 1954;119:349–356
8. Lasjaunias P, Theron J, Moret J. **The occipital artery.** *Neuroradiology*. 1978;15:31–37
9. Kolbinger R, Heindel W, Pawlik G, Erasmi-Korber H. **Right proatlantal artery type 1, right internal carotid occlusion, and left internal carotid stenosis: case report and review of the literature.** *J Neurosci* 1993;117:232–238
10. Anderson RA, Sondheimer FK. **Rare carotid-vertebrobasilar anastomoses with notes on the differentiation between proatlantal and hypoglossal arteries.** *Neuroradiology* 1976;11:113–118
11. Bahsi YZ, Uysal H, Peker S, Yurdakul M. **Persistent primitive proatlantal intersegmental artery (proatlantal artery 1) results in “top of the basilar” syndrome.** *Stroke* 1993;24:2114–2117
12. Parkinson D, Reddy V, Ross RT. **Congenital anastomosis between the vertebral artery and internal carotid artery in the neck: case report.** *J Neurosurg* 1979;51:697–699