



Discover Generics

Cost-Effective CT & MRI Contrast Agents



WATCH VIDEO

AJNR

Optic Tract Edema in a Meningioma of the Tuberculum Sellae

Evelyn M. L. Sklar, Norman J. Schatz, Joel S. Glaser, Linda Sternau and Firas Seffo

AJNR Am J Neuroradiol 2000, 21 (9) 1661-1663

<http://www.ajnr.org/content/21/9/1661>

This information is current as of June 10, 2025.

Optic Tract Edema in a Meningioma of the Tuberculum Sellae

Evelyn M. L. Sklar, Norman J. Schatz, Joel S. Glaser, Linda Sternau, and Firas Seffo

Summary: We report a case of tuberculum sellae meningioma with optic tract edema. Contrary to a prior report on this topic, edema along the optic tract is not only seen in craniopharyngiomas but may be seen (although rarely) in other common parasellar tumors, as in our case of a tuberculum sellae meningioma. The pathogenesis of this edema in meningioma is controversial.

Tuberculum sellae meningiomas represent 3% to 10% of all meningiomas (1). They are more common in women between the ages of 30 and 60 years. Visual prognosis is variable, with most series reporting an improvement in visual function in 40% to 60% of cases after surgery (1). Several factors appear to influence the visual prognosis in patients who undergo surgery for removal of tuberculum sellae meningiomas, including duration of visual symptoms, tumor size, location, and preoperative visual function. The role of edema of the visual pathways in the visual prognosis is unknown.

Case Report

A 40-year-old woman inadvertently discovered diminished vision in her right eye during evaluation for laser refractive surgery. Vision was 20/15 in each eye with no afferent pupillary defect. Confrontational visual fields suggested a temporal defect in the right eye. She had noted increased thirst and frequency of urination for some period of time. Two weeks later, a neuroophthalmologic examination revealed a right afferent pupillary defect. The Humphrey automated visual fields showed an inferior temporal hemianopic scotoma in the right eye only.

MR imaging revealed a 1.5-cm-diameter homogeneously enhancing suprasellar lesion with extension anteriorly as a “dural tail” on the planum sphenoidale, displacing the chiasm (Figs 1 and 2). There was increased signal in the optic tracts bilaterally both on fast spin-echo T2-weighted and fluid-attenuated inversion recovery (FLAIR) images (Fig 3).

Extensive thickening of the arachnoid was discovered during surgery. The tumor spread forward along the olfactory nerves,

encompassed the right optic nerve adjacent to the optic chiasm, infiltrated the surface of the brain, and was sheathed posteriorly along the chiasm. Complete removal was not attempted. The patient underwent postoperative radiation therapy.

Discussion

Meningioma is a benign tumor arising in the cranial cavity or in the spine. Grossly, meningioma is a well-circumscribed, firm, tan or grayish lesion arising from the meninges. Microscopically, a benign meningioma usually has a bland whorled appearance with little anaplasia or mitotic activity. Malignant varieties may be identified on the basis of clinical behavior (rapid growth, recurrence, or invasiveness), microscopic features of malignancy (cellular or nuclear anaplasia, mitotic figures), or certain histologic variants.

On MR images, meningiomas tend to be isointense with gray matter, increasing in visibility with contrast enhancement. In our patient, contrast enhancement revealed a homogeneously enhancing mass, although inhomogeneity may have been due to calcification, cystic areas, blood vessels, or histologic variables within the tumor. Enhancement and thickening of the dura adjacent to the neoplasm, the dural tail, may have been due to tumor infiltration or to reactive proliferation of loose connective tissue in the dura (2, 3).

Edema in association with meningioma is quite variable. Some very large meningiomas occur without any edema, whereas even small tumors may be accompanied by pronounced edema. Brain edema is apparently a reaction of the brain tissue to the presence of the neoplasm, even though the tumor is extracerebral; it is not related to the histologic characteristics of the neoplasm (4). Invasion of the brain with disruption of the blood-brain barrier is an unproved hypothesis.

The source of this peritumoral edema has long been a subject of discussion. Domingo et al (5) used dynamic perfusion scanning and proton spectroscopy to study perfusion and metabolism in the peritumoral edema surrounding eight meningiomas preoperatively. These investigators found extremely limited passage of contrast material and low cerebral blood volume in the 2-cm peritumoral region, as well as elevated lactate, suggesting that oligemia and altered metabolism may be part of the pathophysiology in peritumoral edema.

Received February 3, 2000; accepted after revision March 14.

From the Departments of Radiology (E.M.L.S.), Neurology (N.J.S.), and Ophthalmology (Bascom Palmer Eye Institute) (J.S.G.), University of Miami School of Medicine; the Mount Sinai Medical Center, Miami, FL (L.S.); and the Department of Ophthalmology, University of Syria (F.S.).

Address reprint requests to Evelyn M. L. Sklar, MD, Department of Radiology (R-308), University of Miami School of Medicine, 1115 NW 14th St., Miami, FL 33136.

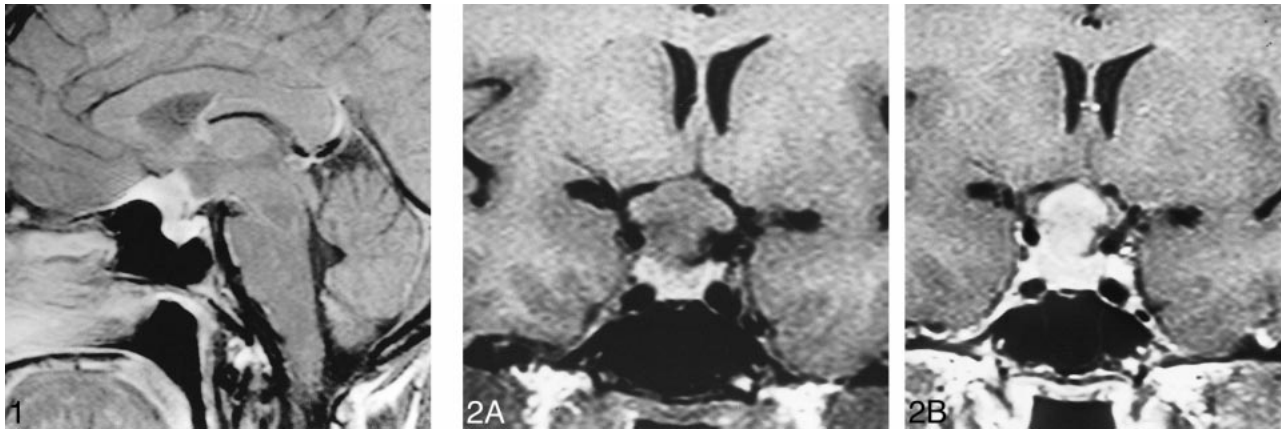


FIG 1. Sagittal contrast-enhanced T1-weighted image (649/20/1) shows a homogeneously enhancing suprasellar lesion with extension anteriorly as a dural tail on the planum sphenoidale.

FIG 2. A and B, Coronal T1-weighted images (656/16/2) before (A) and after (B) administration of contrast material show the suprasellar lesion extending superiorly and displacing the chiasm.

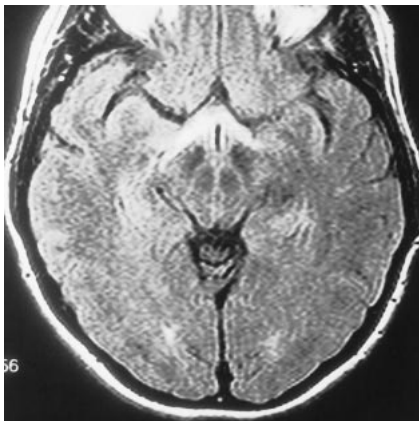


FIG 3. Increased signal in the optic tracts bilaterally is noted on this axial FLAIR image (6000/128/1, TI = 2000).

Vascular endothelial growth factor (VEGF) and vascular permeability factor (VPF) may also play a role in peritumoral edema (6, 7). It has been shown that activation of receptors for VEGF/VPF increases permeability of endothelial cells. Meningiomas with a large amount of peritumoral edema have elevated expression of VEGF/VPF. Other researchers have found that platelet activating factor (PAF), which may arise from infiltrating leukocytes, is important to the development of peritumoral edema in patients with meningioma (8). A significant positive correlation was found between peritumoral edema and PAF concentration. It has also been hypothesized that prostaglandin may play a role in the formation of edema (9). Levels of 6-ketoprostaglandin $F_{1\alpha}$, the stable metabolite of prostacyclin, were found to correlate well with the extent of edema.

The role of macrophages and leukotrienes in association with peritumoral edema has also been described (10). Correlation between macrophage infiltration and peritumoral edema was good: in many cases of peritumoral edema, leukotrienes were de-

tected, whereas in most cases without peritumoral edema, leukotrienes were not detected.

In a recent article, Nagahata et al (11) reported that five of eight patients with craniopharyngioma had optic tract edema, whereas 15 patients with large pituitary adenomas compressing the optic chiasm and six patients with tuberculum sellae meningiomas did not have such edema. The authors concluded that edema caused by craniopharyngioma tends to spread along the optic tracts and that this may be a useful MR finding in distinguishing craniopharyngioma from other common parasellar tumors. However, optic tract edema may be seen in tuberculum sellae meningioma (as in the present case) in pituitary metastases, and it has recently been reported in a case of melanoma (12).

Conclusion

Optic tract edema, although rare, may be seen in conjunction with suprasellar meningiomas. The pathogenesis of this edema has been a source of discussion, and many hypotheses have been suggested. The role of edema in the visual prognosis is unknown. We think that our case shows that, although rare, optic tract edema may be found in association with suprasellar meningiomas, contrary to prior reports, and that meningioma cannot be excluded on the basis of the presence of edema.

References

1. Miller NR. **Walsh and Hoyt's Clinical Neuro-Ophthalmology.** Baltimore: Williams & Wilkins;1991
2. Goldsher D, Litt AW, Pinto RS, et al. **Dural "tail" associated with meningiomas on Gd-DTPA-enhanced MR images: characteristics, differential diagnostic value, and possible implications of treatment.** *Radiology* 1990;176:447-450
3. Tobumaru A, O'uchi T, Eguchi T, et al. **Prominent meningeal enhancement adjacent to meningioma on Gd-DTPA-enhanced MR images: histopathologic correlation.** *Radiology* 1990;175:431-433

4. Chen TC, Zee CS, Miller CA, et al. **Magnetic resonance imaging and pathological correlates of meningiomas.** *Neurosurgery* 1992;31:1015-1021
5. Domingo Z, Rowe G, Blamire AM, Cadoux-Hudson TA. **Role of ischemia in the genesis of oedema surrounding meningiomas assessed using magnetic resonance imaging and spectroscopy.** *Br J Neurosurg* 1998;12:414-418
6. Provias J, Claffey K, del Anguila L, Lau N, Feldkamp M, Guha A. **Meningiomas: role of vascular endothelial growth factor/vascular permeability factor in angiogenesis and peritumoral edema.** *Neurosurgery* 1997;40:1016-1026
7. Kalkanis SN, Carroll RS, Zhang J, Zamani AA, Black PM. **Correlation of vascular endothelial growth factor messenger RNA expression with peritumoral vasogenic cerebral edema in meningiomas.** *J Neurosurg* 1996;85:1095-1101
8. Hirashima Y, Hayashi N, Fukuda O, Ito H, Endo S, Takaku A. **Platelet-activating factor and edema surrounding meningiomas.** *J Neurosurg* 1998;88:304-307
9. Costantini S, Tamir J, Gamori MJ, Shohami E. **Tumor prostaglandin levels correlate with edema around supratentorial meningiomas.** *Neurosurgery* 1993;33:204-211
10. Shinonaga M, Chang CC, Kuwabara T. **Relation between macrophage infiltrates and peritumoral edema.** *Adv Neurol* 1990;52:475-481
11. Nagahata M, Hosoya T, Kayana T, Yamaguchi K. **Edema along the optic tract: a useful finding for the diagnosis of cranio-pharyngiomas.** *AJNR Am J Neuroradiol* 1998;19:1753-1757
12. Bhatti MT, Holder Ca, Newman NJ, Hudgins PA. **MR characteristics of muslin-induced optic neuropathy: report of two cases and review of the literature.** *AJNR Am J Neuroradiol* 2000;21:346-352