



Discover Generics

Cost-Effective CT & MRI Contrast Agents

 FRESENIUS
KABI

[WATCH VIDEO](#)

AJNR

Correlation of *Myo*-inositol Levels and Grading of Cerebral Astrocytomas

Mauricio Castillo, J. Keith Smith and Lester Kwock

AJNR Am J Neuroradiol 2000, 21 (9) 1645-1649

<http://www.ajnr.org/content/21/9/1645>

This information is current as
of June 5, 2025.

Correlation of *Myo*-inositol Levels and Grading of Cerebral Astrocytomas

Mauricio Castillo, J. Keith Smith, and Lester Kwock

BACKGROUND AND PURPOSE: In a limited number of patients, the level of *myo*-inositol (MI), as seen by proton magnetic resonance spectroscopy (HMRS), has been shown to differ for gliomas of different histologic grades. We sought to determine if MI levels correlate with cerebral astrocytoma grade.

METHODS: Five control subjects, 14 patients with low-grade astrocytoma, 10 patients with anaplastic astrocytoma, and 10 patients with glioblastoma multiforme (GBM) underwent single-volume HMRS with an echo time of 20 ms. Twenty-five patients had received surgery, chemotherapy, and/or radiation therapy previously. Using the curve-fitting program supplied by the manufacturer, peak areas for *n*-acetyl aspartate (NAA), choline (Cho), and MI were normalized with respect to the peak area of creatine (Cr). Ratios for MI/Cr, Cho/Cr, and NAA/Cr were obtained for each lesion and retrospectively compared with the histologic grade of the lesion.

RESULTS: Levels of MI/Cr were higher (0.82 ± 0.25) in patients with low-grade astrocytoma, intermediate (0.49 ± 0.07) in control subjects, and lower in patients with anaplastic astrocytoma (0.33 ± 0.16) and GBM (0.15 ± 0.12).

CONCLUSION: Our study shows a trend toward lower MI levels in the presence of anaplastic astrocytomas and GBMs compared with those of low-grade astrocytomas. MI levels may have implications in the grading of cerebral astrocytomas.

Myo-inositol (MI), a molecule that is located within astrocytes, is presumed to act as an osmolyte, and its concentration is altered in many brain disorders (1). MI is also involved in the activation of protein C kinase. Protein C kinase leads to production of proteolytic enzymes, which are found more often in malignant and aggressive primary cerebral tumors. Thus, the levels of MI, as seen by proton magnetic resonance spectroscopy (HMRS), may be helpful for predicting the histologic grade of brain tumors (2–4). It is known that high levels of choline suggest increased cellularity or cell turnover (5). Although most highly malignant tumors have increased levels of choline (Cho), these may also be seen in highly cellular but histologically benign tumors. Malignant tumors also demonstrate the presence of lipids and lactate, but these metabolites are also present in tumors previously treated, regardless of their histologic grade (5).

We sought to determine if MI levels correlate with the histologic grade of cerebral astrocytic tumors.

Methods

Using a 1.5-T MR imaging unit, we performed HMRS in 39 individuals. All HMRS studies were obtained using a single-voxel technique, and in patients with tumors, studies centered on the region previously noted to correspond to maximum contrast enhancement, but during a noncontrast study obtained 24 hours after the initial study was performed. If contrast enhancement was subtle or not present, the area of maximal T2 abnormality and mass effect was sampled. The voxel size varied from 3–27 cm³. Localization was accomplished using the stimulated-echo acquisition mode technique after water suppression. All studies were performed with 20/1500 (TR/TE) and 128–256 signal averages. After baseline correction, *N*-acetyl aspartate (NAA) was assigned at 2.0 ppm, Cho at 3.2 ppm, creatine (Cr) at 3.03 ppm, and MI at 3.56 ppm. Although many lesions showed a peak centered at 1.4 ppm that corresponded to lipid/lactate, we did not use it for the evaluation of tumors in this study because the significance of lipids/lactate in previously treated tumors is questionable (5). Using the curve-fitting software provided by the manufacturer, we obtained areas for MI, NAA, Cho, and Cr. The peak areas of MI, NAA, and Cho were normalized with respect to Cr. Ratios of MI/Cr, Cho/Cr, and NAA/Cr were calculated for the three groups of patients and compared. All ratios were compared with the histologic grade of the lesions.

Results

HMRS was obtained in five healthy control subjects (four male subjects, one female subject; age range, 21–55 years), 14 patients with surgically proven low-grade astrocytomas (Grades 1 and 2;

Received December 21, 1999; accepted after revision April 10, 2000.

From the Department of Radiology, University of North Carolina School of Medicine, Chapel Hill.

Address reprint requests to M. Castillo, CB # 7510, UNC-CH, Chapel Hill, NC 27599-7510.

© American Society of Neuroradiology

10 male patients, four female patients; age range, 2–60 years), 10 patients with surgically proven anaplastic astrocytoma (seven male patients, three female patients; age range, 40–65 years), and 10 patients with proven glioblastoma multiforme (GBM) (eight male patients, two female patients; age range, 35–75 years). Twenty-five patients had received some type of therapy (surgery, radiation, chemotherapy, and/or implantable chemotherapy wafers) 1–3 years before this study.

The levels of MI/Cr were higher (0.82 ± 0.25) in patients with low-grade astrocytoma, intermediate (0.49 ± 0.07) in control subjects, and lower in patients with anaplastic astrocytoma (0.33 ± 0.16) and GBM (0.15 ± 0.12) (Figs 1–4). Among patients with GBM, HMRS showed the lowest levels of MI/Cr and the highest levels of Cho/Cr (Table). NAA/Cr appeared to be higher in patients with anaplastic astrocytomas and GBMs than in patients with low-grade tumor and in control subjects. This finding can be attributed to the fact that most high-grade tumors had been treated and that the peak of NAA, despite being shorter, became wider, resulting in larger peak area.

Discussion

MI is a sugarlike molecule that is mostly located within astrocytes (1). It functions as an osmolyte, and is involved in some hormone-sensitive neuroreception activities as well as protein kinase C activation (1). By HMRS, MI may be identified when acquiring studies using short TEs. MI is usually assigned at 3.56 ppm (6). The utility of identifying MI is not yet well established. It is normally elevated in the newborn brain, but its concentration rapidly decreases thereafter (1). It may also be elevated in Alzheimer's disease, renal failure, diabetes mellitus, recovering hypoxia, hyperosmolar states, progressive multifocal leukoencephalopathy, and in some patients with Canavan disease (1, 7, 8). In most of these diseases, elevation of MI probably reflects its function as an osmolyte or astrocytic marker rather than as a neuronal messenger. MI has been found to be decreased in chronic hepatic and hypoxic encephalopathies, stroke, tumor, toxoplasmosis, cryptococcosis, lymphoma, and some low-grade malignancies (1). Other studies have, however, reported a relative elevation of MI in low-grade astrocytomas when compared with high-grade astrocytomas (3).

Some mitogens, such as platelet-derived growth factor, may directly influence the metabolism of phosphatidylinositol (PI) (9, 10). Cleavage of PI is increased in the presence of some mitogens. MI contributes to formation of PI, and a phosphorylated form of PI is broken down to diacylglycerol and inositol 1,4,5, triphosphate, in response to hormones. The diacylglycerol resulting from the breakdown of PI activates protein kinase C. Protein kinase C may in turn activate proteolytic enzymes such as matrix metalloproteases (MP) (11). Thus,

upregulation of PI increases the concentration of MP. It has been shown that, in cerebral gliomas, invasion is (at least partially) mediated by a specific type of MP (matrix metalloprotease-2 [MP-2]). MP-2 is not present in normal astrocytes or oligodendrocytes. In vitro treatment of specific glioma cell lines with a metalloprotease inhibitor resulted in over 90% reduction of invasion (11). Additionally, treatment of these same cell lines with a specific inhibitor (calphostin C) of protein kinase C also resulted in decreased invasiveness and a lower concentrations of MP-2 (11). Thus, the local aggression of certain gliomas may be modulated partly by the proteolytic activity of metalloproteases. Local aggression is much higher in anaplastic astrocytoma and glioblastoma multiforme than in other forms of astrocytoma.

For our study, we obtained HMRS in control subjects and patients with low-grade astrocytomas, anaplastic astrocytomas, and GBM. We measured MI/Cr, as creatine remains stable under most conditions. We found that MI/Cr was higher in patients with low-grade tumors, followed by control subjects, and that it was lower in patients with anaplastic tumors and GBMs (Figs 1–4). The fact that MI/Cr was lowest in the most aggressive and malignant tumors is not surprising and probably reflects a decrease in the concentration of pooled MI. The portion of this MI that is visible by HMRS is being converted into the PIs, which are not visible on MR images. The presence of the highest MI/Cr being found in low-grade tumors probably implies that the metabolism of MI is not being upregulated (thus, production of proteolytic enzymes and aggression are decreased in low-grade tumors). We believe that the lack of activation of the PI pathway leads to an increased MI pool, which is visible by use of HMRS. The fact that control subjects showed an intermediate level of MI implies that the pool of this metabolite, which is visible by use of HMRS, is being maintained in a balanced form. We also studied the Cho/Cr ratio with respect to the tumor grade and found that the highest ratios were present in GBMs, followed by anaplastic astrocytomas and low-grade tumors. This fact is well known and has been reported elsewhere (5). There was an inverse relationship between Cho/Cr and MI/Cr; that is, with progressive elevation of Cho/Cr, the MI/Cr decreased. NAA/Cr had an inverse relation to MI/Cr; that is, tumors with higher MI/Cr had lowest NAA/Cr, and tumors with lower MI/Cr had higher NAA/Cr. This is opposite to what is more commonly reported; that is, higher-grade tumors have the lowest NAA/Cr. Because most of the high-grade tumors studied herein were previously treated, the NAA peak becomes broad, owing to the presence of other metabolites such as amino acid residues and *N*-acetyl groups in glycoproteins/glycolipids. This broadening of the peak results in an increased peak area despite the fact that, upon visual inspection, the NAA peak height may be lower. Because of this, we believe that the level of

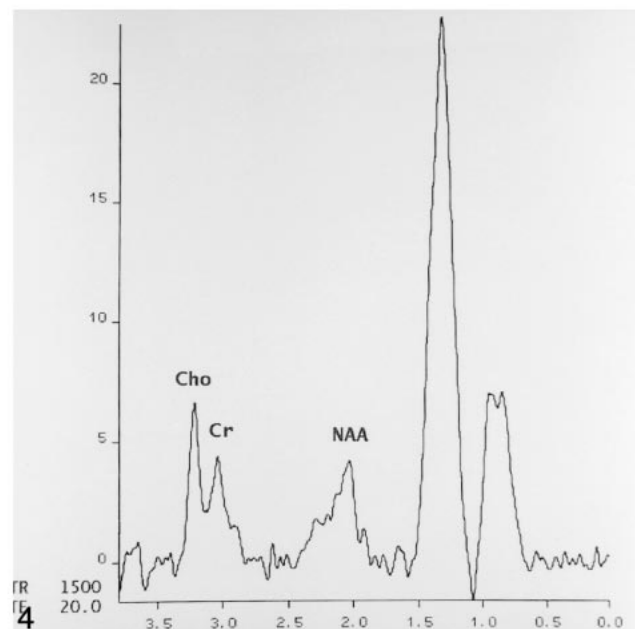
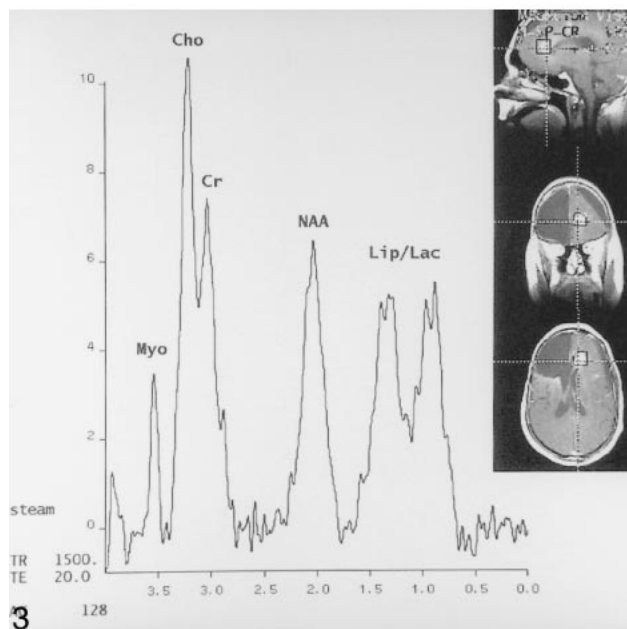
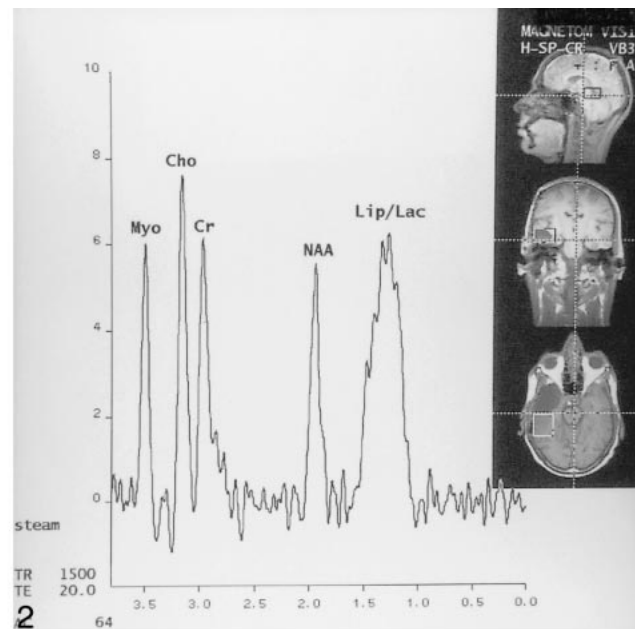
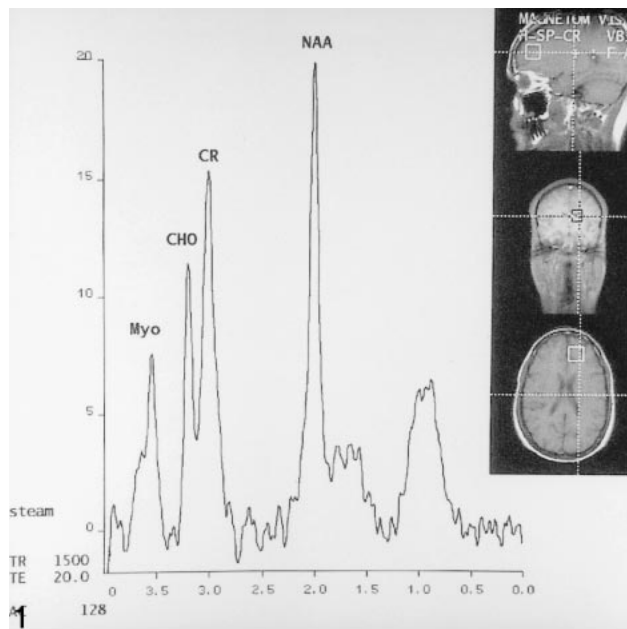


FIG 1. HMRS image (20 [TE], $2 \times 2 \times 2$ -cm voxel) obtained from healthy control subject shows the following normal metabolites: MI (Myo on image), Cho, Cr, and NAA. The small peak at 1.3–1.5 is probably due to lipid contamination (from subcutaneous tissues), which is expected when using this technique.

FIG 2. HMRS image (20 [TE], $3 \times 3 \times 3$ -cm voxel) obtained from patient with histologically confirmed, recurrent, low-grade astrocytoma at posterior margin of prior resection shows high level of MI, mild elevation of Cho, mild decreased NAA, and elevation of lipids and lactate (Lip/Lac) as a sequela of therapy.

FIG 3. HMRS image (20 [TE], $1.5 \times 1.5 \times 1.5$ -cm voxel) obtained from a patient with histologically confirmed, recurrent anaplastic astrocytoma at medial aspect of prior resection shows moderate levels of MI, elevated Cho, depressed NAA, and Lip/Lac, probably as a sequela of therapy.

FIG 4. HMRS image (20 [TE], $2 \times 2 \times 2$ -cm voxel) obtained from a patient with GBM (histologically confirmed but not treated at time of this study) shows no MI, elevated Cho, depressed NAA, and very high levels of Lip/Lac, probably related to tumor necrosis.

NAA in previously treated tumors is of limited utility. A way to avoid this situation is to narrow the line width of NAA and the search range of NAA in the curve-fitting peak program.

We believe that the fact that we studied only five control subjects does not alter our results, demon-

strating differences in the level of MI/Cr between low- and higher-grade astrocytomas. A potential weakness of our investigation is the fact that we did not attempt to evaluate prospectively the ability of MI level to predict the histologic grade of a tumor. Most of our patients had been treated and the

Levels of metabolites in controls and patients with low-grade astrocytoma, anaplastic astrocytoma, and glioblastoma multiforme.

| Lesion/Metabolite (means and standard deviation) | Controls | Low-grade Astrocytoma | Anaplastic Astrocytoma | GBM |
|--|---------------|-----------------------|------------------------|---------------|
| MI/Cr | 0.49 +/- 0.07 | 0.82 +/- 0.25 | 0.33 +/- 0.16 | 0.15 +/- 0.12 |
| Cho/Cr | 0.62 +/- 0.10 | 1.02 +/- 0.25 | 1.48 +/- 0.91 | 2.08 +/- 2.31 |
| NAA/Cr | 1.26 +/- 0.40 | 1.23 +/- 0.57 | 1.48 +/- 1.09 | 3.24 +/- 2.75 |

histologic grading of their lesions was known to all of the investigators. We believe, however, that our results offer baseline data that may be used to assess the significance of MI in a prospective study. Lactate or lipids may suggest a high-grade malignancy, but in our study, the presence of these metabolites was not taken into account because 25 of 34 patients had received some type of prior treatment. It is well known that, in previously treated tumors, the presence of lactate and lipids may represent a sequela of therapy and may not reflect the histologic grade of the tumor. Additionally, we did not seek to establish the effect of therapy on the levels of MI, because in our patients, most of those who had been previously treated harbored high-grade tumors. Lastly, because only a single-voxel technique was used, the possibility of sampling error in tumors of heterogeneous appearance cannot be excluded.

In a series of 10 pediatric patients with brain tumors, the MI/Cr was also found to be higher when compared with control subjects (4). Eight patients harbored low-grade astrocytomas, whereas two had higher-grade malignancies (pineoblastoma and diffuse pontine glioma). They interpreted the elevation of MI to be due to destruction of cells or rapid cellular proliferation. Processes in which cellular destruction is known to occur in large amounts, such as infarctions and radiation-induced damage, are characterized by low MI. In order for MI to be released from the cell, destruction of the membrane needs to occur. Their conclusion that "high levels of MI are found brain tumors" reflects the fact that they studied mostly low-grade tumors and is in accordance with our findings. Cheng et al (3) reported that two low-grade astrocytomas and one anaplastic astrocytoma showed lower inositol levels compared with that found in eight GBMs. The fact that they combined the low-grade and anaplastic tumors into one category (probably because of the small number of tumors studied) makes comparison with our data not possible. From a clinical standpoint, it is not helpful to combine these types of tumors owing to their differences in treatment and prognosis. In addition, their data were obtained from tissue extracts, allowing for MR spectroscopic identification of total pools of metabolites, including MI. The high level of MI that these authors found in extracts of high-grade gliomas reflects total pools, contrary to our study in which in vivo tumor sampling provided information regarding only the MR-visible pools of MI. In a different study, factor analysis and neural net-

works based on HMRS findings were used to investigate and classify brain tumors obtained from chemically extracted biopsy tissue (2). Only inositol showed a significant correlation with the grade of gliomas. A trend toward lower concentrations of inositol for higher tumor grades was found, and this observation concurs with ours.

Although glycine also resonates at 3.6 ppm, it is unlikely to contribute in a significant manner to the overall level of MI seen in our cases. It has been established that in the normal brain, the peak centered at 3.56 ppm corresponds mostly to MI, and the underlying glycine probably contributes less than 10% to the area of that peak. Glycine is a specific amino acid and is elevated in hyperglycinemia (which none of our patients had) (1). Glycine has a long TR and thus remains visible at long TEs, whereas the signal from MI decays and is not seen in that type of study. Although in the present study we have not analyzed the results of MRS obtained with long TEs, this type of study is obtained as part of a routine imaging protocol. We did not observe glycine in any of our patients. Thus, we believe that glycine did not contribute significantly to the MI peak found in our patients.

Conclusion

We found that a trend toward lower MI/Cr in higher-grade astrocytomas (anaplastic and GBM) and higher MI/Cr in low-grade astrocytomas compared with healthy control subjects. A higher-level MI/Cr was related to a lower-level Cho/Cr; that is, the highest Cho/Cr was seen in anaplastic tumors and GBMs, whereas the lowest was seen in low-grade astrocytomas. We believe that the level of MI may have important implications in the presurgical grading of brain tumors derived by HMRS.

References

1. Danielsen ER, Ross B. *Magnetic Resonance Spectroscopy Diagnosis of Neurological Diseases*. New York: Marcel Dekker; 1999:30-34
2. Maxwell RJ, Martinez-Perez I, Cerdan S, Cabanas ME, Arus C, Moreno A, et al. Pattern recognition analysis of H1 NMR spectra from perchloric acid extracts of human brain tumor biopsies. *Magn Reson Med* 1998;39:869-877
3. Cheng LL, Chang IW, Louis DN, Gonzalez RG. Correlation of high-resolution magic angle spinning proton magnetic resonance spectroscopy with histopathology of intact human brain tumor specimens. *J Cancer Res* 1998;58:1825-1832
4. Norfray JF, Tomita T, Byrd SE, Ross BD, Berger PA, Miller RS. Clinical impact of MR spectroscopy when MR imaging is indeterminate for pediatric brain tumors. *AJR Am J Roentgenol* 1999;173:119-125

5. Castillo M, Kwok L. **Proton MR spectroscopy of common brain tumors.** *Neuroimag Clin North Am* 1998;4:733-752
6. Ceodan S, Parrilla R, Santoro J, Rico M. **H-1 NMR detection of cerebral/myo-inositol.** *FEBS Lett* 1985;187:167-172
7. Miller BL, Moats RA, Shonk T, et al. **Alzheimer disease: depiction of increased cerebral myo-inositol with proton MR spectroscopy.** *Radiology* 1993;187:433-437
8. Wang Z, Zimmerman RA, Sauter R. **Proton MR spectroscopy of the brain: clinical useful information obtained in assessing CNS disease in children.** *AJR Am J Roentgenol* 1996;167:191-199
9. Toker A, Cantley JC. **Signalling through the lipid products of phosphoinositide-3-OH kinase.** *Nature* 1997;387:673-676
10. Franke TF, Kaplan DR, Cantley LC, Toker A. **Direct regulation of the AKT protooncogene product by phosphatidylinositol 3,4 bisphosphate.** *Science* 1997;275:665-668
11. Uhm JH, Dooley NP, Villemure JG, Yong VW. **Glioma invasion in vitro: regulation by matrix metalloprotease-2 and protein kinase C.** *Clin Exp Metastasis* 1996;14:421-433