



Ganglioglioma of the Optic Chiasm: Case Report and Review of the Literature

Shanop Shuangshoti, Eberhard Kirsch, Paul Bannan and Victoria A. Fabian

AJNR Am J Neuroradiol 2000, 21 (8) 1486-1489

<http://www.ajnr.org/content/21/8/1486>

This information is current as of August 1, 2025.

Case Report

Ganglioglioma of the Optic Chiasm: Case Report and Review of the Literature

Shanop Shuangshoti, Eberhard Kirsch, Paul Bannan, and Victoria A. Fabian

Summary: We report a case of a hypothalamic chiasmatic ganglioglioma in a 21-year-old woman who presented with hyperprolactinemia and developed visual field defects. This circumscribed cystic lesion with an enhancing mural nodule was radiologically indistinguishable from a pilocytic astrocytoma. Although rare, gangliogliomas should be included in the differential diagnosis of lesions occurring in this area of the brain.

Gangliogliomas, although relatively rare, are the most frequently occurring mixed glioneuronal tumors of the CNS (1). Their incidence ranges from 0.4% to 1.3% of all brain tumors, but they are more common in the pediatric group, with an incidence of 7.6% (2, 3). Patients usually present with seizures (2). The temporal lobes are the most common site, but gangliogliomas can occur anywhere in the central neuraxis, including the brain stem and spinal cord (1). We report a case of a ganglioglioma arising in the hypothalamic chiasmatic region and its MR imaging features. This case emphasizes that gangliogliomas can occur in this location.

Case Report

A 21-year-old woman presented with mild galactorrhea and emotional lability. She also complained of brief sharp headaches that had been occurring several times a day for 6 months. Investigations showed an elevated blood prolactin level of 1400 mIU/L, and CT of the head was interpreted as showing a 1-cm-diameter pituitary tumor. Visual acuity and visual fields were normal. Bromocriptine treatment was started but was discontinued after 2 weeks because of complications.

MR imaging was performed 1 year later to evaluate the lesion after low-dose bromocriptine had been resumed for 9 months. The MR images revealed that there was a solid tumor with a cystic component involving the hypothalamus and the optic chiasm. The lesion measured $20 \times 20 \times 18$ mm and was located above the normal, non-infiltrated pituitary gland. The solid tumor component was of similar signal intensity to white matter on T1-weighted spin-echo images (500/20 [TR/TE]) and com-

parable signal intensity to gray matter on T2-weighted spin-echo images (3300/96). A nodular tumor component, adjacent to the tumor cyst, showed marked enhancement after the administration of contrast material, but there was no enhancement of the other solid tumor components.

The optic chiasm appeared enlarged, and the borders of the hypothalamus could not be well defined. The infundibular stalk was displaced posteriorly. The optic nerves were of normal size without evidence of infiltration (Fig 1). The radiologic diagnosis was consistent with pilocytic astrocytoma. Conservative management was continued because of the risk of visual impairment associated with surgery.

One and a half years later, the patient developed progressive visual deterioration with bitemporal field defects. Visual acuity was 20/20 in the right eye (OD), which is normal, and 20/25 in the left eye (OS), which represents a 5% visual loss. Repeat MR imaging showed a significant progression of the lesion, particularly of the cyst, then measuring $30 \times 28 \times 25$ mm. The nodular enhancing tumor component had also increased in size. The pituitary gland had a sharp border with progressive expansion of the pituitary stalk posteriorly but no signs of infiltration. There was no evidence of hydrocephalus (Fig 2).

The patient underwent a right pterional craniotomy and a subtotal resection of the tumor was performed. The postoperative course was uneventful, except for the persistent bitemporal hemianopia. The visual acuity was 20/40 (OD) and 20/80 (OS), a disabling reduction in visual acuity.

The diagnosis of ganglioglioma was made histologically. The cytological intraoperative smear preparations showed a cellular tumor consisting of neoplastic astrocytes and atypical neurons representing ganglion cells (Fig 3). Some of the neurons were enlarged and binucleate, and the astrocytic component showed moderate nuclear pleomorphism but no mitoses. In addition, there were occasional eosinophilic granular bodies and lymphocytes. The paraffin-embedded tissue showed only neoplastic astrocytes, which were positive on the glial fibrillary acidic protein immunoperoxidase stain. Glial fibrillary acidic protein is a laboratory stain for specific intermediate filaments found in astrocytes. The final histopathologic diagnosis was ganglioglioma of the hypothalamic chiasmatic region.

Discussion

Gangliogliomas involving the optic chiasm are extremely rare. To our knowledge, 11 cases, including ours, have been reported in the literature (Table) (3–9). We included one case of what we designated “ganglioneuromas” because abnormal neurons and neoplastic astrocytes were shown in the article (7). Adequate clinical data were available for 10 patients. The mean age was 20 years; 80% of the tumors were diagnosed during the first 3 decades. There was a slight male predilection with a ratio of 1.5:1. The presenting symptoms varied depending on the extent of the lesions. However, all of the patients had visual impairment. Sec-

Received November 12, 1999; accepted after revision February 15, 2000.

From the Departments of Neuropathology (S.S., V.A.F.), Radiology (E.K.), and Surgery (P.B.), Royal Perth Hospital, GPO Box X2213, Perth, Western Australia, and the Department of Pathology (S.S.), Faculty of Medicine, Chulalongkorn University, Bangkok 10330, Thailand.

Address reprint requests to Victoria Fabian, Department of Neuropathology, Royal Perth Hospital, GPO Box X2213, Perth, Western Australia 6001, Australia.

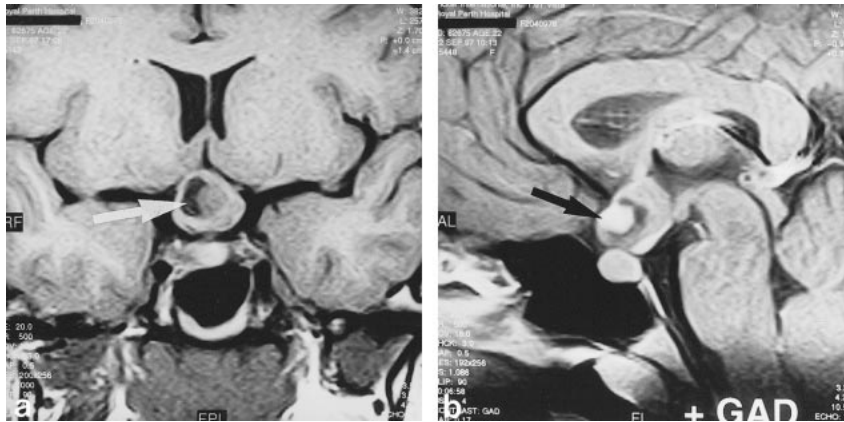


FIG 1. Images from the case of a 21-year-old woman who presented with mild galactorrhea and emotional instability.

A, Coronal, unenhanced, T1-weighted (500/20/3 [TR/TE/excitations]) MR image.

B, Contrast-enhanced sagittal image shows a mass with cystic (white arrow) and nodular contrast-enhancing (black arrow) components arising in the hypothalamus and optic chiasm.

Literature summary of gangliogliomas involving the optic chiasm

No.	Age (yrs)	Sex	Symptom(s)	Site(s)	Surgery	Radiotherapy	Follow-up	Ref
1	6	M	VA: OD 20/25, OS 20/60, bi-temporal HA, headache, vomiting	Chiasm, hypothalamus	Biopsy	55 Gy	5 yrs*, stable VA, VF	3
2	10	F	VA: OD LP, OS 20/100, L homonymous HA	R optic nerve, chiasm	Subtotal resection	500 r X-Ray (2 MEV)	4 yrs*, stable VA, VF	4
3	13	F	VA: OD 20/200, OS no LP, only R temporal island spared, L hemiparesis	Chiasm, R temporal, R thalamus, basal ganglia	Subtotal resection	...	8 mos*, bilateral blindness, extensive SA spread	3
4	15	F	Blindness OD, L temporal HA, R exophthalmos and strabismus, L hemiparesis	Entire R pregeniculate pathway R basal ganglion	Biopsy	...	6 yrs*	5
5	16	M	VA: OD 0.25, OS 0.33, bi-temporal HA	R optic nerve, chiasm	Resection	40 Gy	3 yrs*, VA: OD 0.1, OS 0.4	6
6	21	F	L temporal HA, Galactorrhea, VA: OD 6/9, OS 6/7.5, Bi-temporal HA	Chiasm, hypothalamus	Subtotal resection	...	3 mos*, VA: OD 6/12, OS 6/24, bitemporal HA	P
7	23	M	VA: OD 20/40, OS 20/25, behavioral changes, increased appetite	Third ventricle, chiasm, optic tracts, L temporal	Subtotal resection	given	17 yrs*, VA: CF, bilateral	3
8	24	M	VA: OD 0.33, OS 0.4, Bitemporal HA	R optic nerve, chiasm	Resection	40 Gy	2 yrs 11 mos*, VA: OD HM, OS LP	6
9	33	M	VA: OD 20/20, OS 20/25, L homonymous HA	Chiasm, R optic tract	Biopsy	54 Gy	1 yr*, No tumor progression	7
10	38	M	VA: OD 20/40, OS 20/25, severe R VF defect	Entire R pregeniculate pathway	Subtotal resection	...	NA	8
11	NA	NA	NA	Chiasm, hypothalamus	NA	NA	NA	9

Note.—Ref = reference, M = male, F = female, R = right, L = left, OD = right eye, OS = left eye, VA = visual acuity, VF = visual field (20/20 = 6/6 = normal), LP = light perception, HM = hand movement, CF = counting fingers, HA = hemianopia, SA = subarachnoid, yr = year, mos = month, * alive the last follow-up, NA = not available.

ondary hyperprolactinemia from pituitary stalk compression was observed in our case.

The differential diagnosis of suprasellar lesions is broad. The most common lesions in adults are meningiomas and suprasellar extension of pituitary adenomas, whereas in children, they are craniopharyngiomas and hypothalamic chiasmatic gliomas. Metastases and granulomatous disease are less common (10, 11).

Radiologically, a pilocytic astrocytoma was favored. Pilocytic astrocytomas at this site are indolent, slow-growing neoplasms, and their presenting symptoms vary depending on location. Neuroim-

aging usually reveals pilocytic astrocytomas to be mixed solid and cystic mass lesions in which 10% may show calcification. A mural nodule may show intense contrast enhancement. On MR images, these tumors are isointense relative to normal brain on T1-weighted images and iso- to hyperintense on T2-weighted images. Pilocytic astrocytomas usually show homogeneous contrast enhancement. Cystic formations may occur (11), as our case shows.

Gangliogliomas are characterized on CT scans as hypodense lesions with calcification and a variable contrast enhancement pattern. The MR findings are

FIG 2. Images from the same case, obtained 18 months later.

A, Coronal T2-weighted (3300/96/1) MR image.

B, Contrast-enhanced sagittal T1-weighted (500/20/3) MR image shows an obvious progression of the cystic tumor component (black arrows).

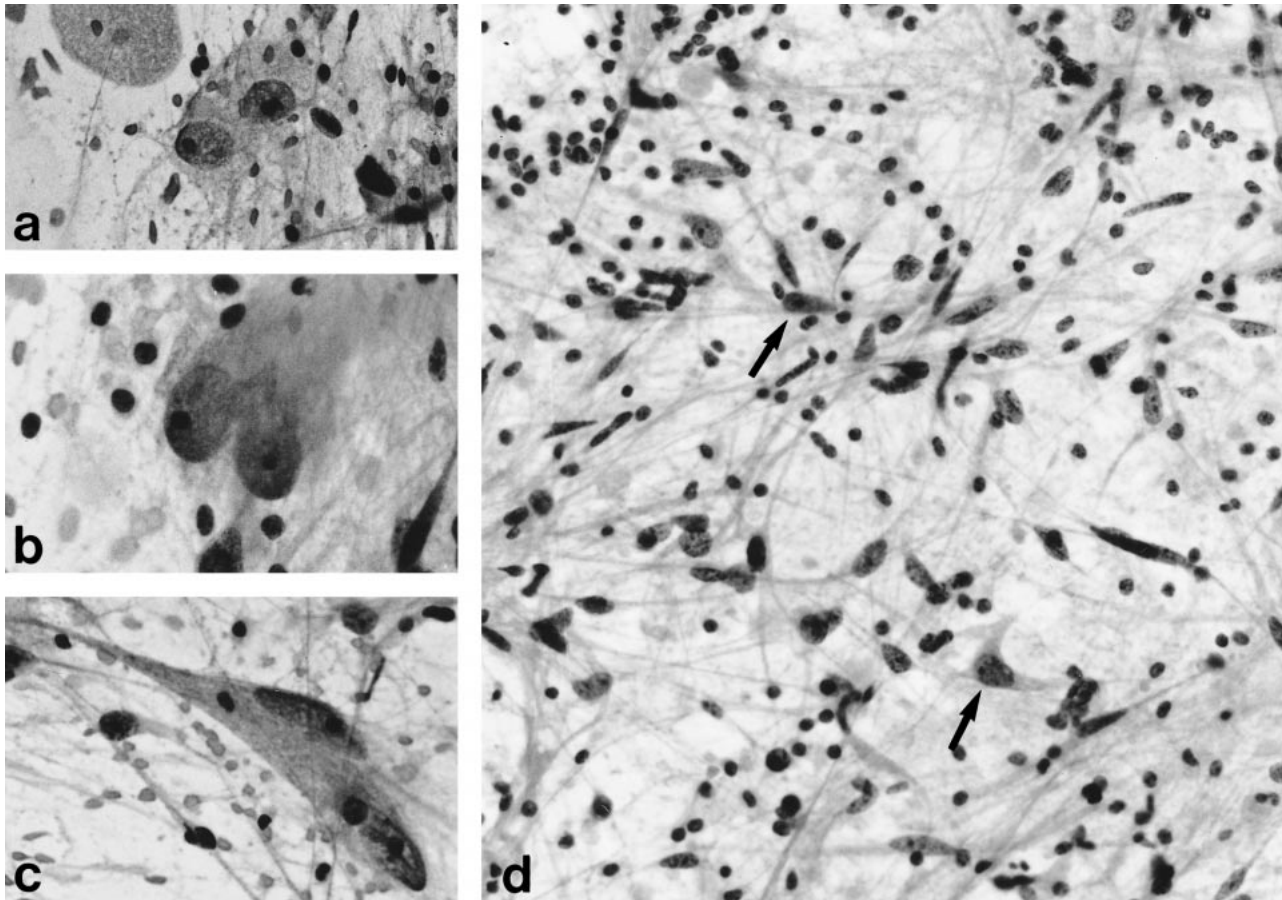
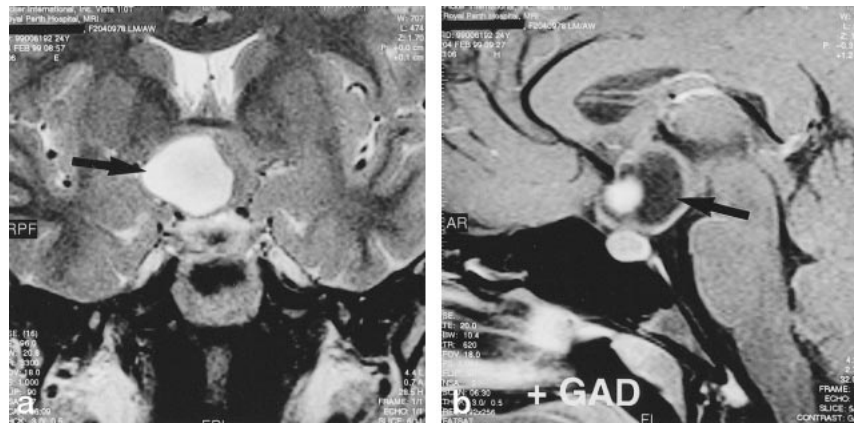


FIG 3. Cytological smear preparation of the ganglioglioma.

A, Abnormal binucleate neurons (hematoxylin and eosin; original magnification, $\times 275$).

B, Abnormal binucleate neurons (hematoxylin and eosin; original magnification, $\times 430$).

C, Abnormal binucleate neurons (hematoxylin and eosin; original magnification, $\times 275$).

D, Neoplastic astrocytes with their numerous cytoplasmic processes (hematoxylin and eosin; original magnification, $\times 275$).

nonspecific. As in our case, the lesions may be iso- to hypointense on T1-weighted images and hyperintense on T2-weighted images. Contrast enhancement was reported in 44% of one series and may have either a nodular rim or solid enhancement pattern (2). In our case, there was pronounced nodular enhancement at the border between the cystic and the solid tumor components. Cystic tumor components occur in up to 57% of gangliogliomas, as in

our case. However, 40% of cases may appear as solid lesions only. These cysts may show a higher signal compared with CSF on T2-weighted images, which represent gelatinous material (2).

The histopathologic criteria for diagnosis of ganglioglioma include neoplastic astrocytes and atypical neurons (1). The ganglion cells must be distinguished from preexisting non-neoplastic neurons, which might have been incorporated into an astro-

cytoma (12). Our case fulfilled these criteria with several large binucleate neurons with prominent nucleoli and an astrocytic component confirmed on the glial fibrillary acidic protein stain. In addition, eosinophilic granular bodies and lymphocytes further support the diagnosis of a ganglioglioma (1, 12). The normal optic chiasm does not contain ganglion cells. The neoplastic neurons in gangliogliomas in this region may have been derived from ectopic neural tissue (3, 7).

The optic chiasm may be involved by gangliogliomas at this site by three different mechanisms. The lesions in patient 1, patient 11, and our patient were intrinsic to the chiasm and hypothalamus, whereas that in patient 3 seemed to originate in the right temporal lobe and medially extended to compress the chiasm. Patient 3 had a long history of complex partial seizures. In seven cases (patients 2, 4, 5, and 7–10), the chiasm and other components of the visual pathway were involved. Chiasmatic involvement in gangliogliomas usually occurs in this way; however, there is difficulty in determining the exact origin of these tumors. They may have arisen in the chiasm and subsequently extended into the other parts of the optic pathway and vice versa.

Most CNS gangliogliomas are well circumscribed. Therefore, surgical excision is possible, resulting in a generally favorable prognosis (3, 8). However, complete resection often cannot be accomplished in cases with chiasmatic involvement. The role of postoperative radiotherapy is controversial and usually reserved for those with disease progression or recurrence (7, 8). Nevertheless, radiotherapy has been applied in those cases in which only biopsy or subtotal resection could be performed. (3, 4, 6, 7). Follow-up was available for

nine patients. All were alive during 8 months to 17 years of follow-up. No cases, including ours, showed significant visual improvement.

Conclusion

Gangliogliomas are relatively infrequent CNS neoplasms, which can be confused radiologically with low-grade pilocytic astrocytomas. We report this case to broaden the differential diagnosis of well-demarcated cystic lesions arising in the hypothalamic-chiasmatic region.

References

1. Lantos PL, Vandenberg SR, Kleihues P. **Tumours of the nervous system.** In: Graham DI, Lantos PL, eds. *Greenfield's Neuropathology*. 6th ed. London: Arnold;1997;663–677
2. Zentner J, Wolf HK, Ostertun B, et al. **Gangliogliomas: clinical, radiological, and histopathological findings in 51 patients.** *J Neurol Neurosurg Psychiatry* 1994;57:1497–1502
3. Liu GT, Galetta SL, Rorke LB, et al. **Gangliogliomas involving the optic chiasm.** *Neurology* 1996;46:1669–1673
4. Cogan DG, Poppen JL, Hicks SP. **Ganglioneuroma of chiasm and optic nerves.** *Arch Ophthalmol* 1961;65:481–482
5. Sugiyama K, Goishi J, Sogabe T, Uozumi T, Hotta T, Kiya K. **Ganglioglioma of the optic pathway: a case report.** *Surg Neurol* 1992;37:22–25
6. Lowes M, Bojsen-Moller M, Vorre P, Hedegaard O. **An evaluation of gliomas of the anterior visual pathways: a 10-year survey.** *Acta Neurochir (Wien)* 1978;43:201–206
7. Chilton J, Caughron MR, Kepes JJ. **Ganglioglioma of the optic chiasm: case report and review of the literature.** *Neurosurgery* 1990;26:1042–1045
8. Lu WY, Goldman M, Young B, Davis DG. **Optic nerve ganglioglioma: case report.** *J Neurosurg* 1993;78:979–982
9. Rodriguez LA, Edwards MSB, Levin VA. **Management of hypothalamic gliomas in children: an analysis of 33 cases.** *Neurosurgery* 1990;26:242–247
10. Osborne AG. **Diagnostic Neuroradiology.** St Louis: Mosby;1994; 461–482
11. Johnsen DE, Woodruff WW, Allen IS, Cera PJ, Funkhouser GR, Coleman LL. **MR imaging of the sellar and juxtaseellar regions.** *Radiographics* 1991;11:727–758
12. Moss TM, Nicoll JAR, Ironside JM. **Intra-operative Diagnosis of CNS Tumours.** London: Arnold;1997;90–92