



## Discover Generics

Cost-Effective CT & MRI Contrast Agents

 FRESENIUS  
KABI

[WATCH VIDEO](#)

# AJNR

## Functional MR Imaging Analysis of Pain-related Brain Activation after Acute Mechanical Stimulation

Christelle Créac'h, Patrick Henry, Jean Marie Caillé and Michèle Allard

This information is current as of June 16, 2025.

*AJNR Am J Neuroradiol* 2000, 21 (8) 1402-1406  
<http://www.ajnr.org/content/21/8/1402>

# Functional MR Imaging Analysis of Pain-related Brain Activation after Acute Mechanical Stimulation

Christelle Créac'h, Patrick Henry, Jean Marie Caillé, and Michèle Allard

**BACKGROUND AND PURPOSE:** Most studies concerning imaging of pain processing have used thermal, chemical, or electrical nociceptive stimulation. The aim of the present study was to determine the cortical representation of mechanical pain. For this, using functional MR (fMR) imaging at 1.5 T, we compared activation patterns during painful and nonpainful tonic mechanical stimulation in healthy volunteers.

**METHODS:** Eleven right-handed subjects ranging in age from 21 to 46 years underwent gradient-echo echo-planar fMR imaging while quantified tonic pressure was applied to the first metacarpophalangeal joint. Imaging parameters were 3000/60 (TR/TE) with a 5-mm section thickness in a 7.30-minute sequence with  $2 \times 90$  seconds of painful stimulation interleaved with  $3 \times 90$  seconds of nonpainful stimulation. Functional images were processed using dedicated IDL software.

**RESULTS:** Mechanical tonic nociceptive pressure was associated with activation of the primary somatosensory cortex contralateral to the hand stimulated and variable, often bilateral activation of the secondary somatosensory, temporal, anterior and posterior cingulate, insular, and prefrontal cortexes. Thalamic activation was inconsistent and always contralateral to stimulation.

**CONCLUSION:** The interindividual variability found in this fMR imaging study calls for repetitive single-subject analysis or more extensive studies of large groups of patients. Either may be based on fMR imaging analysis of brain activation after tonic mechanically induced pain, which leads to deep pain sensation similar to patients' painful sensations most commonly encountered in clinical practice.

Whereas early clinical observations appeared to indicate that the cerebral cortex played no more than a minor role in pain perception (1), imaging studies revealed the involvement of several cortical areas in processing normal pain sensation in humans (2). The most commonly activated regions include the primary (S1) and secondary somatosensory (S2) cortexes, as well as the prefrontal, anterior cingulate, temporal, and insular cortexes (2–14). Although a common corpus of brain areas is involved in the elaboration of normal pain sensation, some discrepancies concerning them exist in published experiments. Although technical factors cannot be excluded, differences in noxious stimulation (type, duration, frequency, and localization) probably contribute to this conflicting data. Until now, func-

tional imaging of pain processing has predominantly made use of phasic or tonic noxious heat, tonic cold, and noxious chemical or electrical stimulation of the skin (12). Little evidence has been published concerning cerebral activation in response to painful tonic mechanical stimulation used to induce deep pain, which is frequently encountered in clinical practice. Furthermore, it has been suggested that tonic pain may be psychologically more similar to chronic pain than phasic pain (15). Thus, using fMR imaging, we attempted to determine the neural correlates of acute normal pain sensation by comparing activation patterns during nociceptive mechanical stimulation to those of nonnociceptive mechanical stimulation in healthy human volunteers.

Received November 1, 1999; accepted after revision March 13, 2000.

From INSERM U.378 (M.A.) and Service de Neuroradiologie/Neurologie CHU de Bordeaux (C.C., P.H., J.M.C.).

Address reprint requests to Michèle Allard, INSERM U.378, Institut François Magendie, 1, Rue Camille St. Sams, 33076 Bordeaux France

© American Society of Neuroradiology

## Methods

### Human Subjects

Eleven right-handed healthy volunteers participated in this study (four female, seven male; age range, 21–46 years). All volunteers gave their informed consent before the experiment. The basic design of the study was described to all subjects, including the option to withdraw at any time. The subjects had

no medical, neurologic, or psychiatric illness and were pain-free. None of the subjects were taking analgesics or CNS-acting drugs.

#### Stimulation Procedures

Using a tensiometer, the mechanical stimulation consisted of quantified tonic pressure applied to the dorsal aspect of the left first metacarpophalangeal joint through a round surface with a 3-cm diameter. The detection threshold was defined as the lowest stimulus intensity required for the subject to report a sensation of pressure. The pain threshold was defined as the lowest stimulus intensity required for the subjects to report a sensation of pain. Prior to scanning, during preliminary testing, two stimulus intensity levels were identified: a level just above the detection threshold (from 4 to 6 mm Hg), which was applied during the rest period, and a level just above the pain threshold (from 15 to 18 mm Hg), which was applied during the activation period. Subjects then underwent a preliminary test to ensure that the mechanical stimulation could be tolerated. The experimental paradigm consisted of five interleaved nonpainful, rest and painful, activation phases; ie, three rest phases and two activation phases leading to a total scanning time of 7 minutes 30 seconds. Each phase included 10 images per slice. Immediately after completion of each functional scan, subjects rated their experience of pain intensity for each phase on a scale that measured 10 cm (visual analog scale [VAS]). One end of the analog scale read "no pain" and the other read "most severe ever experienced."

#### Functional MR Imaging Procedures and Data Analysis

All experiments were performed using a 1.5-T whole-body system with a circularly polarized head coil (Siemens, Erlangen, Germany). Sagittal T1-weighted images were acquired for anatomic identification. Ten noncontiguous transverse slices (thickness 5 mm, gap 1 mm) parallel to the anterior commissure–posterior commissure line were acquired to aid in anatomic identification of activated areas (T1-weighted; 350/15 [TR/TE]). For the functional studies, we used echo-planar sequences with a trapezoid readout, alternating gradient shape according to the following parameters: band width=780 Hz/pixel, 3000/60 (TR/TE),  $\alpha=90^\circ$ ; field of view= $28 \times 21$  cm, matrix  $64 \times 64$  interpolated up to  $128 \times 128$ . The same 10 transverse slice positions used for the T1-weighted images were used for the functional slices. During each activation or rest period, 10 images were acquired per slice for all 10 slices. Because of technical limitations, the maximum number of slices acquired was 10. Because we chose to explore the whole parietal cortex, we were not able to visualize the entire temporal or frontal cortexes or the cerebellum during the present experiments.

#### Data Analysis

Functional images were processed using dedicated interactive digital language software. All of the T2\*-weighted sequences were modified using a software for the correction of movement (adapted from NIH software by J. Pinon and C. Moonen). In order to select data without motion artifacts, they were subsequently screened in cinema mode for abnormal displacement, and the time course for signal intensity was inspected for any abrupt change. Subjects whose data contained such artifacts were excluded from the study.

Sites of task-related activation were determined by correlating image pixel intensity time courses from the dynamic MR data with the stimulus protocol using a box-car reference function that was shifted by one data point (8 s) to account for hemodynamic latencies and rise times. For each slice, the 30 averaged resting and the 20 averaged activated images were compared using Student's *t* test on a pixel-by-pixel basis ( $P<.001$ ). Cross-correlation coefficient threshold was set at

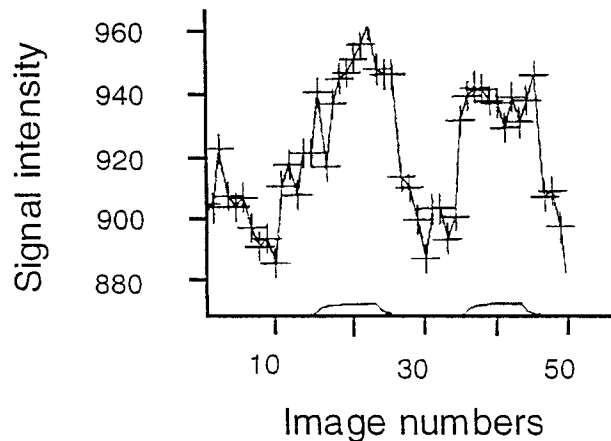


Fig 1. Time course of region of interest intensity in the secondary somesthetic cortex. The + sign represents each dynamic scan. Activation periods are represented on the abscissa (images 15–25 and 35–45). The five first images acquired were discarded from postprocessing analysis. Imaging parameters included 3000/60 (TR/TE) and a 5-mm section thickness in a 7-minute 30-second sequence with  $2 \times 90$  seconds of painful stimulation interleaved with  $3 \times 90$  seconds of innocuous stimulation. Functional images were processed using dedicated IDL software.

0.450, and a minimal value of 6 mm<sup>2</sup> per region of interest was selected for cluster analysis.

Time courses were analyzed to ensure that activation followed and did not precede the stimulus, and to calculate the mean signal change between conditions. Because it has been shown that a relative signal modification higher than 5% originates from the microvasculature (16), we retained for further analysis signals with an activation ratio less than 5%. An intensity change map was generated, which represented the difference between native images during noxious and innocuous stimulation.

#### Anatomic Localization

Functional images were superimposed over high-resolution conventional T1-weighted images. Regions activated were checked to ensure that they did not overlap areas of susceptibility artifact (ie, near sinuses or ventricles). We used anatomic landmarks to determine the location of the central sulcus. Each region of interest was assigned by two radiologists independently (C.C. and M.A.) by using Brodmann's classification. The regions of interest were grouped into nine functional brain structures.

#### Results

All subjects rated the noxious stimuli as obviously painful but tolerable, whereas rest periods were rated as innocuous (VAS: 0). The perceived pain level was comparable for the first and second painful period as indicated by the VAS values,  $5.1 \pm 0.6$  and  $5.5 \pm 0.7$ , respectively. Because we used a block-stimulation design (90 s), habituation effects due to prolonged stimuli were possible. There, however, was no attenuation of the signal over time either during a given stimulation period or between successive sessions. Figure 1 illustrates a typical subject in whom the average signal intensity was almost identical during the first and second activation periods:  $942 \pm 3.5$  and  $937 \pm 1.5$ , respec-

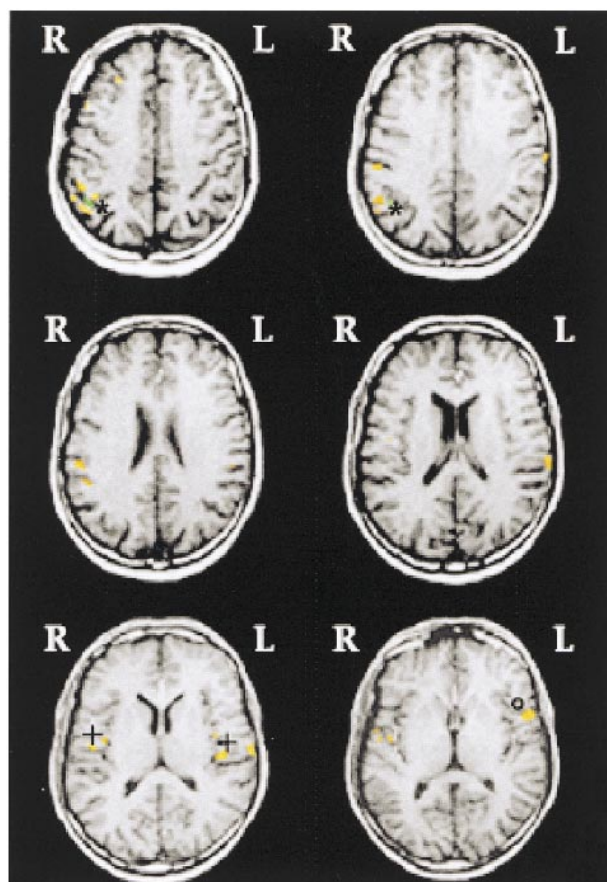


FIG 2. Cortical activation during noxious mechanical stimulation of the left hand in one subject. Imaging parameters included 3000/60 (TR/TE) and a 5-mm section thickness in a 7-minute 30-second sequence with  $2 \times 90$  seconds of painful stimulation interleaved with  $3 \times 90$  seconds of innocuous stimulation. Functional images were processed using dedicated IDL software. Activation maps are shown on six representative slices. R: right side; L: left side. Contralateral primary somatosensory (\*), bilateral superior parietal (+) and insular (open square) cortices. Colored scale represents the correlation coefficient between time-series data and the box-car reference waveform that corresponded to the task sequence threshold.

tively (mean value  $\pm$  SEM). These results were consistent with the closeness in pain intensity perceived by the subjects during the combined stimulation periods. This suggests that sensitization/habituation and interstimulus interactions were limited to a minimum. Consequently, subtractive analysis should be pertinent for this model of cortical activation by tonic mechanically induced cutaneous pain.

Figure 2 represents a typical activation map. In all subjects, unilateral left tonic mechanical stimulation induced bilateral cortical activation (Fig 2, Table). Secondary somatosensory cortex (S2) was activated in all 11 subjects, bilaterally in six, and unilaterally in five (three ipsilaterally and two contralaterally). The temporal, cingulate, insular, primary somatosensory, and inferoparietal cortices were variably activated during nociceptive stimulation and not one of these was activated in more than eight of the 11 subjects. A clear contralateral

Number of subjects with significant activation in specific structures

Activated Structures	Brodman Area	LH	RH	LH + RH
Prefrontal cortex	BA 8, 9, 46	1	0	5
Primary sensory cortex (S1)	BA 1, 2, 3	0	5	1
Secondary sensory cortex (S2)	BA 5, 7	3	2	6
Inferior parietal cortex	BA 39, 40	1	3	3
Superior temporal cortex	BA 22	1	3	4
Anterior cingulate cortex	BA 24	—	—	7
Posterior cingulate cortex	BA 21, 23	—	—	7
Insular cortex		2	1	4
Thalamus		0	3	0

Note.—Regions are identified by Brodmann (BA) number designation. LH: Left Hemisphere activated only; RH: Right Hemisphere activated only; LH + RH: activation of both left and right hemispheres. Regions needed to meet a minimum of 6 mm<sup>2</sup> to be considered activated, with each voxel meeting a threshold of  $P < .001$ . Imaging parameters included 3000/60 (TR/TE) and a 5-mm section thickness in a 7.30-minute sequence with  $2 \times 90$  seconds of painful stimulation interleaved with  $3 \times 90$  seconds of nonpainful stimulation.

lateralization was observed only in the primary somatosensory cortex (BA 1, 2, 3) in six subjects and in the thalamus in three. Given the medial localization of the cingulate cortex and the spatial resolution in this area, any activation in the cingulate cortex was arbitrarily considered to be bilateral (Table).

## Discussion

Our data give new insight into the neural correlates that process the conscious perception of normal tonic mechanically induced cutaneous pain. Here we show that such pain induced contralateral activation in S1 and, less frequently, in the thalamus, whereas polymodal association areas such as S2 and the prefrontal, cingulate, insular, temporal, and inferior parietal cortices were bilaterally activated.

External pressure applied to the dorsum of the digit, such as that used in this study, recruits both nociceptive afferent neurons and nonnociceptive neurons (17). Subtracting the effects of innocuous mechanical from noxious mechanical stimuli eliminates the tactile sensory-discriminative components involving texture and position of the acute noxious stimulus but not its intensity component. The preferentially contralateral S1 response, for which we found evidence, has also been shown by using tonic heat pain with substantial differences between the intensities of the noxious and innocuous stimuli in some of the available studies about tonic pain (8–10). Furthermore, Derbyshire et al (12) suggested that cold-pressor pain results in greater primary somatosensory cortex activation



than does heat pain alone because of the associated deep pain sensation. A deep pain sensory component of the mechanical stimulation used in the present experiment might explain the frequent contralateral S1 activation. Despite an abundance of clinical data concerning the respective roles of S1 and S2 in pain processing, there is still no consensus on this issue (2, 3). The constant activation of S2 observed in the present experiments may be explained by the involvement of S2 in somatosensory discriminative aspects of pain, which has been demonstrated in electrophysiological studies (18). This is consistent with findings obtained using tonic heat pain (8–10). The bilateral activation of S2 seen in six of our 11 subjects probably involved reciprocal connections between the S2, the nuclei of both thalami, and other cortical areas, which we also found to be activated in the present study.

The connections with attentional networks and arousal/vigilance systems of the inferoparietal cortex may underlie its activation (19) and orient subjects toward the sensory inputs. It is interesting to note that lesions of this area, especially on the right side, can result in sensory neglect (20). In line with this, we observed a preferential right-versus-left activation of the inferoparietal cortex. This activation might reflect hypervigilance to sensory information under our experimental conditions. The contribution of anticipatory arousal, which is implicitly involved in the cerebral response to pain, was probably enhanced because the chosen duration of each experimental session (7 min 30 s) was too short to permit randomization of the two noxious stimulation phases.

In view of the well-known spinothalamic projections and the presence of various nociceptive neurons in several thalamic nuclei, it is somewhat surprising that this area was not more intensely or consistently activated by the noxious stimulus used in this study. Indeed, contralateral thalamic activation was found in only three of the present eleven subjects, and none had ipsilateral thalamic activation. Evidence has been reported suggesting that experimental tonic stimulation could result in less thalamic response compared with phasic stimulation (8, 12). Nevertheless, thalamic activation has been shown in other studies on experimentally induced tonic pain, either contralateral or bilateral to the cutaneous stimulation (7). In fact, this aspect of our results might be attributable to a limited hemodynamic response in the thalamus. In addition, assuming thalamic nuclei to have different functional specializations, a particular signal from a given nociceptor nucleus may fail to rise significantly above background noise in fMR studies. Nevertheless, we found that target cortical areas of projections from these thalamic nuclei, including the insular and prefrontal and anterior cingulate cortices, were activated in several subjects.

The insular cortex has been shown to be bilaterally activated in different functional imaging studies in which the stimulation was tonic heat (8–

10) or cold pain (7, 8). Perception of pain has been found to be associated with activation of the anterior insular cortex preferentially with respect to the rest of the insular cortex (4, 8, 14). Herein we showed an inconstant, predominantly bilateral activation of the insular cortex, with a preferential involvement of the anterior and intermediate parts. Interestingly, central pain and pain asymbolia have been observed clinically after insular lesions (21). Moreover, the anterior insular cortex has connections with part of the prefrontal cortex (22) and part of the anterior cingulate cortex (23), which were also activated in our paradigm.

The prefrontal cortex is known to be involved in attention, but also in affective components of pain. For example, the affective perception of pain is considerably reduced by prefrontal leucotomy, despite the preservation of sensory aspects of pain (24). Our results showed a frequent activation of the lateral part of the prefrontal cortex, which was also found by Casey et al (7) with tonic cold pain, but not during phasic heat pain. This apparent discrepancy could be related to a difference in perceived unpleasantness.

A number of our subjects displayed activation of the anterior cingulate cortex, BA 24 and 23, a finding that is consistent with previous fMR imaging and positron emission tomography studies using tonic noxious stimulation (7–10, 12, 25, 26). Cingulotomy can suppress the affective components of pain in patients with intractable pain, without changing its sensory-discriminative aspects (27). Taken together, these observations and the anatomic links known to exist between the cingulate cortex and such areas as the limbic system and the prefrontal cortex support a potential role for the anterior cingulate cortex in emotional aspects of pain perception (28).

The present observations address the issue of the central representation of mechanically elicited tonic pain. Although the experimental conditions and pain perception of our eleven subjects were very comparable, none of the brain structures except S2 were activated in more than eight. At least three hypotheses might explain this variability: 1) A lack of sensitivity of the fMR technique might be the reason, but variable activation has also been reported using other imaging techniques (29). 2) Another factor could be changes in usual pain-related behavior attributable to MR procedures; for example, inhibition of fear reaction movements or MR-induced anxiety. 3) An interindividual variability in pain processing would be a straightforward explanation. Although we cannot exclude the first hypothesis, we believe that the variability observed herein reflects differences among individuals in psychophysical, affective-emotional, and cognitive components of pain. This effect suggests that an evaluation of psychophysical interindividual differences might be useful to help delineate specific neural components underlying the multiple facets of pain.

## Conclusion

In summary, by using fMR imaging, we showed that a distributed cortical pathway is involved in pain perception after tonic mechanical stimulation. This pathway included primary somatosensory cortex contralateral to the hand stimulated and bilateral secondary somatosensory cortex as well as the temporal, anterior and posterior cingulate, insular, and prefrontal cortexes.

Although intersubject variability exists in the neuronal networks that subserve tonic mechanical pain processing, we found a corpus of brain areas frequently activated, including the prefrontal cortexes. More extensive studies involving large groups of patients or repetitive single-subject analyses are warranted. Longitudinal follow-up of patients with chronic pain, for example, might demonstrate plastic changes in the neuronal network involved in pain perception. If the tonic mechanically induced pain used in the present study is a valid model of the deep pain experienced in such disorders as rheumatoid arthritis, it might contribute to the understanding of their pathophysiologic processes.

## References

- Head H, Holmes G. Sensory disturbances from cerebral lesions. *Brain* 1911;34:102-254
- Jones AKP, Brown WD, Friston KJ, Qi LY, Frackowiak RSJ. Cortical and subcortical localization of response to pain in man using positron emission tomography. *Proc R Soc Lond B Biol Sci* 1991;244:39-44
- Talbot JD, Marrett S, Evans AC, Meyer E, Bushnell MC, Duncan GH. Multiple representations of pain in human cerebral cortex. *Science* 1991;251:1355-1358
- Coghill RC, Talbot JD, Evans AC, et al. Distributed processing of pain and vibration by the human brain. *J Neurosci* 1994;14:4095-4108
- Casey KL, Minoshima S, Berger KL, Koeppe RA, Morrow TJ, Frey KA. Positron emission tomographic analysis of cerebral structures activated specifically by repetitive noxious heat stimuli. *J Neurophysiol* 1994;71:802-807
- Apkarian AV. Functional imaging of pain: new insights regarding the role of the cerebral cortex in human pain perception. *Semin Neurosci* 1995;7:279-293
- Casey KL, Minoshima S, Morrow TJ, Koeppe RA. Comparison of human cerebral activation patterns during cutaneous warm, heat pain, and deep cold pain. *J Neurophysiol* 1996;76:571-581
- Craig AD, Reiman EM, Evans A, Bushnell MC. Functional imaging of an illusion of pain. *Nature* 1996;384:258-260
- Rainville P, Duncan GH, Price DD, Carrier B, Bushnell MC. Pain affect encoded in human anterior cingulate but not somatosensory cortex. *Science* 1997;277:968-971
- Svensson P, Johannsen P, Jensen TS, et al. Cerebral representation of graded painful phasic and tonic heat in humans: a positron emission tomography study. *Proceedings of the 8th World Congress on Pain, Progress in Pain Research and Management*, T.S. Jensen, J.A. Turner, and Z. Wiesenfeld-Hallin, eds, Seattle: IASP Press;1998;8:868-878
- Xu X, Fukuyama H, Yazawa S, et al. Functional localization of pain perception in the human brain studied by PET. *Neuroreport* 1997;8:555-559
- Derbyshire SWG, Jones AKP. Cerebral response to a continuous tonic pain stimulus measured using positron emission tomography. *Pain* 1998;79:127-135
- Porro CA, Cettolo V, Francescato MP, et al. Temporal and intensity coding of pain in human cortex. *J Neurophysiol* 1998;80:3312-3320
- Davis KD, Kwan CL, Crawley AP, Mikulis DJ. Functional MRI study of thalamic and cortical activations evoked by cutaneous heat, cold, and tactile stimuli. *J Neurophysiol* 1998;80:1533-1546
- Sternbach RA. The need for an animal model of chronic pain. *Pain* 1976;2:2-4
- Menon RS, Ogawa S, Tank DW, Ugurbil K. Tesla gradient recalled echo characteristics of photic stimulation-induced signal changes in the human primary visual cortex. *Magn Reson Med* 1993;30:380-386
- Besson JM, Chaouch A. Peripheral and spinal mechanisms of nociception. *Physiol Rev* 1987;67:67-186
- Bromm B, Treede RD. Laser-evoked potentials to mechanical and electrical stimulation in man. *Rev Neurol* 1991;147:625-643
- Posner MI, Dehaene S. Attentional networks. *TINS* 1994;17:75-79
- Heilman KM, Watson RT, Valenstein E, et al. Attention: behavior and neuronal mechanism. In: VB Mountcastle, F Plum and SR Geiger, eds, *Handbook of Physiology*. Sect. 1, *The Nervous System*, Vol V, *Higher Functions of the Brain*, Part 1, Bethesda: Am Physiol Soc;1987:461-481
- Potagas C, Avdelidis D, Singounas E, Nfissir O, Aessopos A. Episodic pain associated with a tumor in the parietal operculum: a case report and literature review. *Pain* 1997;72:201-208
- Preuss TM, Goldman-Rakic PS. Connections of the ventral granulate cortex of macaques with perisylvian premotor and somatosensory areas: anatomical evidence for somatic representation in primate frontal association cortex. *J Comp Neurol* 1989;282:293-316
- Augustine JR. Circuitry and functional aspects of the insular lobe in the primates including humans. *Brain Res Rev* 1996;22:229-244
- Davis KD, Hutchinson WD, Lozano AM, Dostrovsky JO. Altered pain and temperature perception following cingulotomy and capsulotomy in a patient with a schizoaffective disorder. *Pain* 1994;59:189-199
- Hsieh JC, Stähle-Bäckdahl M, Hägermark O, et al. Traumatic nociceptive pain activates the hypothalamus and the periaqueductal gray; a positron emission tomography study. *Pain* 1995;64:303-314
- Davis KD, Taylor SJ, Crawley AP, Wood WL. Functional MRI of pain- and attention-related activations in the human cingulate cortex. *J Neurophysiol* 1997;77:3370-3380
- Pillay PK, Hassenbach SJ. Bilateral MRI-guided stereotactic cingulotomy for intractable pain. *Stereotact Funct Neurosurg* 1992;59:33-38
- Devinsky O, Morrell MJ, Vogt BA. Contributions of anterior cingulate cortex to behaviour. *Brain* 1995;118:279-306
- Vogt BA, Derbyshire SWG, Jones AKP. Pain processing in four regions of human cingulate cortex localized with co-registered PET and MRI. *Eur J Neurosci* 1996;8:1461-1473