



Providing Choice & Value
Generic CT and MRI Contrast Agents



FRESENIUS
KABI

CONTACT REP

AJNR

Detachable Balloon Embolization: Safety Balloon Technique

Pearse Morris

AJNR Am J Neuroradiol 2000, 21 (5) 984

<http://www.ajnr.org/content/21/5/984.2>

This information is current as
of July 19, 2025.

High-field, High-resolution MR Imaging of the Human Indusium Griseum

In the March 1999 issue of the *AJNR*, Nakada (1) indicates that one or more elevations medial to the superior surface of the corpus callosum represent the indusium griseum (Fig 1). I believe he is incorrect because these elevations represent the *medial* longitudinal striae of Lancisii (Fig 1, 2). A lateral longitudinal stria of Lancisii also exists, as can be seen on the left laterally in Figure 1B. These medial and lateral longitudinal striae are believed to be rudiments of the fornices proper that remain dorsal to the corpus callosum during embryogenesis. Together with the indusium griseum, the longitudinal striae form the supracallosal hippocampal rudiments. The medial and lateral longitudinal striae are small bundles of myelinated fibers that primarily originate in the hippocampi in the temporal lobes and run forward underneath the thin layer of gray matter of the indusium griseum to project mainly in the septal area. Fibers arising from the indusium griseum itself and fasciola cinerea also run within these longitudinal striae. The exact sub-regional origin(s) and precise termination(s) of the majority of fibers in the medial and lateral longitudinal striae of the Lancisii is not known with certainty. Similarly, the functional aspects of these hippocampal rudiments is unclear (2–7).

J. Randy Jenkins, M.D., FACR
 Director of Neuroradiology
 University of Texas Health Science Center
 San Antonio, Texas

References

1. Nakada T. **High-field, high-resolution MR imaging of the human Indusium Griseum.** *AJNR Am J Neuroradio* 1999;20:524–525
2. Duvernoy HM. **The Human Hippocampus.** In *Atlas of Applied Anatomy.* München, F.R.G.: Gergmann Verlag; 1988;43–75
3. Parent A. **Carpenter's Human Neuroanatomy.** Baltimore: Williams & Wilkins; 1996:763
4. Burt AM. **Textbook of Neuroanatomy.** Philadelphia: W.B. Saunders; 1993;487–491

5. Pansky B, Allen DJ, Budd GC. **Hippocampal Formation.** In: *Review of Neuroscience.* New York: McGraw-Hill; 1988:266
6. Williams PL. In: *Gray's Anatomy.* New York: Churchill Livingstone; 1995:1178
7. Nieuwenhuys R, Voogd J, van Huijzen C. **The Human Central Nervous System.** New York: Springer-Verlag; 1978:300

Reply

I believe that Dr. Jenkins is not aware of the fact that the presented images were T2-reversed (T2R) images as described in the Methods section where T2-weighted images are video-reversed. Perhaps he inadvertently believed that the images presented were T1-weighted and the structure had an intensity equivalent to that of fiber tracts. As you can immediately understand by examining the cortex, the structure that I identified as the indusium griseum (IG) had “gray matter” density. Unfortunately, reproduction of the fine images into a journal article often makes identification of contrast differences difficult. Nevertheless, I believe that one can identify the IG as gray matter in the presented T2R images. It is much more difficult, if not impossible, to identify the longitudinal striae (LS), which are fiber tracts, because these structures have intensity characteristics that are viturally identical to those of the corpus callosum. Nevertheless, LS can occasionally be distinguished as a structure adjacent to the IG, as in the case of Figure 1B (a small white matter structure next to the IG).

I hope that this explanation clears up the concerns of Dr. Jenkins.

Tsutomu Nakada, M.D., Ph.D.
 Professor and Chair
 Department of Integrated Neuroscience
 Brain Research Institute
 University of Niigata
 Niigata, Japan

Dr. Leighton Mark was invited to comment on this issue.

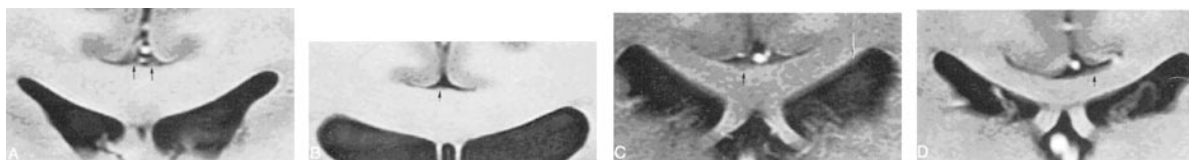


FIG 1. Representative MR images of the IG classical, symmetric two-strip (A), symmetric, but centrally fused (B), lateralized, single-strip (C), and thin-layer (D) patterns.

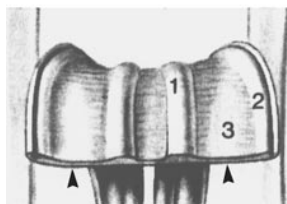


FIG 2. The medial and lateral longitudinal striae of Lancisii. Schematic of the superior aspect of the anterior extent of the supracallosal hippocampal remnants with cut edge (arrowheads) shows: 1) medial longitudinal stria; 2) lateral longitudinal stria; and 3) indusium griseum. (Reprinted from: Nieuwenhuys R, Voogd J, van Huijzen C. *The Human Central Nervous System.* Berlin: Springer-Verlag 1988:300, with permission.)

Commentary

Drs. Nakada and Jinkins have expressed seemingly different interpretations for the imaged structures labeled in Figure 1 from Dr. Nakada's paper (1). Dr. Nakada identifies the labeled structure as the indusium griseum (IG), whereas Dr. Jinkins believes these elevations represent the medial longitudinal striae of Lancisii (MLS). These anatomic issues, related to what is essentially a technical discussion, are effectively presented, but the reader may still wonder if the structure is the IG or MLS.

It is difficult for me to reach a simple conclusion, but I would instead like to frame the question from the perspective of some of the associated anatomic and technical nuances related to this issue, which I feel are more complicated than simple anatomic identification.

It is generally agreed that the IG represents gray matter and the MLS are white matter fiber tracts. Furthermore, the MLS can cause a small focal elevation on the surface of the IG in a paramidline position. The MLS are frequently considered vesigial, but concern about sparsely myelinated fibers contributing to the gray matter MR appearance may not be an issue, because the MLS are probably fully myelinated with a normal relationship of axonal diameter to myelin sheath thickness (2). The IG covers the entire surface of the body of the corpus callosum from the midline to the callosal sulcus, but it can be nodular and vary in thickness, appearing maximally just under 1.0 mm near the midline with rapid tapering on either side, and can thin out to just several cell layers thickness (Personal communication: Douglas C. Miller, M.D., Ph.D., Director, Neuropathology; Director, Pathology Residency Programs, NYU Medical Center/Bellevue Hospital). There are, however, unresolved but related questions regarding the difference/similarities in the IG appearance between populations that differ in age, sex, race, and geography.

A 3-T MR unit would offer an advantage with increased signal to noise, but depiction of brain anatomy becomes a more complicated issue. The gray/white contrast can decrease at this higher field strength because of the disproportionate T1 signal increase of the gray and white matter. The T2 signal intensity of cerebral tissue is less affected especially when very strongly T2-weighted techniques are used. The fast spin-echo technique, however, offers special challenges, including artifactual changes in k-space at shorter TE and a widened point spread function, affecting the delineation of subtle anatomy. In addition, the use of a 12-cm field of view (FOV) with a 512×512 matrix creates maximal resolution of about 0.23 mm, which introduces volume averaging confounds for portions of the IG smaller than 0.23 mm. The slice thickness is also an important component of the issue of volume averaging and is not mentioned in Nakada's article.

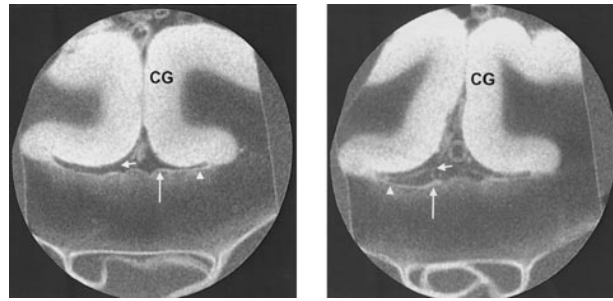


FIG 1 left. Coronal T2-weighted MR image of a specimen showing a very thin, nearly uniformly thick IG (*long arrow*), with the more lateral component (*arrowhead*) that extends into the callosal sulcus (*short arrow*). Note the focally elevated contour of the more medial portion of the IG. [CG = cingulate gyrus] (SE, 1000/35/4 [TR/TE/excitations], FOV=2 cm, 1.0-mm slice thickness, 256×256 matrix)

FIG 1 right. Coronal T2-weighted MR image of a different specimen showing a thickened appearance to the paramidline portion (*long arrow*) of the IG with a thinner, more lateral section (*arrowhead*) that can still be seen extending into the callosal sulcus (*short arrow*). The thickened component of the IG also exhibits a slight, focally convex superior margin, (SE, 1000/35/4 [TR/TE/excitations], FOV=2 cm, 1.0-mm slice thickness, 256×256 matrix)

My own previous anatomic study of the IG was biased toward the use of a routine spin-echo technique at 1.5-T field strength to avoid some of the mentioned problems. The signal to noise is then significantly augmented by the use of a 2.5-cm single-turn inductively coupled solenoid surface coil. This is used with a 2.0-cm FOV, 256×256 matrix, and 1.0-mm slice thickness for a maximal pixel resolution of 0.07 mm. Figures 1 left and right are images obtained with this technique. Figure 1 left shows a fairly uniform, very thin gray matter appearance of the IG layered on the superior surface of the corpus callosum, covering the midline and extending into the callosal sulcus region. The focally elevated contour of the IG near the midline is probably related to the MLS, which is difficult to distinguish from the adjacent white matter of the corpus callosum. Figure 1 right shows a slightly thickened appearance of the IG closer to the midline but a very thick component is still visible near the callosal sulcus. This portion of the IG also reveals a slightly elevated contour.

In summary, I find it difficult to evaluate the very small anatomy in question owing to the article's images obtained with those particular technical parameters, and I am unable to decide confidently if the labeled structure represents only the IG or MLS. It is entirely possible, however, for both seemingly discordant opinions to be correct or at least consistent with my own observations. The focal thickening of the gray matter on the superior surface of the corpus callosum, therefore, may represent the IG (though the rest of the IG is not visible but is probably present, though very thin), and the focally elevated contour of the IG may be related to the underlying MLS, thickened IG, or both, though a focally thickened IG is not necessary to produce the focal convexity.

Dr. Nakada's article and the controversy it generates indicate the need for further refinements in in vivo microanatomic MR imaging, and his work should be considered a positive step in that direction.

Leighton P. Mark, M.D.
Neuroradiology Section
Department of Diagnostic Radiology
Medical College of Wisconsin

References

1. Nakada T. **High-field, high-resolution MR imaging of the human indusium griseum.** *AJNR Am J Neuroradiol* 1999;20:524-525
2. Arroyo-Guijarro J, Prats-Galino A, Ruano-Gil D, Costa-Lloet C. **Comparative study of the medial longitudinal striae of the hippocampus (formerly called "nerves of Lancisi") in the fighting bull and domestic bull.** [*French*] *Bulletin de l'Association des Anatomistes* 1988;72:15-19

Detachable Balloon Embolization: Safety Balloon Technique

Masaryk et al have given an excellent description of a technique used during deployment of a detachable balloon in a carotid cavernous fistula (1). Their technique involves placement of two introducer catheters in the carotid artery and placement of parallel microcatheters, one carrying a detachable balloon, the other a nondetachable balloon. The nondetachable balloon can then be used either to extrude the detachable balloon through the fistula to the venous side or stabilize it there during detachment. I have used a similar technique in the treatment of several carotid cavernous fistulas and found it to be extremely useful in preventing backward traction on the detachable balloon. Moreover, the technique is also very helpful in balloon occlusion of carotid arteries, where it significantly reduces the tendency of detachable silicone balloons (DSB) to slip back down the artery during traction on the microcatheter. A convenient improvement in technique that readers might find useful is that the entire procedure can be performed with a single 7F or 8F introducer catheter using a single-port Y-adaptor. This can be performed by advancing the DSB first through the main catheter. Be sure that it is all the way out of the catheter, lest the following nondetachable balloon should catch it within the catheter and cause it to detach inadvertently and embolize. A non-detachable Endeavor balloon (Boston Scientific, Watertown, MA) can be stiffened with a Transend 0.010-cm wire (Boston Scientific) and then advanced in a parallel direction through the first catheter. It can be inflated with the wire in place by using a Tuohy-Borst adaptor. The nondetachable balloon then can be used to stabilize the DSB during detachment either within a fistula or within an artery. In several consecutive cases, I have had no difficulty detaching

the more distal DSB, even though the mounting microcatheter is pinioned against the vessel wall by the inflated Endeavor balloon. In my experience, this technique has greatly facilitated ease and accuracy of detachment positions in use of DSBs and is now employed routinely in all DSB cases.

Pearse Morris, MB, BCH
Wake Forest University School of Medicine
Winston-Salem, North Carolina

References

1. Masaryk TJ, Perl J, Wallace RC, Magdinec M, Chyatte D. **Detachable balloon embolization: concomitant use of a second safety balloon.** *AJNR Am J Neuroradiol* 1999;20:1103-1106

In Re: The Presyrinx State: a Reversible Myelopathic Condition that May precede Syringomyelia

I read with interest the paper by Fischbein et al in which prominent motion of the tonsils was seen in a patient with a Chiari I malformation on a phase-contrast velocity MR image (1). This observation confirms our report in which similar findings were made in seven of eight patients with the malformation (2). We attributed this prominent motion to an increase in the downward systolic velocity of the tonsils in the Chiari I malformation. It has been postulated that this increase in the tonsillar velocities may contribute to the development of syringomyelia by causing an increased systolic pressure wave forcing CSF into the cord parenchyma during systole (3). Another cause for the increased flow of CSF into the cord parenchyma may be an increase in the duration of CSF systole at the C2-C3 level in patients with the Chiari I malformation and syringomyelia, as reported by our group (4). This alone could lead to an increase in the bulk flow of CSF into the spinal cord. After surgical removal of bony structures at the craniocervical junction and decompression of the tonsils, the syrinx cavity collapsed and the duration of systole decreased (4). The increase in systolic pressure, forcing CSF into the spinal cord parenchyma during systole postulated by Fischbein et al (1) and others (3), while intuitively correct, needs to be proved by direct CSF pressure measurements of the cervical subarachnoid space in these patients.

Samuel M. Wolpert, M.D.
Santa Fe, NM 87501

References

1. Fischbein NJ, Dillon WP, Cobbs C and Weinstein PR. **The presyrinx state: a reversible myelopathic condition that may precede syringomyelia.** *AJNR Am J Neuroradiol* 1999;20:7-20

2. Wolpert SM, Bhadelia RA, Bogdan A, Cohen A. **Chiari I malformations: assessment with phase-contrast velocity MR.** *AJNR Am J Neuroradiol* 1994;15:1299-1308
3. Oldfield EH, Muraszko K, Shawker TH, Patronas NJ. **Pathophysiology of syringomyelia associated with Chiari I malformation of the cerebellar tonsils.** *J Neurosurg* 1994;80:3-15
4. Bhadelia RA, Bogdan AR, Wolpert SM et al. **Cerebrospinal fluid flow waveforms: analysis in patients with Chiari I malformation by means of gated phase-contrast MR imaging velocity measurements.** *Radiology* 1995;196:195-202

Curved Planar Reformatted CT Angiography: Utility for the Evaluation of Aneurysms at the Carotid Siphon

I read with interest the article by Ochi et al (1) and can confirm that the technique they describe is accurate in the detection and delineation of aneurysms of the terminal internal carotid artery. It is a technique that we have been employing within the Institute of Neurological Sciences in Glasgow since 1988 that evolved to an examination of patients with isolated CN III palsy, with the goal of obviating the need for invasive angiography (2). The original method used overlapping single slices and a straight parasagittal oblique plane planned from the coronal reformation with standard Philips software. In 1990 when the Elscint Elite CT was installed, true curved planar reformations (CPR) were introduced, producing a curved parasagittal oblique from the coronal arterial projection, as described by Ochi et al. We reported 36 patients prospectively studied with isolated CN III palsy: 17 aneurysms were found in 13 patients, all causative aneurysms were detected, and all normal vessels and aneurysms were confirmed with arterial angiography. Another article followed on the comparison between 3D CT and CPR (3), and our conclusions are similar to those described by Ochi et al; that is that CPR is superior to 3D CT for the detection and delineation of aneurysms even with cine loop rotations of the 3D data. This led us to replace conventional angiography with CT angiography and CPR by 1990 for the primary investigation of patients with CN III palsy. The technique is robust, and its efficacy is attested to by a recent follow-up article of 100 consecutive patients with CN III palsy investigated by CT angiography (4) in whom all causative aneurysms were detected and follow-up showed no cases had been missed. Those palsies caused by local tumors were also diagnosed from the source images as the scanning of parameters (120 Kv 400 mas per single slice) allowed analysis of the soft tissues and vessels, unlike to low-helical CT angiographic technique of Ochi et al.

Evelyn Teasdale
*Department of Clinical Neuroradiology
 Institute of Neurological Sciences
 Glasgow Scotland*

References

1. Ochi T, Shimizu K, Yasuhara Y, Shigesawa T, Mochizuki T, Ikezoe J. **Curved planar reformatted CT angiography: usefulness for the evaluation of aneurysms at the carotid siphon.** *AJNR Am J Neuroradiol* 1999;20:1025-1030
2. Teasdale E, Statham P, Straiton J, et al. **Non-invasive radiological investigation for oculomotor palsy.** *J Neurol Neurosurg Psychiatry* 1990;53:549-553
3. Teasdale E, Straiton J, Macpherson P. **Dynamic computed tomography in patients with oculomotor palsy: multiplanar and 3D reformations.** *Neuroradiology* 1991;33 (Supp):45-47
4. McFadzean RM, Teasdale EM. **Computerised tomography angiography in isolated IIIrd nerve palsies.** *J Neurosurg* 1998;88: 679-684

Experimental Arteriovenous Malformations Modeling in Laboratory Sheep Versus Swine

In a recent article in the *AJNR* (1), Qian et al presented an interesting attempt at creating an arteriovenous malformation (AVM) model in sheep, a laboratory animal that had not been used previously for this purpose. The authors are to be congratulated on their commendable intentions and efforts to create an experimental AVM model aimed at providing an additional laboratory tool to study these difficult and challenging lesions. Several issues in their article deserve further comment because their presentation raises two significant concerns. I would suggest that the "AVM model" presented is neither "simplified" nor is it truly representative of a cerebral AVM.

The authors stated that the main purpose of their study was to create a "simplified" AVM model specifically, compared with a previously presented swine AVM model (1-6) that does not require in its construction the "highly sophisticated neurointerventional skills" for occluding three "intracranial" arterial branches. Five observations can be made about this statement. First, the three arterial branches concerned, the muscular branch of the ascending pharyngeal artery (not the ascending pharyngeal artery proper, as stated at one point by the authors), the occipital artery, and the external carotid artery, all ipsilateral to the neck fistula, are all extracranial neck arteries easily accessible via the endovascular route should this be required. They are not "intracranial" as alluded to by the authors in their abstract. Arteries above the skull base generally cannot be accessed endovascularly in the swine.

Second and most importantly, occlusion of these three branches had been abandoned long ago in the swine model, as documented in the literature (5, 6) but not referenced by Qian et al. It was found subsequent to the first studies using the swine model, in which occlusion of side branches was performed, that in fact it behaved hemodynamically (ie, with satisfactory and realistic angiographic shunting across the nidus) just as well without having to occlude the three side branches. Occlusion of these branches was omitted to simplify even further the construction of the swine AVM model, and

therefore, for some time now requiring *only* the creation of a surgical carotid–jugular fistula compared with the original model first described in 1993. This change was introduced while accepting the theoretical likelihood that this also resulted in marginal reduction of the postoperative blood shunting through and channeling from both retia to the fistula (5, 6). Importantly, hemodynamic validation studies (5, 6) of the swine model without occlusion of the side branches indicated that its transnidus blood flow and pressure characteristics were somewhat representative of human AVMs. Therefore, the *raison d'être* for the study of Qian et al would appear to be erroneous, because with regard to model construction, one model cannot be deemed to be a *simplified* version of another if both construction techniques are *identical*. The current swine AVM is already simple by the criteria of Qian et al.

Third, the methods of occluding arterial branches used in the original swine model were not at all “complex” and do not require “highly sophisticated neurointerventional skills;” quite contrary to the repeated suggestions by the authors. This is misleading because they are usually regarded as very simple and standard vascular interventional maneuvers that can be learned easily, should it be necessary to employ them. Indeed, the actual methodology of occluding these branches was of secondary importance within the overall context of constructing the earlier version of the swine model. For that matter, any possible device or technique (the simplicity/complexity of which could suit one experience) could have served to achieve the objective of vascular occlusion. Even the injection of small amounts of embolic glue could have been used as a way to practice occluding normal arteries, especially the two smaller ones, prior to the subsequent nidus embolization.

Fourth, if the object of creating an animal AVM model is to gain experience in embolization techniques and vascular interventional skills, as has been the intent of Qian et al, then it could be argued that the valuable experience gained in occluding arterial branches in the neck during construction of the AVM model (and in sheep only one branch would have to be occluded [read further]) would actually add considerably to the skills of the trainee and might be a desirable additional exercise to any vascular interventional training course. This had been pointed out in an early article on the swine AVM model (3). The extra cost of having to occlude these side branch(es), whether three in swine or one in sheep, would go toward providing additional trainee experience, or the extra cost and resulting trainee experience can be omitted, as desired by the course organizers. It would be fair to say as well that the very conventional “expensive microcatheters and wires” used in occluding side branches would most likely be reused in the subsequent embolization of the AVM nidus, and there-

fore these do not represent the source of much extra cost as portrayed by Qian et al.

Lastly, because there is no ascending pharyngeal artery in the sheep, and the external carotid artery ipsilateral to the fistula would have to be preserved to conduct blood down to the fistula, this leaves the ipsilateral occipital artery as the only branch in question (eg, swine model) as to whether it should be occluded or not in the sheep model presented. In this regard, a significant concern of the author's work is their incorrect interpretation of the angiograms they present. Contrary to their statement in the results section, the occipital artery on the fistula side is visualized very clearly as it fills in a retrograde direction from the contralateral occipital artery because of the sump effect of the nearby carotid–jugular fistula. This has significant detrimental implications in terms of flow diversion higher up through the so-called “nidus” (see below). Occlusion of this occipital artery on the fistula side would appear to be essential in the sheep, regardless of its cost, to increase flow diversion and enhance the poor flow through the so-called “AVM” as seen in the postsurgical angiograms presented.

The very act of experimental model construction necessitates the observation of clear fundamental rules and links in a chain of events related to the scientific method (7). First among these rules is that model selection and construction must be predicated on the best available known description of the real world entity to be modeled, and in this case, of cerebral AVMs. Following this closely is the mandatory requirement of preliminary model validation by testing its accuracy; this is achieved by matching the behavior of the model with known scientific observations about this entity. The sheep AVM model presented fails on both counts in relation to both its morphologic characteristics and its angiographic hemodynamic behavior.

In terms of basic morphologic characteristics, the sheep model bears little resemblance to cerebral AVMs in two ways. First, the overall shape/contour of the so-called “nidus” is very unlike that of cerebral AVMs. The sheep “nidus” is composed of one rete mirabile, ie a distinct vascular network connected to the contralateral rete (another distinct structure) by a *few* midline interretial vessels. This connection may even be a single vessel, as seen in a plastic cast presented by Daniel et al (8). Such a distinctly discontinuous appearance is almost never seen in conventional nidi of cerebral AVMs, unless some other event has occurred to induce this odd appearance, such as a hemorrhagic episode with an unusual subsequent partial thrombosis or a grossly unsatisfactory partial radiosurgical obliteration of the middle portion of a large nidus. Qian et al have justified this appearance in their “model” by stating that the sheep “actually has a double AVM nidus” more characteristic of multiple AVMs (mAVMs). This is unsatisfactory on two counts: 1) mAVMs constitute less than 2% of all AVMs (9),

and therefore a model of this specific entity is of little use because it is nonrepresentative of the great majority of cerebral AVMs; and 2) the great majority of mAVMs are distant from each other and are fed and drained by separate arteries and veins. To my knowledge, the presence of two communicating mAVMs *might* have existed (because they shared a common draining vein) in one patient reported in the literature by Voigt et al (9, 10). This extremely rare configuration is what is being modeled in the sheep by Qian et al. As well, there are negative practical implications of this "double nidus" in the sheep model, because the goal of any attempted simulation of transarterial (3, 4) or transvenous (2) embolization of the nidus should be to target the entire nidus. That is, it should be necessary to demonstrate with whatever embolic agent being used, that it should at least be capable of reaching the rete contralateral to the site of injection. With such a degree of physical separation of the retia in the "double nidus" of the sheep, this is unlikely. Finally with regard to morphologic characteristics, could this sheep model be that of a single cerebral AVM with multiple true "anatomic" or "structural" nidus compartments ("sectorization" of the nidus, as coined by Pertuiset et al [11]) represented by the two barely connected retia mirabilia? The answer should be negative, because in these uncommon cerebral AVMs true "hemodynamic" nidus compartmentalization is much more readily recognized in AVMs, each compartment is fed and drained by its own artery and vein, respectively, and therefore, it is quite unlike what is found in the sheep "AVM model." None of the above issues are relevant to the nidus of the swine AVM model because of its extensive midline interretial connections that join bilateral retia mirabilia into an overall *single* vascular network representative of the nidi of most cerebral AVMs.

A second minor shortcoming of the sheep "AVM model" applies to the feeding arteries. The great majority of cerebral AVMs are fed by terminal or direct feeders. Instead, the sheep "AVM" is fed only by two or more "en passage" type of feeders. Conversely, the most important feeder to the swine AVM nidus is an easily accessible terminal type of feeder represented by the ascending pharyngeal artery. In the swine model, the presence of the ramus anastomoticus and the arteria anastomotica, acting as additional en passage feeders, completes the appearance of appropriately simulated feeders of both types. All three swine feeders can be microcatheterized during realistic interventional/embolization simulations (3). Thus, in terms of strict adherence to the rules of modeling, the feeding arterial system to the swine AVM model is also much more representative of cerebral AVMs than that found in sheep.

In relation to the angiographic appearance of the sheep "AVM model" and the hemodynamic inferences that can be made, one striking observation is noted: the arterial feeders, nidus, and draining veins

are only *faintly* opacified precisely down to the level of the origin of the occipital artery ipsilateral to the fistula. Indeed, on the lateral image provided, there is no discernible contrast medium in the right external carotid artery (the simulated draining vein) above its junction with a markedly opacified right occipital artery. These observations indicate an overall poor flow through that part of the vascular circuit, which represents the "AVM model." In comparison, both occipital arteries are very well opacified, indicating that most of the flow diversion from the contralateral side of the neck to the fistula occurs at the level of the occipital arteries, and not at the level of both retia. Hemodynamically speaking, this is a point of critical importance, because cerebral AVMs represent a short-circuit for blood flow between arteries and veins. Instead, the neck anastomoses between both occipital arteries in the sheep would appear to offer a pathway of less resistance than that of the "AVM." This hemodynamic inadequacy of the sheep "AVM" is not surprising when the shape of the "nidus" is taken into account. The almost complete separation of bilateral retia and the presence of only one/few vessels between them means that the resistance to flow from one rete to the other would be considerably higher than that found in a single-entity nidus, as seen in the swine AVM model. This principle may be better appreciated by analogy with elementary laws of hydrology or electricity. Indirect support for this comes also through knowledge that in the normally fast-flowing swine AVM model, if the resistance is increased in any part of the AVM circuit (eg, by partially embolizing the nidus, or by inducing vasospasm in the main feeding artery or draining vein), then flow diversion to the neck fistula occurs through pathways parallel with both retia at the level of other arteries in the neck. This typically occurs through occipital artery to occipital artery anastomoses, giving the exact angiographic appearance of the sheep "AVM model." Once again, none of these issues relate to the swine AVM model in which the low-resistance single-entity nidus permits preferential fast shunting blood flow and, hence, a realistic angiographic appearance and a representative transnidus drop in flow and pressure parameters.

In view of the morphologic and hemodynamic shortcomings described, the sheep would seem to be an inappropriate laboratory animal for the purpose of AVM model construction. Owing to its obviously simple construction technique and its underlying structure and hemodynamics, the carotid-jugular fistula type AVM model in swine is considered a very suitable experimental simulator of cerebral AVMs, especially with regard to interventional neurovascular research, ie, the performance and study of experimental embolotherapy and the development of new embolization techniques. If the swine is unavailable in a particular laboratory, caution should be exercised in referring to an alternative morphologically and hemodyn-

amicably unacceptable construct as an "AVM model." The authors should be encouraged to intensify their efforts, through strict attention to detail and adherence to the principles of experimental modeling (7), in seeking out new and improved *in vivo* AVM modeling techniques other than in sheep. For example, one proposal for an appropriate alternative laboratory animal to use for AVM model construction might be the goat. This animal is only 15% more expensive than either swine or sheep. Vascular anatomy of the goat head and neck is practically identical to that of the sheep, with the most important exception that both retia are connected by extensive midline interretial vessels similar to the swine and unlike the sheep.

Tarik F. Massoud, M.D.
 Division of Neuroradiology
 University of Michigan Medical Center
 Ann Arbor, Michigan

References

1. Massoud TF, Ji C, Viuela F, et al. **An experimental arteriovenous malformation model in swine: anatomic basis and construction technique.** *AJNR Am J Neuroradiol* 1994;15:1537
2. Massoud TF, Hademenos GJ, Viuela F, Ji C. **Transvenous retrograde nidus sclerotherapy under controlled hypotension (TRENTH): Experimental evaluation of a novel embolization technique for brain arteriovenous malformations (abstr).** *Radiology* 1995;197(P):486
3. Massoud TF, Ji C, Viuela F, et al. **Laboratory simulations and training in endovascular embolotherapy using a swine arteriovenous malformation model.** *AJNR Am J Neuroradiol* 1996;17:271-279
4. Massoud TF, Ji C, Guglielmi G, Viuela F. **Endovascular treatment of arteriovenous malformations with selective intranidal occlusion by detachable platinum electrodes: technical feasibility in a swine model.** *AJNR Am J Neuroradiol* 1996;17:1459-1466
5. Murayama Y, Massoud TF, Viuela F. **Transvenous hemodynamic assessment of experimental arteriovenous malformations: Doppler guidewire monitoring of embolotherapy in a swine model.** *Stroke* 1996;27:1365-1372
6. Murayama Y, Massoud TF, Viuela F. **Hemodynamic changes in arterial feeders and draining veins during embolotherapy of arteriovenous malformations: An experimental study in a swine model.** *Neurosurgery* 1998;43:96-106
7. Massoud TF, Hademenos GJ, Young WL, Gao E, Pile-Spellman J, Viuela F. **Principles and philosophy of modeling in biomedical research.** *FASEB J* 1998;12:275-285
8. Daniel PM, Dawes JKD, Prichard MM. **Studies of the carotid rete and its associated arteries.** *Trans R Soc Lond (Series B)* 1953;237:173-208
9. Salzman M, Scholtz H, Numaguchi Y. **Multiple intracerebral arteriovenous malformations: report of three cases and review of the literature.** *Surg Neurol* 1992;38:121-128
10. Voigt K, Beck U, Reinshagen G. **A complex cerebral vascular malformation studied by angiography: multiple aneurysms, angiomas, and arterial ectasia.** *Neuroradiology* 1973;5:117-123
11. Pertuiset B, Ancrì D, Clergue F. **Preoperative evaluation of hemodynamic factors in cerebral arteriovenous malformations for selection of a radical surgery tactic with special reference to vascular autoregulation disorders.** *Neurol Res* 1982;4:209-233

Reply

We would like to thank Dr. Massoud for his interest in our recently published arteriovenous malformation (AVM) model in sheep. As it was stated in our article, the purpose of the study was to evaluate the feasibility of creating an animal AVM model without the need for complex endovascular procedures. In his commentary of our article, Dr. Massoud made a strong defense of the swine model described by his group and criticized the sheep model as overly complicated and unrepresentative of a cerebral AVM. We will not even attempt to respond to all of his criticisms, because the response would need to be even longer than the original manuscript. We will simply try to delineate the rationale we followed in developing our experimental model and clarify some of his misunderstanding.

Despite some similarities to human AVMs, animal models are unable to reproduce the complex angioarchitectural features of human AVMs, such as arteriovenous shunts, multiple compartments in the nidus, tortuous feeders, intranidal vascular aneurysms, propensity to hemorrhage, variable hemodynamic resistance, abnormal venous drainage, "steal effect," as well as the "perfusion pressure breakthrough" after treatment. Contrary to what Massoud likes to believe, this great variability in the morphologic and pathophysiologic features in AVMs makes it impossible to classify any one animal model as a "typical" AVM or to claim that it embodies most of the desired features. The fact is that, to date, none of the described animal models, including the swine, are truly representative of a human AVM.

Dr. Massoud emphasized in his original publication that endovascular occlusion of the right occipital, ascending pharyngeal, and the external carotid artery in the swine model was necessary to maximize blood shunting across the rete to the fistula. Their pilot study revealed that if these vessels were left unoccluded, they became major collateral pathways, diverting most of the blood flow away from the rete itself (1). Although Massoud argued in his letter that he eliminated the need for endovascular procedures in a subsequent study (2, 3), there was still the need to place a large 8F guiding catheter into the right carotid artery adjacent to the fistula in order to decrease the flow through this vessel and "thus allow for a greater contribution to the fistula from the cephalad aspect of the artery and thus increase the flow reversal down the drainage portion of the AVM model." This was done in order to optimize the inadequate flow obtained through the rete in the swine.

Another "deficiency" of the sheep animal model is, according to Dr. Massoud, the existence of a single vessel connecting the two retia. We disagree with his interpretation of the images presented, because multiple vascular connections were clearly shown in the cast specimens as well as angiographically in our study (Fig 1A and B).

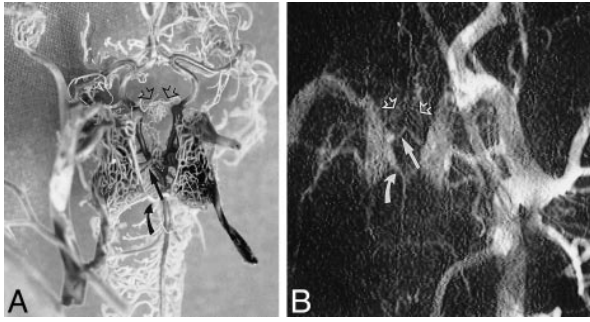


FIG 1. A, Photograph of the corrosion cast of the cerebrovascular anatomy on ventral view with 20° cephalad angulation shows two vascular connections in the posterior (*curved arrow*) and middle (*straight arrow*) portions as well as a dense vascular network connecting the anterior portion of the carotid retia. B, Close-up view of the retial structure on a left common carotid arteriogram after surgery confirms the vascular connections between both retia demonstrated on the corrosion cast.

Dr. Massoud also pointed out in his letter that, in the sheep model, most of the flow diversion from the contralateral side to the fistula occurred at the level of the occipital arteries and not through the retia. We disagree with his interpretation and, in order to prove our point, we recreated the model in an additional animal and repeated the angiographic study after ligation of the occipital artery contralateral to the fistula. As expected, angiograms performed before and after ligation demonstrated, as expected, the same differences in density between the distal and proximal carotid artery (Fig 2A and B). Additionally, it was apparent in the postligation angiogram that the internal maxillary artery on the side of the fistula was densely opacified during the early phase, even before the carotid artery was opacified (Fig 2C), discounting Dr. Massoud's misconception that this segment had filled in a retrograde manner through the occipital artery. The relatively low density in the segment above the junction with the right occipital artery is easily explained, not as a result of diverted blood flow at the level of the occipital arteries, but instead as the final effect of the contrast column on the proximal and mid segments that are curved, as seen on the lateral pro-

jection, giving them a relatively higher density. This observation was demonstrated on the anteroposterior and lateral angiograms performed before and after surgery (4).

Dr. Massoud stated that the lack of validation of the morphologic and hemodynamic behavior of the sheep model made this model inadequate for scientific purposes. We would like to comment that, although hemodynamic assessments of the swine model, during AVM embolization by Massoud et al (2, 3), provided some interesting data (2, 3), the validity of these studies was questioned by several investigators (5, 6). Cockroff and Steinberg (5) expressed in their commentary that "the validity of the conclusions drawn depends on the model relevance to human AVMs." They further expressed that "it remained to be determined whether these techniques will provide useful information on humans with complex AVMs." Wakhloo et al (6), among others, also stated that the "use of blood flow velocity measurements in an AVM draining vein to quantify the extent of an embolization may have limited application."

Rather than respond to all of Dr. Massoud's criticisms, which are mostly an ardent defense of "his model," we think it is more important to keep in perspective that the importance of these models is their value for research and training in neurovascular interventions, because they do have arterial feeder(s), a nidal structure, draining vein(s), and high flow through the "AVM," regardless of their morphologic characteristics.

Zhong Qian, M.D.
Wilfrido R. Castañeda, M.D.
Department of Radiology
Louisiana State University Medical Center
School of Medicine in New Orleans

References

1. Massoud TF, Ji C, Vinuela F, Guglielmi G, Robert J, Duckwiler GR, Gobin YP. An experimental arteriovenous malformation model in swine: anatomic basis and construction technique. *AJNR Am J Neuroradiol* 1994;15:1537-1545

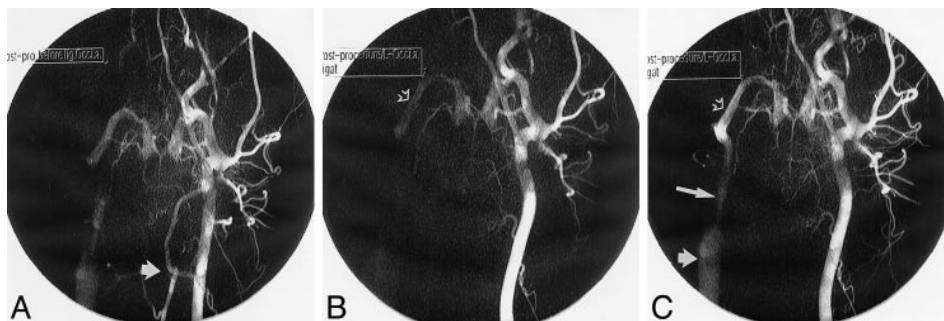


FIG 2. A, Postoperative left carotid arteriogram taken before occipital artery ligation shows the opacified left occipital artery (*arrow*). B, Left carotid arteriogram after occipital artery ligation. The early phase shows both retial structures and opacification of the internal maxillary artery (*open arrow*) on the anastomotic side. C, Late phase of carotid arteriogram shows opacification of the external carotid artery (*long arrow*) and jugular vein (*short arrow*) on the anastomotic side, confirming the direction of flow diversion through the retia toward the arteriovenous fistula.

2. Murayama Y, Massoud TF, Vinuela F. **Transvenous hemodynamic assessment of experimental arteriovenous malformations: Doppler guidewire monitoring of embolotherapy in a swine model.** *Stroke* 1996;27:1365-1372
3. Murayama Y, Massoud TF, Vinuela F. **Hemodynamic changes in arterial feeders and draining veins during embolotherapy of arteriovenous malformations: an experimental study in a swine model.** *Neurosurgery* 1998;43:96-104
4. Qian Z, Climent S, Maynar M, Uson-Garallo J, Lima-Rodrigues MA, Calles C, Robertson H, Castaneda-Zuniga WR. **A simplified arteriovenous malformation model in sheep: feasibility study.** *AJNR Am J Neuroradiol* 1999;20:765-770
5. Cockroft KM, Steinberg GK. **Comments on Murayama Y, Massoud TF, Vinuela F. Hemodynamic changes in arterial feeders and draining veins during embolotherapy of arteriovenous malformations: an experimental study in a swine model.** *Neurosurgery* 1998;43:104
6. Wakhloo AK, Lieber BB, Hopkins LN. **Comments on Murayama Y, Massoud TF, Vinuela F. Hemodynamic changes in arterial feeders and draining veins during embolotherapy of arteriovenous malformations: an experimental study in a swine model.** *Neurosurgery* 1998;43:105-106

In Re: Tokumaru AM, Barkovich AJ, O'uchi T, Matsuo T, Kusano S. **The evolution of cerebral blood flow in the developing brain: evaluation with MR imaging.** *AJNR Am J Neuroradiol* 1999; 20:845-852

To the Editor:

I wish to inform the readers of the *AJNR* of errors that occurred in the preparation and submission of the above-referenced study, of which I was senior author. Specifically, a previously published article (1) contained much of the same material and was not cited in our article. I was unaware of that publication. In addition, Mr. Tsuyoshi had not given his consent to be cited as an author of our article that appeared in the *AJNR*.

As senior author, I apologize and take full responsibility for these errors.

Aya M. Tokmaru, MD
Department of Radiology
National Defense Medical College
Tokorozawa City, Japan